



## Bioscientia Medicina: Journal of Biomedicine & Translational Research

Journal Homepage: [www.bioscmed.com](http://www.bioscmed.com)

### Steroid Therapy in Extrahepatic Cholestasis Suggestive of Biliary Atresia: A Case Report

Primadita Syahbani<sup>1</sup>, Rendi Aji Prihaningtyas<sup>1</sup>, Bagus Setyoboedi<sup>1\*</sup>, Sjamsul Arief<sup>1</sup>

<sup>1</sup>Department of Child Health, Universitas Airlangga/Dr. Soetomo General Academic Hospital, Surabaya, Indonesia

#### ARTICLE INFO

##### Keywords:

Cholestasis  
Infant  
Jaundice  
Steroid

##### \*Corresponding author:

Bagus Setyoboedi

##### E-mail address:

[bagus.setyoboedi@fk.unair.ac.id](mailto:bagus.setyoboedi@fk.unair.ac.id)

All authors have reviewed and approved the final version of the manuscript.

<https://doi.org/10.37275/bsm.v8i9.1042>

#### ABSTRACT

**Background:** Biliary atresia is a fibroinflammatory disease obstructing the extrahepatic biliary system. Biliary atresia is the leading cause of cholestasis in infants and the cause of end-stage liver disease in the first two years of life. Surgical treatment with Kasai portoenterostomy has been performed but has not eliminated the need for liver transplantation. The consideration of adjuvant steroid therapy for suppressing the fibro-inflammatory process in the bile ducts may improve the outcome of extrahepatic cholestasis. **Case Presentation:** A case of a 2-month 7-day-old boy with a chief complaint of jaundice with suspicion of biliary atresia. Jaundice started 1 week after birth, followed by acholic stools, yellow-brown urine, distended abdomen, hepatomegaly, and visible abdominal veins. Laboratory examination revealed an elevated level of direct bilirubin (cholestasis) in combination with elevated levels of aspartate aminotransferase (AST), alanine aminotransferase (ALT), and Gamma-glutamyl transferase (GGT), hypoalbuminemia, and reactive of IgG and IgM CMV. A percutaneous liver biopsy was performed and showed extrahepatic cholestasis with mild fibrosis consistent with biliary atresia. The patient was treated with oral methylprednisolone and ursodeoxycholic acid (UDCA). After 12 weeks of therapy, the patient was free of jaundice and darkening of stool color, followed by a normal bilirubin level. **Conclusion:** In young infants with extrahepatic cholestasis suggestive of biliary atresia, steroid administration resulted in clinical and laboratory improvement. The involvement of the immune response in the pathogenesis of biliary atresia may suggest new therapeutic targets for biliary atresia, such as steroids for improving the outcome of biliary atresia in young infants.

#### 1. Introduction

Elevated total serum bilirubin causes neonatal jaundice also known as neonatal hyperbilirubinemia, which is clinically characterized by the yellowish coloration of the skin, sclera, and mucous membranes.<sup>1</sup> The prevalence of neonatal jaundice in an African hospital reached 55.2%.<sup>2</sup> Research conducted in Bhutan, India, shows that the prevalence of neonatal jaundice is increasing. In 2019, 33% of births resulted in babies with neonatal jaundice, and this increased in 2020 to 47%.<sup>3</sup> The accumulation of bilirubin in the blood leads to jaundice, which can come from a variety of diagnoses, ranging from self-limiting breast milk jaundice to aggressive life-

threatening diseases such as biliary atresia and liver failure.<sup>4</sup> In most cases, it is a mild, temporary condition that resolves itself without treatment. This is known as "physiological jaundice" or non-cholestatic jaundice, and the more severe type is known as "pathological jaundice" or cholestatic jaundice.<sup>5</sup>

It is important to distinguish jaundice caused by cholestasis from jaundice caused by non-cholestatic conditions (such as physiological jaundice in newborns) since it is most likely pathological. Therefore, patients with cholestatic jaundice will benefit from prompt diagnosis and appropriate therapy.<sup>5</sup> The condition called cholestatic jaundice in

neonates is a disorder of bile formation or excretion. One of the effects of cholestatic jaundice is the accumulation of bile components beyond the normal capacity of the liver cell structure. This causes cellular damage to the liver parenchyma, toxic damage to the biliary tree, and peripheral circulation of harmful chemicals, including bile acids. The hepatobiliary function is impaired by cholestasis, which is usually classified as intrahepatic (hepatocyte injury, bile canaliculi, or intrahepatic bile ducts) or extrahepatic (extrahepatic ducts, common hepatic ducts, or common bile ducts).<sup>6</sup>

Symptoms such as acholic stools, dark yellow urine, or hepatomegaly can be found in cholestasis. If acholic stools are found, there may be biliary obstruction, and additional investigations are required. Biliary atresia is a fibroinflammatory disease that causes complete obstruction of the extrahepatic system of the biliary duct. It is also a major cause of neonatal cholestasis. Affected children can develop rapidly progressing fibrosis if left untreated, which can lead to portal hypertension. Biliary atresia is also the most common cause of end-stage liver disease in the first two years of age due to rapid disease progression.<sup>7</sup> It is critical to detect biliary atresia quickly as rapid treatment correlates with delaying or reducing the need for liver transplantation.<sup>8</sup>

Several theories have been proposed to explain the pathophysiology of biliary atresia, ranging from genetic factors, immune factors, and environmental factors. One proposed environmental factor is exposure to in-utero infections from cytomegalovirus (CMV), Epstein-Barr virus, to papillomavirus. Immune factors relate to immune dysregulation to autoimmune processes involving the activation of adaptive and innate immune responses.<sup>9</sup> The recommended operative therapy for biliary atresia is Kasai portoenterostomy (KPE), but liver transplantation will still be recommended to avoid the effects of further liver damage.<sup>9</sup> However, not all health facilities are adequate for hepatic transplantation in Indonesia, so adjuvant therapies are urgently needed. Several therapeutic options are being researched, one of which

is steroid therapy. In this case report, steroids were used as adjuvant therapy and gave favorable results in a case of cholestasis in an infant suspected of having biliary atresia.

## **2. Case presentation**

A 2-month-old and 7-day-old boy came to Dr. Soetomo General Academic Hospital with a chief complaint of jaundice. The patient was referred for further diagnosis with suspicion of biliary atresia. Jaundice was suffered since the age of 1 week after birth, had phototherapy for a week, but jaundice persisted. Until the patient was 1 month old, jaundice got worse followed by abdominal distended with visible blood vessels. Complaints were also accompanied by pale-colored stools or acholic stools and yellow-brown urine like tea. No other complaints, such as fever, vomiting, or bleeding. In previous treatment history, the patient was given ursodeoxycholic acid, but the bilirubin level remained high and the abdominal condition was getting more distended. There was no history of previous surgery or disease. There were no similar complaints in the family.

The patient was the first child, born sectio caesarea and premature at 35 weeks due to the amniotic membrane being drained. He did not cry immediately and was born cyanotic with a birth weight of 1800 grams. The patient was admitted to the NICU for approximately 3 weeks and was diagnosed also with congenital heart disease. During pregnancy, the mother was often hospitalized, had shortness of breath, and vomited for almost 1 month. The last immunization that has been obtained was BCG. The patient was breastfed only until the age of 1 month and 20 days and after that was given a combination of breast milk and formula milk.

The patient was compos mentis with a body weight of 3100 gr, body length of 47 cm, head circumference of 32 cm, and abdominal circumference of 36 cm. On physical examination, hepatomegaly was found with a size of 6 cm x 5 cm x 2.5 cm with a spongy consistency, sharp edges, smooth surface, and splenomegaly with varicous vein in the abdomen.

The laboratory examination showed an increase in liver function, such as aspartate aminotransferase (AST) 288 U/L, alanine aminotransferase (ALT) 488 U/L, Gamma-glutamyl transferase 720 U/L, Alkaline phosphatase (ALP) 467 U/L, bilirubin (total 16.35 mg/dL, and direct 12.76 mg/dL), and hypoalbuminemia 2.96 g/dL. Other laboratory results revealed APTT 35.7 sec, PPT 12.1 sec, CRP 1.85 mg/dL, HbsAg non-reactive, TSH 10,726, FT4 1.60 ng/dL. TORCH analysis showed CMV IgM reactive at 1.48 IU/mL (<0.85), and CMV IgG reactive at 1462.8 IU/mL (6). Toxoplasma and Rubella IgG and IgM were non-reactive. Routine blood examination revealed Hb 10 g/dL, Hct 33.1%, White blood cells 10.27 x103/ $\mu$ L, Platelet 35 x103/ $\mu$ L. Echocardiography showed moderate atrial septal defect (ASD) and small patent ductus arteriosus (PDA). The results of the eye and ENT screening were normal.

A two-phase abdominal ultrasound revealed liver size +/- 6.65 cm, sharp angle, regular edge, echo intensity of parenchyma appears homogeneous, v.porta caliber +/- 0.12 cm, a. hepatica caliber +/- 0.08 cm, v.hepatica appears normal, triangular cord sign (-). The gall bladder was found normal size, no wall thickening, no stone/nodule/sludge, preprandial size +/- 3.4 cm (length) x 0.7 cm (width) (vol +/- 86 cc), at postprandial size +/- 2.1 cm (length) x 0.8 cm (width) (vol +/-0.66 cc) with contraction index 25%. There was splenomegaly measuring +/- 7.43 cm. Percutaneous liver biopsy showed bile duct proliferation and a few lymphocyte inflammatory cells in the portal tract. There is no bile duct proliferation. The hepatic lobe comprises hepatocyte cells with ballooning degeneration, including a little bile pigment. Percutaneous liver biopsy results were consistent with extrahepatic cholestasis with mild fibrosis (F1) (Figure 1).

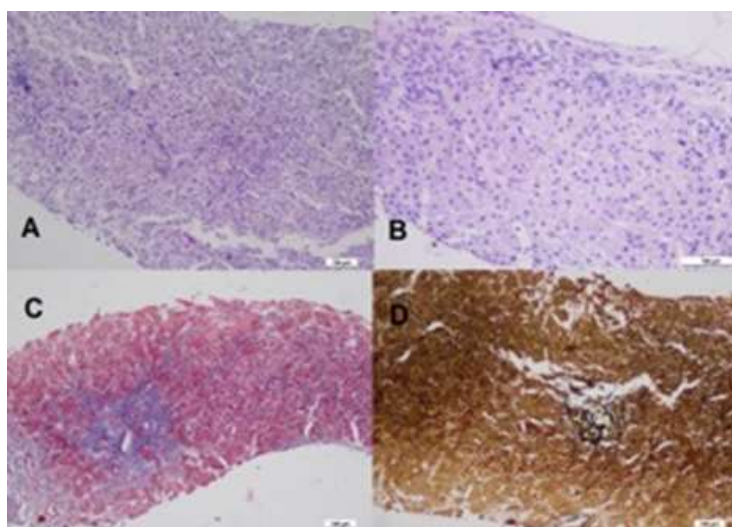


Figure 1. Liver biopsy specimens (A. Hematoxylin-eosin staining with 100x magnification; B. hematoxylin-eosin staining with 200x magnification; C. Mason's trichrome staining showed fibrosis; D. reticulin staining showed fibrosis).

The patient received steroid treatment at a dose of 2 mg/kgBB/day and combined with ursodeoxycholic acid. Complaints of jaundice and acholic stools were evaluated daily by parents who had also been educated regarding stool color cards. Laboratory test evaluation was done every 2 weeks. The patient had

received steroid treatment with weekly tapering off. The symptoms of jaundice were improved and the acholic stools have become darker (Figure 2-4). After steroid therapy, a re-evaluation of liver function was carried out, with the results of AST 194 U/L, ALT 281 U/L, GGT 567.9 U/L, total bilirubin 15.65 mg/dL, and

direct bilirubin 12.35 mg/dL. From the laboratory evaluation results, there was a decrease in AST, ALT, GGT, and bilirubin levels to total bilirubin 0.91 mg/dL

and direct bilirubin to 0.5 mg/dL in the 12<sup>th</sup> week of treatment (Figure 5).

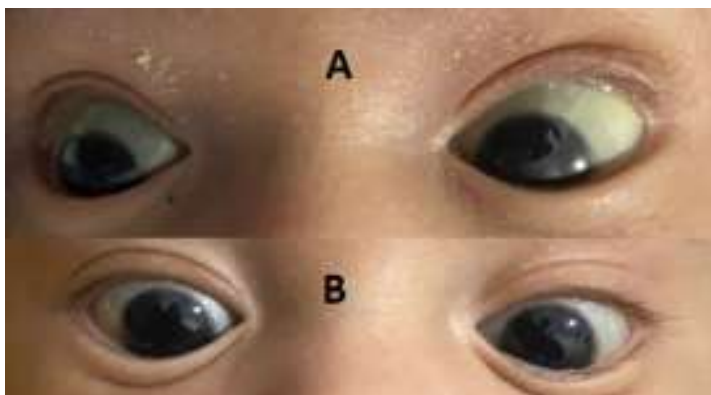


Figure 2. Clinical Jaundice Evaluation (A. Before treatment; B. After treatment).

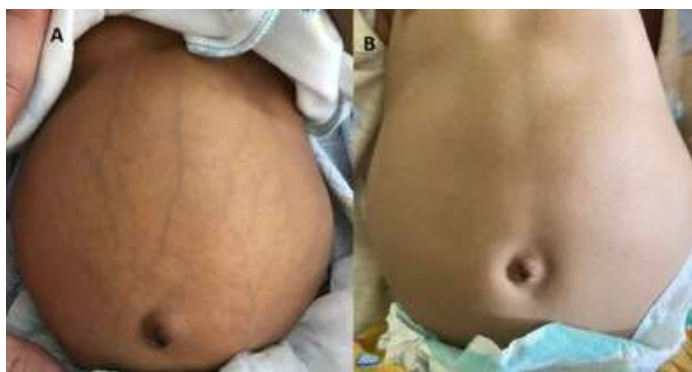

Figure 3. Abdominal distended evaluation (A. Before treatment; B. After treatment).

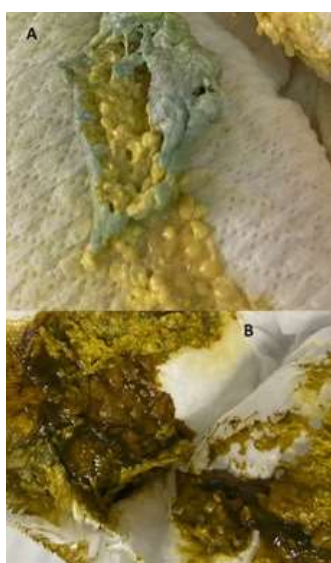


Figure 4. Stool color evaluation (A. Before treatment; B. After treatment).

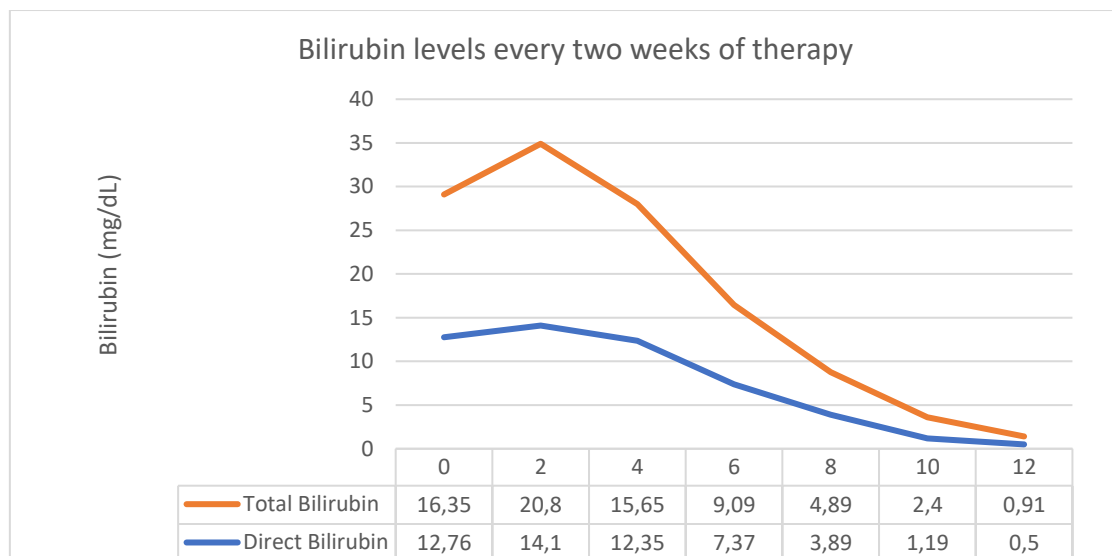


Figure 5. Serum bilirubin level evaluation during treatment.

### 3. Discussion

In this patient, there were clinical findings that indicated the diagnosis of biliary atresia in the form of persistent jaundice, acholic stools, and hepatomegaly.<sup>10</sup> The diagnosis of biliary atresia was supported by the presence of cholestasis in the patient as indicated by an increase in direct bilirubin of 12.76 mg/dL, which is >20% of total bilirubin.<sup>7</sup>

Biliary atresia was diagnosed by liver biopsy, but the suspected cause of cholestasis caused by biliary atresia should be considered because biliary atresia is the most common cause of cholestasis in neonates.<sup>7</sup> The patient's history of jaundice was sustained until 1 month of age and phototherapy and ursodeoxycholic acid treatment were tried but jaundice persisted. Pathologic jaundice or cholestatic jaundice leading to this suspected diagnosis of biliary atresia is still often too late to be diagnosed and treated at the appropriate age. Frequently, biliary atresia is still associated with breast milk jaundice and is not evaluated further.<sup>11</sup>

The biopsy revealed extrahepatic cholestasis supported biliary atresia. A liver biopsy can differentiate biliary atresia from other causes of cholestatic jaundice with a high degree of accuracy. Histopathologic features of biliary atresia include biliary proliferation, biliary obstruction, focal liver

parenchymal necrosis, extramedullary hemopoiesis, and inflammatory cell infiltration.<sup>10</sup> In cases with high suspicion of biliary atresia, liver biopsy may exclude biliary atresia and avoid intraoperative cholangiogram.<sup>12</sup>

Operative therapy with KPE is still chosen with a success rate that depends on the degree of fibrosis process of the liver which is an advanced process of biliary atresia.<sup>13</sup> A study in Indonesia showed the success of KPE was 51.7%.<sup>14</sup> Meanwhile, another study examined the outcome of patients who underwent KPE and found that the mortality rate was 58.5% with the main causes being sepsis and liver failure.<sup>15</sup> Liver transplantation was performed because KPE only delays the process and increases the potential survival rate of patients. However, a Korean study showed that liver transplantation in biliary atresia has another unfavorable impact, namely portal vein complications (13 out of 120 patients). In addition, the most common cause of death in biliary atresia patients who underwent liver transplantation was infection (67%).<sup>16</sup> Thus, liver transplantation in biliary atresia patients has a high risk and serious complications.

One of the adjuvant therapies in biliary atresia is steroid therapy. Steroid administration in biliary

atresia patients after KPE may provide a better result than those who are not administered.<sup>17,18</sup> However, there are no studies regarding the efficacy of administering steroids before KPE, especially when cholestasis develops in young infants.

In the current study on post-KPE steroid administration, it is observed that steroids can increase the jaundice clearance rate after the 6-month follow-up compared to those who were not given steroids.<sup>17</sup> The number of children with normal bilirubin levels was higher in the high-dose steroid therapy (53.4%) than in the low dose (38.7%).<sup>19</sup> Biliary atresia is related to complex immune processes triggered by viruses, toxins, and gene variations, leading to proinflammatory processes that destroy the duct epithelium and cause cholangiopathy.<sup>20,21</sup>

An initial insult to the biliary tract leads to the release of new antigens, which are then presented to naive T lymphocytes by antigen-presenting cells. Primed Th1 lymphocytes release proinflammatory cytokines and recruit cytotoxic T cells, leading to biliary and liver parenchymal damage. Inflammatory cytokines are found in overexpressed levels. These include interleukins (IL-2), interferon  $\gamma$ , and tumor necrosis factor.<sup>22</sup> MMP-7 was also found to play a role in the promotion of inflammation and fibrosis in biliary atresia. The active involvement of immune response and MMP-7 in the pathogenesis of biliary atresia would have implications for new therapeutic targets in biliary atresia.<sup>23</sup>

The potential advantages of glucocorticoid therapy, which includes steroids, in biliary atresia, are that it elevates apical sodium-independent bile acid transporters, which regulate bile acid metabolism and decrease bile acid production, suppresses immune function to delay progressive liver fibrosis, and represses related inflammation gene transcription.<sup>17</sup> The mechanism of steroids in their administration in cases of biliary atresia is said to have not been explained in further detail. In general, the potential role of steroids is as a potent anti-inflammatory drug, and in cases of biliary atresia, this role is being utilized.<sup>24</sup> This finding is based on the presence of

inflammatory marker components identified in infants with biliary atresia. In addition to these, there is a post-KPE systemic inflammatory process characterized by an increase in serum inflammatory cytokines (TNF- $\alpha$ , IL-2, IL-12) and soluble adhesion molecules that can last until at least 6 months postoperatively.<sup>25</sup> These ongoing systemic inflammatory processes and localized intrahepatic inflammation are attractive therapy targets where steroids can limit the damage to hepatocytes and fibrosis.<sup>24</sup> Some studies report complications associated with steroid treatment, but they are also difficult to define as steroid complications. It can also be related to surgical procedures or other medications, but other studies have shown that steroids do not increase the risk of other serious complaints.<sup>17</sup> Biliary atresia is a condition where progressive fibrosing leads to obstructive cholangiopathy, which can lead to portal hypertension. The bile duct damage continues and will eventually lead to biliary cirrhosis despite the Kasai procedure.<sup>10</sup>

Another regimen given to the patient is ursodeoxycholic acid (UDCA). In conditions of biliary atresia where there is an obstruction to bile flow, some patients are given UDCA. Due to its choleric effect, UDCA is expected to enhance hepatic bile flow by up-regulating bile acid transporters, such as Bile Salt Export Protein (BSEP).<sup>26</sup> Existing studies have only explored the effects of steroid administration on patients with biliary atresia who have undergone the Kasai procedure as conducted in London.<sup>27</sup> Meanwhile, there haven't been many studies and case reports related to the administration of steroids as adjuvant therapy in biliary atresia. Thus, finding out more about the mechanism of steroid therapy in biliary atresia requires further experimental studies.

This patient was given steroid therapy using methylprednisolone at a dose of 2 mg/kgBB/day which was then tapered off every week. Then the patient was evaluated every 2 weeks and obtained clinical improvement in jaundice and feces that were no longer as pale as before. The bilirubin, AST, and ALT levels also decreased. Currently, the patient has

entered the 12th week of treatment and is still being monitored for clinical, and laboratory results, and the milestones progression.

#### 4. Conclusion

The diagnosis of cholestasis remains difficult to implement, while the disease progresses steadily over time. In addition, diagnosis of biliary atresia is not easy to perform in all healthcare facilities and needs urgent surgery treatment. In limited health facilities, steroid therapy may be an alternative initial therapy option that may be beneficial in patients with cholestasis with suspicion of biliary atresia to prevent the disease progression.

#### 5. References

1. Ansong-Assoku B, Shah SD, Adnan M, Ankola PA. Neonatal Jaundice. In: StatPearls [Internet]. Treasure Island (FL): StatPearls Publishing. 2024.
2. Brits H, Adendorff J, Huisamen D, Beukes D, Botha K, Herbst H, et al. The prevalence of neonatal jaundice and risk factors in healthy term neonates at National District Hospital in Bloemfontein. *Afr J Prim Health Care Fam Med.* 2018; 10(1).
3. Dorji N, Gurung MR, Gyeltshen G, Singh Mongar K. Epidemiology of neonatal jaundice at Punakha District Hospital, Punakha, Bhutan. *Int Health.* 2023; 15(5): 505–11.
4. Chee YY, Chung PH, Wong RM, Wong KK. Jaundice in infants and children: causes, diagnosis, and management. *Hong Kong Med J.* 2018; 24(3): 285–92.
5. Fawaz R, Baumann U, Ekong U, Fischler B, Hadzic N, Mack CL, et al. Guideline for the evaluation of cholestatic jaundice in infants: joint recommendations of the north american society for pediatric gastroenterology, hepatology, and nutrition and the european society for pediatric gastroenterology, hepatology, and nutrition. *J Pediatr Gastroenterol Nutr.* 2017; 64(1): 154–68.
6. Onofrio FQ, Hirschfield GM. The pathophysiology of cholestasis and its relevance to clinical practice. *Clin Liver Dis.* 2020; 15(3): 110–4.
7. Feldman AG, Sokol RJ. Neonatal cholestasis: updates on diagnostics, therapeutics, and prevention. *Neoreviews.* 2021; 22(12): e819–36.
8. Harpavat S, Lupo PJ, Liwanag L, Hollier J, Brandt ML, Finegold MJ, et al. Factors influencing time-to-diagnosis of biliary atresia. *J Pediatr Gastroenterol Nutr.* 2018; 66(6): 850–6.
9. Antala S, Taylor SA. Biliary atresia in children. *Clin Liver Dis.* 2022; 26(3): 341–54.
10. Siddiqui AI, Ahmad T. Biliary Atresia. In: StatPearls [Internet]. Treasure Island (FL): StatPearls Publishing. 2024.
11. Schreiber RA, Harpavat S, Hulscher JBF, Wildhaber BE. Biliary atresia in 2021: epidemiology, screening and public policy. *JCM.* 2022; 11(4): 999.
12. Ahmed ABM, Fagih MA, Bashir MS, Al-Hussaini AA. Role of percutaneous liver biopsy in infantile cholestasis: cohort from Arabs. *BMC Gastroenterol.* 2021; 21(1): 118.
13. Sastiono S, Maheranny M, Oswari H. Factors affecting the success rate of kasai portoenterostomy. *NRJS.* 2016; 1(1): 27–30.
14. Qisthi SA, Saragih DSP, Sutowo DW, Sirait DN, Imelda P, Kencana SMS, et al. Prognostic factors for survival of patients with biliary atresia following kasai surgery. *Kobe J Med Sci.* 2020; 66(2): E56–60.
15. Gad EH, Kamel Y, Salem TAH, Ali MAH, Sallam AN. Short- and long-term outcomes after Kasai operation for type III biliary atresia: twenty years of experience in a single tertiary Egyptian center-A retrospective cohort study. *Ann Med Surg (Lond).* 2021; 62: 302–14.
16. Lee S, Yi NJ, Han ES, Hong SY, Lee JM, Hong SK, et al. Long-term survival outcomes beyond the first year after liver transplantation in

- pediatric acute liver failure compared with biliary atresia: a large-volume living donor liver transplantation single-center study. *JCM*. 2022; 11(24): 7480.
17. Yang C-Z, Zhou Y, Ke M, Gao R-Y, Ye S-R, Diao M, et al. Effects of postoperative adjuvant steroid therapy on the outcomes of biliary atresia: a systematic review and updated meta-analysis. *Front Pharmacol*. 2022; 13: 956093.
  18. Lu X, Jiang J, Shen Z, Chen G, Np YW, Xiao X, et al. Effect of adjuvant steroid therapy in type 3 biliary atresia: a single-center, open-label, randomized controlled trial. *Annals of Surgery*. 2023; 277(6): e1200–7.
  19. Dong R, Song Z, Chen G, Zheng S, Xiao X min. Improved outcome of biliary atresia with postoperative high-dose steroid. *Gastroenterol Res Pract*. 2013;2013:1–5.
  20. Asai A, Miethke A, Bezerra JA. Pathogenesis of biliary atresia: defining biology to understand clinical phenotypes. *Nat Rev Gastroenterol Hepatol*. 2015; 12(6): 342–52.
  21. Ortiz-Perez A, Donnelly B, Temple H, Tiao G, Bansal R, Mohanty SK. Innate immunity and pathogenesis of biliary atresia. *Front Immunol*. 2020; 11: 329.
  22. Ghazy RM, Adawy NM, Khedr MA, Tahoun MM. Biliary atresia recent insight. *Egypt Pediatr Assoc Gaz*. 2018; 66(1): 1–8.
  23. Nomden M, Beljaars L, Verkade HJ, Hulscher JBF, Olinga P. Current concepts of biliary atresia and matrix metalloproteinase-7: a review of literature. *Front Med*. 2020; 7: 617261.
  24. Tyraskis A, Davenport M. Steroids after the Kasai procedure for biliary atresia: the effect of age at Kasai portoenterostomy. *Pediatr Surg Int*. 2016; 32(3): 193–200.
  25. Narayanaswamy B, Gonde C, Tredger JM, Hussain M, Vergani D, Davenport M. Serial circulating markers of inflammation in biliary atresia—Evolution of the post-operative inflammatory process. *Hepatology*. 2007; 46(1): 180–7.
  26. Burns J, Davenport M. Adjuvant treatments for biliary atresia. *Transl Pediatr*. 2020; 9(3): 253–65.
  27. Davenport M, Parsons C, Tizzard S, Hadzic N. Steroids in biliary atresia: Single surgeon, single centre, prospective study. *J Hepatol*. 2013; 59(5): 1054–8.