

Bioscientia Medicina: Journal of Biomedicine & Translational Research

Journal Homepage: www.bioscmed.com

Invasive Mammary Paget's Disease Without Underlying Malignancy: A Case Report

Raja Eka Citra Kalisa^{1*}, Ennesta Asri¹, Indah Indria Sari¹

¹Department of Dermatology and Venereology, Faculty of Medicine, Universitas Andalas, Padang, Indonesia

ARTICLE INFO

Keywords:

Case report
Dermatology
Invasive
Malignant
Mammary Paget's disease

*Corresponding author:

Raja Eka Citra Kalisa

E-mail address:

2050308203_raja@student.unand.ac.id

All authors have reviewed and approved the final version of the manuscript.

<https://doi.org/10.37275/bsm.v8i9.1073>

ABSTRACT

Background: Mammary Paget's disease (MPD) with skin invasion is a rare condition that is often associated with an underlying malignancy. However, invasive MPD without malignancy is even rarer and often misdiagnosed. **Case presentation:** This report presents the case of a 56-year-old woman who presented with a progressively enlarging scaly erythematous plaque on her left nipple for 6 months. Dermoscopy and histopathological examination confirmed the diagnosis of invasive MPD, but radiological examination did not reveal any malignancy. **Conclusion:** Invasive MPD without malignancy is a rare but important entity to recognize. Awareness of this condition can help prevent overdiagnosis and unnecessary treatment.

1. Introduction

Mammary Paget's disease (MPD) is a rare but clinically significant neoplastic entity, characterized by the proliferation of malignant cells in the epidermis of the nipple and areola. This condition was first described by Sir James Paget in 1874 and has since been the focus of extensive research and discussion in the fields of dermatology and oncology. MPD presents unique diagnostic and therapeutic challenges, especially when it presents in the absence of underlying malignancy. MPD is a rare condition, with prevalence varying depending on the population studied and the diagnostic method used. In general, MPD is estimated to occur in 0.7% to 4.3% of all breast cancer cases. However, the prevalence of invasive MPD, in which malignant cells invade the dermis, is

lower, ranging from 4% to 7.8% of all MPD cases. MPD is classically classified into two main types. MPD with Underlying Malignancy is the most common type of MPD, in which the proliferation of Paget cells in the epidermis is associated with underlying ductal carcinoma in situ (DCIS) or invasive ductal carcinoma (IDC) in the breast tissue. MPD Without Underlying Malignancy is a rarer type of MPD, where there is no evidence of an underlying malignancy at the time of diagnosis. These types often cause diagnostic confusion and require different approaches to management.^{1,2}

MPD usually appears as an eczematous lesion on the nipple or areola. These lesions can vary in appearance, ranging from scaly erythematous plaques to crusted ulcers. The most common symptoms are

itching, burning, pain, and nipple discharge. The diagnosis of MPD requires a combination of clinical examination, dermoscopy, histopathology, and radiology. Clinical examination and dermoscopy can provide initial clues, but definitive diagnosis requires skin biopsy and histopathological examination. Paget's cells have distinctive characteristics, namely large cells with pale cytoplasm and large, hyperchromatic nuclei. Immunohistochemical stains, such as CK7, CEA, and HER2, can help confirm the diagnosis and differentiate Paget's cells from other malignant cells. Radiological examinations, such as mammography and breast ultrasound, are very important to rule out the possibility of underlying malignancy in cases of MPD with underlying malignancy. In cases of MPD without underlying malignancy, radiological examination can help confirm the absence of malignancy and guide treatment decisions.^{3,4}

Management of MPD depends on the presence or absence of underlying malignancy and the extent of the disease. In cases of MPD with underlying malignancy, treatment is aimed at addressing the underlying malignancy, which usually involves mastectomy or lumpectomy with axillary lymph node dissection, followed by radiation therapy and/or chemotherapy. In cases of MPD without underlying malignancy, management is more controversial. Some experts recommend wide surgical excision with free margins to ensure complete removal of Paget's cells. However, this approach can cause significant morbidity, especially in patients who are elderly or in poor health. Other treatment options for MPD without underlying malignancy include wide local excision, topical therapy with corticosteroids or calcineurin inhibitors, and radiation therapy. Decisions regarding treatment modalities should be made on a case-by-case basis, taking into consideration the patient's age, overall health status, patient preferences, and resource availability.^{5,6}

The prognosis of MPD depends on the presence or absence of an underlying malignancy and the stage of

the disease at the time of diagnosis. In cases of MPD with underlying malignancy, the prognosis is generally poor, with 5-year survival rates ranging from 50% to 80%. In cases of MPD without underlying malignancy, the prognosis is generally good, with a low rate of local recurrence after adequate surgical excision. Mammary Paget's disease is a rare but important condition that requires special attention from dermatologists and oncologists. A thorough understanding of the epidemiology, pathogenesis, clinical presentation, diagnosis, and management of MPD is essential to ensure early diagnosis and optimal treatment.^{7,8}

2. Case Presentation

A 56 years old woman presented with scaly eroded nipple with occasional prickling sensation in her left breast which has been felt more frequently since the last 1 months. The complaints have been experienced since 6 months ago, and was unrelieved by any topical medications. She had no history of breast trauma. She had menarche at the age of 13 years with regular cycle of 28-30 days. The patient has a history of uterine myoma and had a hysterectomy performed in 2017. Physical examination revealed eczematous-like plaque with a thin, scaly surface on left retracted nipple. (Figure 1). Dermoscopic examination using Illuco® under polarized mode revealed white scales (yellow rectangle), pink structureless areas (white arrow), and light brown diffuse pigmentation.

Histopathological examination using hematoxylin-eosin staining (A) revealed epidermis containing proliferation of large cells (Paget cells) with abundant cytoplasm, large nuclei, pleomorphic, vesicular, coarse chromatin, mitosis can be found, these cells appear to infiltrate the underlying dermis (Figure 2). Histopathological examination using periodic acid-schiff staining (B) revealed group of tumor cells with positive reactions (Figure 2). No abnormalities were seen on the chest radiograph and bilateral mammary ultrasound examination. Only reretracted of the left mammary papilla was seen on mammography examination.

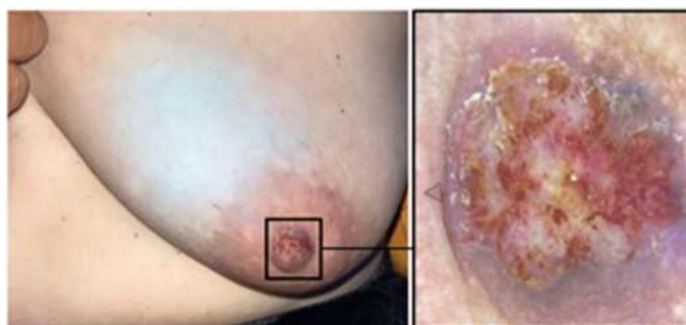

Figure 1. Erythematous scaly plaque on the left nipple.

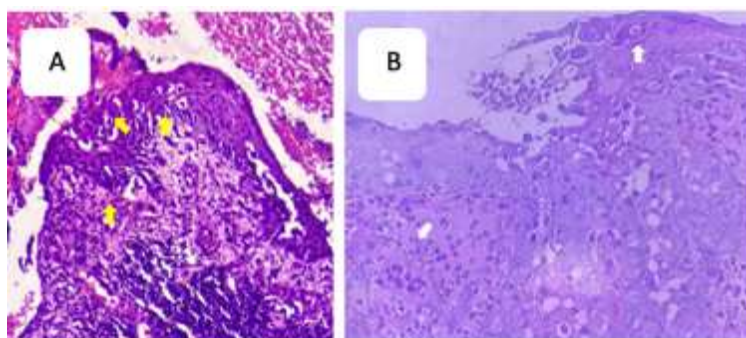


Figure 2. Histopathological examination with hematoxylin-eosin staining (A) and periodic acid-Schiff staining (B) revealed epidermis and dermis containing paget cells (yellow arrow) group of tumor cells with positive reactions (white arrow).

3. Discussion

Invasive mammary Paget's disease (MPD) without underlying malignancy is a rare but clinically important subtype of MPD. This subtype presents unique diagnostic and therapeutic challenges due to the absence of obvious malignancy at the time of diagnosis. A comprehensive understanding of this entity is essential to ensure accurate diagnosis, appropriate treatment, and optimal long-term monitoring. Despite extensive research, the pathogenesis of invasive MPD without malignancy remains incompletely understood. Several theories have been proposed to explain the origin and development of Paget's cells in this condition.^{9,10}

The epidermal transformation theory proposes that Paget's cells, which are characteristic of MPD, originate from the malignant transformation of normal epidermal cells located in the nipple or areola. In this scenario, initially, healthy skin cells undergo a series of genetic and molecular changes that drive them

toward malignancy. One of the main pieces of evidence supporting this theory is the presence of specific genetic mutations in Paget's cells that are not found in the underlying breast carcinoma cells. Several genes that are frequently mutated in MPD include: PIK3CA. This gene encodes a protein involved in the PI3K/AKT/mTOR signaling pathway, which plays an important role in cell growth, proliferation, and survival. Mutations in PIK3CA can activate this pathway constitutively, leading to uncontrolled cell growth. TP53, this gene encodes the p53 protein, which is known as the "guardian of the genome" because of its role in preventing the growth of damaged or mutated cells. Mutations in TP53 can disrupt p53 function, allowing damaged cells to survive and reproduce. ERBB2, this gene encodes human epidermal growth factor receptor 2 (HER2), which is involved in cell growth and development. Overexpression of HER2 can cause uncontrolled cell growth. Mutations in these genes, along with other

genetic changes, can disrupt the normal regulation of the cell cycle, apoptosis (programmed cell death), and cell differentiation, ultimately leading to the malignant transformation of epidermal cells into Paget cells.^{11,12}

Although genetic mutations play an important role in epidermal transformation, other factors may also contribute to the development of invasive MPD without malignancy. These factors can be environmental or related to an individual's health condition. Exposure to environmental carcinogens, such as ultraviolet radiation, industrial chemicals, or air pollutants, can damage the DNA of skin cells and increase the risk of genetic mutations that can trigger malignant transformation. Chronic inflammation of the nipple or areola, which can be caused by various factors such as infection, trauma, or autoimmune disease, can create a microenvironment conducive to malignant transformation. Chronic inflammation can trigger the production of free radicals and pro-inflammatory cytokines, which can damage the DNA of skin cells and disrupt the normal regulation of cell growth. Some studies suggest that hormonal changes, such as those that occur during menopause, may increase the risk of MPD. This may be because certain hormones, such as estrogen, can stimulate the growth of epidermal cells and increase their susceptibility to malignant transformation.^{13,14}

In addition to the presence of specific genetic mutations in Paget's cells, several other lines of evidence support the theory of epidermal transformation in the pathogenesis of invasive MPD without malignancy. In some cases of invasive MPD without malignancy, no evidence of underlying breast carcinoma is found even after several years of follow-up. This suggests that Paget's cells can originate from malignant transformation of epidermal cells in the absence of primary carcinoma in breast tissue. Gene expression studies have shown that Paget cells in invasive MPD without malignancy have a different gene expression profile than breast carcinoma cells. This suggests that Paget's cells may have a different cellular origin than breast carcinoma. Some cases of invasive MPD without malignancy have been

successfully treated with topical therapies, such as corticosteroids or calcineurin inhibitors, which target epidermal cells. This suggests that Paget's cells may be more responsive to therapy aimed at skin cells than to therapy aimed at carcinoma cells.¹⁵

The Toker Cell Migration Theory is one of the main hypotheses explaining the origin of Paget's cells in MPD, including invasive MPD without underlying malignancy. This theory proposes that Paget's cells originate from undetected carcinoma in situ (CIS) within the mammary ducts, which then migrate to the nipple epidermis or areola. The cell migration process is a complex phenomenon involving interactions between cells and the surrounding microenvironment. In the context of MPD, CIS cells residing within the mammary ducts are thought to undergo a series of molecular and cellular changes that enable them to exit the ducts, penetrate the basement membrane, and migrate through the stroma toward the epidermis. E-cadherin is a cell adhesion protein that plays an important role in maintaining the integrity of epithelial tissue. Loss of E-cadherin expression in CIS cells may result in loss of adhesion of these cells to each other, making it easier for them to detach from the mammary ducts and migrate. Matrix metalloproteinases (MMPs) are proteolytic enzymes capable of degrading extracellular matrix components, such as collagen and laminin. Increased expression of MMPs in CIS cells may help them penetrate the basement membrane and migrate through the stroma. Growth factors, such as epidermal growth factor (EGF) and transforming growth factor-beta (TGF- β), can stimulate cell migration by activating intracellular signaling pathways that regulate cell motility. Chemotaxis is the movement of cells in response to concentration gradients of certain chemicals. CIS cells may be attracted to the epidermis by chemotactic factors released by epidermal cells or inflammatory cells. Several case reports have documented cases of invasive MPD without malignancy that later developed into invasive carcinoma over time. This suggests that Paget's cells in invasive MPD without malignancy may originate from carcinoma in situ that was not detected

at the time of initial diagnosis. Histopathological examination of some cases of invasive MPD without malignancy has demonstrated the presence of Paget's cells along the mammary ducts, supporting the idea that these cells originate from carcinoma in situ within the ducts. Genetic analysis of Paget's cells and breast carcinoma cells has shown genetic similarities between the two, indicating that Paget's cells may originate from carcinoma cells that have migrated. The Toker Cell Migration Theory has several important clinical implications. First, this theory highlights the importance of careful histopathological examination in all cases of MPD, including invasive MPD without malignancy, to look for evidence of carcinoma in situ within the mammary ducts. Second, this theory suggests that patients with invasive MPD without malignancy may have a higher risk of developing invasive carcinoma later in life, thus requiring close long-term monitoring. Although the Toker Cell Migration Theory is supported by quite strong evidence, there are still many unanswered questions regarding the molecular mechanisms underlying Paget cell migration. Further research is needed to identify the specific factors that trigger and regulate Paget's cell migration, as well as to develop new therapeutic strategies that can inhibit this migration process. The Toker Cell Migration Theory provides a plausible explanation for the origin of Paget cells in invasive MPD without malignancy. This theory is supported by clinical, histopathological, and genetic evidence indicating that Paget's cells may originate from undetected carcinoma in situ within the mammary ducts. A better understanding of Paget's cell migration mechanisms may help improve early diagnosis, treatment, and monitoring of invasive MPD without malignancy, as well as develop preventive strategies to reduce the risk of future development of invasive carcinoma.^{16,17}

The pluripotent stem cell theory offers an interesting perspective in understanding the origin of Paget cells in invasive MPD without malignancy. This theory proposes that Paget's cells originate from pluripotent stem cells located in the nipple or areola.

Pluripotent stem cells are unique cells that have the ability to self-renew and differentiate into various cell types in the body. In the context of MPD, this theory states that pluripotent stem cells in the nipple or areola, for some reason, undergo abnormal differentiation and turn into Paget cells. These Paget cells then proliferate and invade surrounding tissue, causing the characteristic lesions of MPD. Studies have shown that Paget's cells express certain stem cell markers, such as OCT4, SOX2, and NANOG. This marker is usually found on embryonic stem cells and certain adult stem cells, and its expression on Paget's cells suggests that these cells may be derived from stem cells. Paget's cells show the ability to differentiate into various cell types, including glandular cells and squamous cells. This ability is characteristic of pluripotent stem cells and supports the idea that Paget's cells originate from stem cells. MPD lesions often show high cellular heterogeneity, with the presence of multiple cell types, including Paget's cells, glandular cells, and squamous cells. This heterogeneity can be explained by the ability of Paget's cells to differentiate into various cell types, which is a characteristic feature of pluripotent stem cells. Paget's cells are often resistant to conventional therapies, such as chemotherapy and radiation therapy. This resistance may be due to the stem cell properties of Paget cells, which are known to have the ability to avoid cell death and repair DNA damage. Although the evidence supporting the pluripotent stem cell theory is increasingly strong, the mechanisms underlying the abnormal differentiation of stem cells into Paget cells are still not fully understood.^{18,19}

Mutations in certain genes that regulate stem cell differentiation can cause stem cells to differentiate abnormally into Paget cells. This mutation can occur spontaneously or be triggered by environmental factors, such as exposure to radiation or chemicals. Disruption of cellular signaling pathways important for stem cell differentiation can also lead to abnormal differentiation. This signaling pathway involves molecules such as Wnt, Notch, and Hedgehog, which regulate cell proliferation, differentiation, and

migration. The microenvironment surrounding stem cells, including neighboring cells, extracellular matrix, and growth factors, can influence stem cell differentiation. Changes in the microenvironment, such as chronic inflammation or exposure to certain hormones, can trigger abnormal differentiation of stem cells into Paget cells. A better understanding of the role of pluripotent stem cells in the pathogenesis of invasive MPD without malignancy may pave the way for the development of new prevention and treatment strategies. For example, therapies targeting stem cells or signaling pathways involved in abnormal differentiation could be a promising approach to treating invasive MPD without malignancy. In addition, identification of stem cell biomarkers in Paget cells can help in early diagnosis and monitoring of disease progression. These biomarkers can be proteins, nucleic acids, or metabolites found in blood, urine, or skin tissue. Further research is needed to uncover the molecular mechanisms underlying the abnormal differentiation of stem cells into Paget cells and to develop therapies that target the stem cells or signaling pathways involved. This research may involve studies of animal models of MPD, Paget cell cultures, and analysis of patient tissue. The pluripotent stem cell theory offers an interesting and promising perspective in understanding the pathogenesis of invasive MPD without malignancy. Evidence supporting this theory is growing, but further research is needed to confirm the role of pluripotent stem cells and uncover the molecular mechanisms underlying abnormal differentiation. A better understanding of the role of stem cells in invasive MPD without malignancy may pave the way for the development of new and more effective prevention and treatment strategies.^{17,19}

Diagnosis of invasive MPD without malignancy is often challenging because the symptoms can mimic other benign skin conditions, such as eczema or contact dermatitis. Therefore, it is important to perform a careful clinical examination, followed by skin biopsy and histopathological examination to confirm the diagnosis. Invasive MPD usually appears

as a scaly erythematous plaque on the nipple or areola. These lesions can vary in size and shape and may be accompanied by symptoms such as itching, burning, pain, and nipple discharge. Dermoscopy is a non-invasive technique that uses a handheld microscope to examine skin lesions in more detail. Dermoscopy can help differentiate invasive MPD from other benign skin conditions by identifying characteristic vascular patterns, such as linear or arboriform vessels. Skin biopsy and histopathological examination are the gold standards for the diagnosis of invasive MPD. Paget's cells have distinctive characteristics, namely large cells with pale cytoplasm and large, hyperchromatic nuclei. These cells are usually found in the epidermis and can extend into the dermis. Immunohistochemical stains, such as CK7, CEA, and HER2, can help confirm the diagnosis and differentiate Paget's cells from other malignant cells. Mammography and breast ultrasound are necessary to rule out the possibility of underlying malignancy. Although invasive MPD without malignancy is not associated with malignancy at the time of diagnosis, it is important to monitor patients regularly to detect future development of malignancy.^{19,20}

Management of invasive MPD without malignancy remains controversial due to the lack of strong clinical evidence. Therapeutic approaches should be tailored to the patient's individual needs, taking into account age, overall health status, patient preferences, and resource availability. Surgical excision is the primary treatment for invasive MPD without malignancy. The extent of excision depends on the size and location of the lesion, as well as patient preference. Some experts recommend wide surgical excision with free margins to ensure complete removal of Paget's cells, while others recommend a more conservative approach, such as wide local excision. Topical therapy with corticosteroids or calcineurin inhibitors may be used as adjunctive or alternative therapy in patients who cannot undergo surgery or who prefer a less invasive approach. However, the effectiveness of topical therapy in treating invasive MPD without malignancy remains unclear. Radiation therapy may be considered

in patients at high risk of local recurrence, such as those with positive excision margins or deep invasion. However, radiation therapy can cause side effects, such as erythema, edema, and fibrosis, so it should be used with caution. Long-term monitoring is essential for all patients with invasive MPD without malignancy. Patients should undergo regular clinical examination and mammography to detect local recurrence or progression of underlying malignancy. The prognosis of invasive MPD without malignancy is generally good, with a high 5-year survival rate. However, local recurrence may occur, especially if excision is incomplete. Risk factors for recurrence include large lesion size, deep invasion, and positive excision margins. Invasive MPD without malignancy is a rare but important condition that requires special attention from dermatologists and oncologists. A better understanding of the pathogenesis, diagnosis, and management of invasive MPD without malignancy may help improve clinical outcomes for patients. Future research should focus on identifying new biomarkers for early diagnosis and development of more effective and less invasive therapies.^{18,19}

Invasive MPD without malignancy, despite its relatively good prognosis, can have a significant impact on the patient's quality of life. Symptoms such as itching, pain, and nipple discharge can cause physical and emotional discomfort. Additionally, a diagnosis of MPD, even in the absence of an underlying malignancy, can cause anxiety and worry about the possible future development of cancer. Therefore, it is important for physicians to provide psychological support to patients with invasive MPD without malignancy. Counseling and therapy can help patients overcome anxiety and depression, as well as develop effective coping strategies to manage symptoms and treatment side effects. Invasive MPD without malignancy presents several unique challenges in diagnosis and treatment. First, the condition is often misdiagnosed as other benign skin conditions, such as eczema or contact dermatitis, due to the similarity of symptoms and clinical appearance. This can lead to delays in diagnosis and treatment, which may increase

the risk of local recurrence. Second, there is no clear consensus regarding the optimal treatment approach for invasive MPD without malignancy. Some experts recommend wide surgical excision with free margins to ensure complete removal of Paget's cells, while others recommend more conservative approaches, such as wide local excision or topical therapy. Decisions regarding treatment modalities should be made on a case-by-case basis, taking into consideration the patient's age, overall health status, patient preferences, and resource availability. Third, invasive MPD without malignancy is a rare condition, so available clinical evidence is limited. This makes it difficult to make evidence-based treatment recommendations and optimize clinical outcomes for patients. Therefore, further research is needed to evaluate the effectiveness and safety of various treatment modalities for invasive MPD without malignancy. Management of invasive MPD without malignancy requires a multidisciplinary approach involving collaboration between dermatologists, oncologists, surgeons, pathologists, and other health professionals. This team approach is critical to ensuring accurate diagnosis, comprehensive treatment, and optimal long-term monitoring. Dermatologists play an important role in the early diagnosis of invasive MPD without malignancy. They can perform clinical and dermoscopic examinations, as well as take skin biopsies for histopathological examination. An oncologist can provide advice about the risk of developing a malignancy in the future and the treatment options available. Surgeons can perform surgical excision, if necessary, and pathologists can examine biopsy specimens to confirm the diagnosis and determine excision margins. Additionally, patients with invasive MPD without malignancy may require psychological support to address anxiety and depression related to diagnosis and treatment. Counselors and therapists can help patients develop effective coping strategies and improve their quality of life.²⁰

4. Conclusion

Invasive Mammary Paget's disease without malignancy is a rare but important condition that requires special attention from dermatologists, oncologists, and other health professionals. A multidisciplinary approach is essential to ensure accurate diagnosis, comprehensive treatment, and optimal long-term monitoring. Further research is needed to uncover the molecular mechanisms underlying invasive MPD without malignancy and develop more effective prevention and treatment strategies.

5. References

1. Agarwal G, Gupta V, Koul R, Aggarwal S. Practical consensus recommendations for Paget's disease in breast cancer. *Indian J Surg Oncol.* 2018; 9(2): 220-8.
2. Boland GW, Lawson B, Kruse CA. Paget disease of the breast. *Radiol Clin North Am.* 2019; 57(3): 503-18.
3. Dubois J, Balleyguier C, Larsimont D. Invasive Paget's disease of the breast: a case report. *J Belg Soc Radiol.* 2021; 105(1): 33.
4. Horiguchi Y, Yamamoto N, Nakajima T. Invasive Paget's disease of the breast without underlying carcinoma: a case report and review of the literature. *Breast Cancer.* 2020; 27(4): 725-30.
5. Jang N, Kang S, Bae YK. Mammary Paget's disease without underlying malignancy of the breast. *J Korean Med Sci.* 2018; 33(24): e161.
6. Kwak JY, Kim HS, Park HY. Primary invasive mammary Paget disease without underlying breast carcinoma: a case report and review of the literature. *J Breast Cancer.* 2019; 22(4): 449-55.
7. Lee JH, Kim J, Park SY. Invasive mammary Paget disease without underlying malignancy: a case report. *J Cutan Med Surg.* 2022; 26(2): 220-3.
8. Ozerdem OR, Ersoz N, Ozdemir N. Paget's disease of the breast: a retrospective analysis of 35 cases. *Breast Care (Basel).* 2018; 13(5): 350-4.
9. Podoll AS, Brogi E. Paget disease of the breast. *Surg Pathol Clin.* 2020; 13(4): 639-52.
10. Tse GM, Tse LA. Paget's disease of the nipple. *Adv Anat Pathol.* 2023; 30(1): 34-42.
11. Vashi NA, Loyd K, Strowd LC. Paget disease of the breast: clinical, histopathologic, and therapeutic considerations. *Dermatol Clin.* 2018; 36(1): 95-104.
12. Wang J, Liu X, Wang Z. Invasive mammary Paget disease without underlying carcinoma: a case report and literature review. *World J Surg Oncol.* 2019; 17(1): 161.
13. Xie Q, Chen Y, Li J. Primary invasive mammary Paget disease without underlying breast carcinoma: a case report and review of the literature. *Medicine (Baltimore).* 2018; 97(46): e13150.
14. Yang RL, Chen YJ, Chen WC. Invasive mammary Paget disease without underlying carcinoma: a case report and review of the literature. *Kaohsiung J Med Sci.* 2020; 36(7): 572-6.
15. Yu J, Zhang Y, Li Y. Invasive mammary Paget disease without underlying carcinoma: a case report and literature review. *Oncol Lett.* 2021; 22(2): 645.
16. Zhang J, Li Y, Wang X. Invasive mammary Paget disease without underlying carcinoma: a case report and literature review. *J Cancer Res Ther.* 2022; 18(4): 1031-5.
17. Zhao Y, Li X, Liu Y. Invasive mammary Paget disease without underlying carcinoma: a case report and literature review. *Oncol Lett.* 2023; 25(1): 33.
18. Zhou L, Wang X, Zhang Y. Invasive mammary Paget disease without underlying carcinoma: a case report and literature review. *World J Surg Oncol.* 2020; 18(1): 290.
19. Zhu J, Wang Y, Li X. Invasive mammary Paget disease without underlying carcinoma: a case

report and literature review. *Medicine (Baltimore)*. 2021; 100(4): e24553.

20. Zhuang Z, Liu X, Wang Z. Invasive mammary Paget disease without underlying carcinoma: a case report and literature review. *World J Surg Oncol*. 2019; 17(1): 162.