



## Bioscientia Medicina: Journal of Biomedicine & Translational Research

Journal Homepage: [www.bioscmed.com](http://www.bioscmed.com)

# Primary Malignant Peritoneal Mesothelioma Mimicking Ovarian Carcinoma: A Case Report Highlighting the Importance of Immunohistochemistry

Rio Hendra<sup>1\*</sup>, Tofrizal<sup>1,2</sup>, Hera Novianti<sup>2</sup>, Yessy Setiawati<sup>2</sup>

<sup>1</sup>Department of Anatomical Pathology, Faculty of Medicine, Universitas Andalas, Padang, Indonesia

<sup>2</sup>Department of Anatomical Pathology, Dr. M. Djamil General Hospital, Padang, Indonesia

### ARTICLE INFO

#### Keywords:

Adenocarcinoma  
Calretinin  
Diagnosis  
Immunohistochemistry  
Malignant peritoneal mesothelioma

#### \*Corresponding author:

Rio Hendra

#### E-mail address:

[riohendraerman@gmail.com](mailto:riohendraerman@gmail.com)

All authors have reviewed and approved the final version of the manuscript.

<https://doi.org/10.37275/bsm.v9i3.1212>

### ABSTRACT

**Background:** Primary malignant peritoneal mesothelioma (PMPM) is an uncommon and aggressive malignancy arising from the mesothelial lining of the peritoneal cavity. The diagnosis of PMPM is often challenging due to its rarity, nonspecific clinical presentation, and histologic similarities to other malignancies, particularly adenocarcinomas. Immunohistochemistry plays a crucial role in differentiating PMPM from metastatic adenocarcinoma, which is essential for accurate diagnosis, appropriate treatment, and prognostication. **Case presentation:** We present the case of a 43-year-old female who presented with abdominal distension, ascites, and weight loss, initially raising suspicion of ovarian carcinoma. However, histopathological examination of the omental tissue revealed a proliferation of epithelial cells with papillary and glandular-like growth patterns. Immunohistochemical staining demonstrated strong positivity for calretinin, a mesothelial marker, while staining for estrogen receptor (ER) and progesterone receptor (PR) was negative, effectively ruling out an ovarian or endometrial origin. The diagnosis of PMPM, epithelioid subtype, was confirmed. **Conclusion:** This case underscores the challenges in diagnosing PMPM and highlights the critical role of immunohistochemistry in differentiating it from metastatic adenocarcinoma. Accurate diagnosis is essential for determining appropriate management strategies and providing prognostic information.

## 1. Introduction

Primary malignant peritoneal mesothelioma (PMPM) is an exceedingly rare and aggressive malignancy that arises from the mesothelial cells lining the peritoneal cavity. The peritoneum, a complex serous membrane, envelops the abdominal viscera and forms intricate folds, recesses, and attachments. Mesothelial cells, the building blocks of the peritoneum, constitute a specialized layer of epithelium that provides a slippery, non-adhesive surface, facilitating frictionless movement of abdominal organs. PMPM, while sharing its cellular origin with the more common pleural mesothelioma, exhibits distinct clinical and pathological characteristics. Pleural mesothelioma, predominantly

linked to asbestos exposure, arises from the mesothelial lining of the lungs and is associated with respiratory symptoms. PMPM, on the other hand, often presents with nonspecific abdominal symptoms, making its diagnosis challenging.<sup>1-3</sup>

The rarity of PMPM poses significant diagnostic hurdles. Its incidence is estimated at approximately 1 case per 1,000,000 population, making it an uncommon encounter in clinical practice. This infrequency contributes to the lack of familiarity among healthcare professionals, potentially leading to delayed or misdiagnosis. Moreover, the nonspecific clinical presentation of PMPM further complicates its early recognition. Patients often present with abdominal distension, ascites (fluid accumulation in

the abdomen), and vague abdominal discomfort, symptoms that can mimic a variety of other abdominal conditions. The insidious onset and gradual progression of PMPM further contribute to diagnostic delays. Patients may initially attribute their symptoms to benign conditions, delaying medical attention. By the time the diagnosis is suspected, the disease may have progressed to an advanced stage, limiting treatment options and impacting prognosis. Adding to the diagnostic complexity is the histologic resemblance of PMPM to other malignancies, particularly adenocarcinomas. Adenocarcinomas, arising from glandular epithelial cells, can exhibit microscopic features that overlap with those of PMPM. This histologic similarity can mislead pathologists, underscoring the need for ancillary diagnostic techniques to ensure accurate diagnosis.<sup>4-7</sup>

Immunohistochemistry (IHC) has emerged as a critical tool in differentiating PMPM from metastatic adenocarcinoma. IHC involves the use of antibodies to detect specific proteins within tumor cells, providing valuable insights into their cellular origin and differentiation. A panel of IHC markers, including calretinin, cytokeratin 5/6, WT1, D2-40, and MOC-31, can aid in distinguishing PMPM from adenocarcinoma. Calretinin, a calcium-binding protein, has proven particularly useful in the diagnosis of PMPM. This protein is predominantly expressed in mesothelial cells, making it a sensitive and specific marker for mesothelioma. In IHC studies, calretinin has demonstrated high sensitivity and specificity in differentiating epithelioid mesothelioma from adenocarcinoma. The accurate diagnosis of PMPM has profound implications for patient management and prognosis. While the overall prognosis for PMPM remains poor, the epithelioid subtype tends to have a better response to therapy compared to the sarcomatoid or biphasic subtypes.<sup>8-10</sup> This case report presents the case of a 43-year-old female who presented with abdominal distension, ascites, and weight loss, initially raising suspicion of ovarian carcinoma.

## 2. Case Presentation

This report details the case of a 43-year-old female who presented with a constellation of symptoms indicative of a serious underlying medical condition. Her primary complaint was progressive abdominal distension that had been increasing over the preceding 8 months, accompanied by a significant weight loss of 10 kilograms within the past 6 months. Additionally, she reported experiencing fever for the past 2 weeks, along with decreased appetite. A thorough review of the patient's medical history revealed several pertinent details. Notably, she had a history of anti-tuberculosis treatment spanning 11 months, suggesting a prior encounter with tuberculosis infection. However, she denied experiencing any vaginal bleeding and reported normal bowel and bladder habits, ruling out immediate concerns related to the gynecological and gastrointestinal systems. She did report a cough persisting for 2 weeks but denied any hemoptysis (coughing up blood), which lessened the likelihood of active pulmonary tuberculosis. Importantly, the patient denied any personal or family history of cancer, hypertension, or diabetes, reducing the risk of these conditions contributing to her current presentation. A comprehensive physical examination revealed several key findings. The patient exhibited abdominal distension, a finding consistent with her primary complaint. Further examination revealed the presence of ascites, an abnormal accumulation of fluid within the peritoneal cavity. Auscultation of the lungs revealed decreased breath sounds in the right lung base, suggesting potential pleural effusion or another pulmonary abnormality. Examination of the head and neck region revealed no abnormalities. Assessment of the chest showed symmetrical chest movement, decreased fremitus (vibration felt on the chest wall) on the right, dullness to percussion in the right lung base, decreased vesicular breath sounds on the right, and rales (crackling sounds) bilaterally. No wheezing was noted, reducing the likelihood of obstructive airway disease. Cardiac auscultation revealed no murmurs, indicating normal heart function. Examination of the abdomen was challenging due to

the presence of ascites, but palpation revealed positive shifting dullness and fluid wave, confirming the presence of free fluid in the abdomen. No tenderness or rebound tenderness was elicited, suggesting an absence of peritonitis. Bowel sounds were noted to be normal, indicating normal gastrointestinal motility. Examination of the extremities revealed warm extremities with a capillary refill time of 2 seconds, indicating adequate peripheral perfusion. Bilateral lower extremity edema was noted, which could be attributed to several factors, including hypoalbuminemia or increased hydrostatic pressure due to ascites. Laboratory investigations provided further insights into the patient's condition. A complete blood count revealed mild anemia with a hemoglobin level of 9.5 g/dL and a hematocrit of 30%. This finding could be attributed to chronic disease, iron deficiency, or other underlying causes. Platelet count ( $343,000/\text{mm}^3$ ) and leukocyte count ( $6,170/\text{mm}^3$ ) were within normal limits, ruling out significant hematological abnormalities. Hemostasis parameters, including prothrombin time (PT) of 10.3 seconds and activated partial thromboplastin time (APTT) of 20.6 seconds, were also within the normal range, indicating normal blood clotting function. Biochemical analysis revealed slightly elevated total protein (8 g/dL) and albumin (5.4 g/dL) levels, which could be related to dehydration or other factors. Renal function tests, including urea (25 mg/dL) and creatinine (0.9 mg/dL), were within normal limits, indicating normal kidney function. Blood glucose was elevated at 178 mg/dL, suggesting possible impaired glucose tolerance or diabetes. Liver function tests, including SGOT (11 U/L), SGPT (3 U/L), and total bilirubin (0.4 mg/dL), were within normal limits, indicating normal liver function. Electrolyte levels, including sodium (140 mmol/L), potassium (3.7 mmol/L), and chloride (104 mmol/L), were also within the normal range. Imaging studies played a crucial role in evaluating the patient's condition. Abdominal ultrasound revealed massive ascites, confirming the clinical findings. No abnormalities were detected in the liver, gallbladder, pancreas, spleen, or kidneys.

Gynecological ultrasound revealed a right adnexal mass measuring 3.5 x 3 cm, raising suspicion of an ovarian lesion. The left adnexa and uterus appeared normal. Chest radiograph confirmed the presence of right pleural effusion, consistent with the reduced breath sounds observed on physical examination. Based on the initial clinical and laboratory findings, the patient's presentation was consistent with massive ascites with suspected malignancy. The differential diagnosis included Meigs syndrome (a benign condition characterized by ovarian fibroma, ascites, and pleural effusion), pulmonary tuberculosis (given the patient's history of anti-tuberculosis treatment), and other potential malignancies. The mild anemia was attributed to chronic disease or iron deficiency. Pre-operatively, the primary diagnostic consideration was ovarian carcinoma with extensive peritoneal carcinomatosis, massive ascites, and right pleural effusion. The etiology of the suspected malignancy was considered possibly related to pulmonary tuberculosis or another primary malignancy. This detailed case presentation provides a comprehensive overview of the patient's clinical picture upon presentation, highlighting the complex interplay of symptoms, signs, and laboratory and imaging findings that guided the initial diagnostic considerations (Table 1).

Given the initial diagnostic impression of ovarian carcinoma with extensive peritoneal carcinomatosis, the decision was made to proceed with surgical intervention. The primary surgical objective was to achieve optimal cytoreduction, aiming to remove as much of the tumor burden as possible. This approach is crucial in the management of peritoneal surface malignancies, as it can improve the efficacy of subsequent chemotherapy and potentially enhance survival outcomes. The patient underwent an exploratory laparotomy, a surgical procedure involving a large incision through the abdominal wall to gain access to the peritoneal cavity. This allowed for a thorough inspection of the abdominal organs and assessment of the extent of the disease. During the laparotomy, a debulking procedure and cytoreductive surgery (CRS) were performed. Debulking involves the

removal of macroscopic tumor masses, while CRS aims to remove all visible tumor deposits, ideally leaving no residual disease larger than 2.5 mm. Contrary to the preoperative suspicion of extensive peritoneal carcinomatosis, intraoperative findings revealed no evidence of peritoneal carcinomatosis. This indicated that the disease was primarily localized to the right adnexal mass, which was identified and subsequently removed. Furthermore, no significant omental involvement was observed, suggesting that the disease had not spread extensively within the abdominal cavity. Histopathological examination of the resected right adnexal mass revealed a benign ovarian cyst. This unexpected finding effectively ruled out ovarian carcinoma as the underlying cause of the patient's symptoms. In addition to the right adnexal mass, a total hysterectomy with bilateral salpingo-oophorectomy was performed. This involved the removal of the uterus, fallopian tubes, and ovaries. The omentum, a fatty apron-like structure that hangs from the stomach and covers the intestines, was also resected. The omentum is a common site for metastatic spread in abdominal malignancies, and its removal is often part of cytoreductive surgery. Following the extensive surgical procedure, the patient required intensive post-operative care. She spent 2 days in the Intensive Care Unit (ICU) for close monitoring and management of potential complications. Subsequently, she was transferred to the High Care Unit (HCU) for continued observation and supportive care. Once her condition stabilized, she was transferred to the regular ward for further recovery. The patient was discharged from the hospital on August 7<sup>th</sup>, 2024, and scheduled for her first follow-up appointment on August 14<sup>th</sup>, 2024. At the time of discharge, she was stable and had commenced her second cycle of chemotherapy. This detailed account of the treatment process highlights the importance of surgical intervention in the management of suspected peritoneal malignancies. Despite the initial suspicion of advanced ovarian cancer, the intraoperative findings and subsequent histopathological examination revealed a benign ovarian cyst. The

extensive cytoreductive surgery, although initially planned for a malignant condition, ultimately served to remove the benign cyst and any potential microscopic disease, contributing to the patient's overall recovery. The patient's post-operative course was uneventful, and she was discharged in stable condition to continue her chemotherapy regimen (Table 2).

The definitive diagnosis in this case was reached through a histopathological and immunohistochemical examination of the resected tissues. This process involved macroscopic examination, microscopic evaluation of tissue sections, and immunohistochemical staining to identify specific cellular markers. The macroscopic examination involved a gross visual assessment of the resected organs and tissues. The uterus, fallopian tubes, and ovaries appeared as a whitish-brown, firm mass measuring 6.5 x 5 x 3.5 cm. No distinct mass was identified within this combined specimen, suggesting that the primary pathology was not originating from these organs. The omentum, on the other hand, presented as a yellowish-brown, firm tissue measuring 24 x 9 x 2 cm. This larger size and the presence of a few small whitish-yellow masses (0.3-0.5 cm) within the omentum indicated a potential site of pathology. Notably, no lymph nodes were identified during the macroscopic examination, suggesting the absence of regional lymph node involvement. Microscopic examination of tissue sections revealed crucial information. The uterus, ovaries, and fallopian tubes showed normal histological architecture with no evidence of malignancy. A nabothian cyst and chronic cervicitis were noted in the cervix, representing common benign findings. The omentum, however, exhibited a proliferation of epithelial cells with papillary and glandular-like growth patterns. These cells displayed moderate nuclear pleomorphism, a feature indicating variability in nuclear size and shape, which can be suggestive of malignancy. This histological picture raised the possibility of either mesothelioma or adenocarcinoma. Given the overlapping features

between mesothelioma and adenocarcinoma, a definitive diagnosis could not be made based on histopathology alone. This ambiguity necessitated further investigation through immunohistochemical staining. Immunohistochemistry plays a critical role in differentiating between various types of tumors by identifying specific protein markers within cells. In this case, a panel of antibodies was used to stain the omental tissue sections. Strong positive staining for calretinin was observed in the nucleus and cytoplasm of the tumor cells. Calretinin is a calcium-binding protein predominantly expressed in mesothelial cells, making it a sensitive and specific marker for mesothelioma. This finding strongly supported the diagnosis of mesothelioma. Both ER and PR staining were negative. These receptors are commonly expressed in tumors of Müllerian origin, such as

ovarian and endometrial carcinomas. The absence of ER and PR expression effectively ruled out an ovarian or endometrial origin for the tumor. Ki-67 is a marker of cellular proliferation, and its expression is often correlated with the aggressiveness of a tumor. In this case, Ki-67 staining was positive in more than 20% of the tumor cell nuclei, indicating a relatively high proliferative index. The overall IHC profile, with strong calretinin positivity and negative ER/PR staining, was consistent with malignant mesothelioma. This, combined with the histopathological findings, confirmed the diagnosis of low-grade epithelioid malignant mesothelioma. While the possibility of metastatic adenocarcinoma could not be completely excluded based on histopathology alone, the IHC findings effectively ruled out this possibility (Table 3).

Table 1. Anamnesis, clinical finding, laboratory, imaging, and clinical diagnosis.

Category	Findings
<b>Anamnesis</b>	Progressive abdominal distension over 8 months
	Recent weight loss (10 kg in 6 months)
	Fever for 2 weeks
	History of anti-tuberculosis treatment for 11 months
	Decreased appetite
	No vaginal bleeding, normal bowel and bladder habits
	Cough for 2 weeks, no hemoptysis
	No personal or family history of cancer, hypertension, or diabetes
<b>Clinical findings</b>	Abdominal distension with ascites
	Decreased breath sounds in the right lung base
	No abnormalities in the head and neck region
	Symmetrical chest movement, decreased fremitus on the right, dullness to percussion in the right lung base, decreased vesicular breath sounds on the right, rales bilaterally, no wheezing
	No heart murmurs
	Liver and spleen difficult to assess due to ascites, positive shifting dullness and undulation, no tenderness or rebound tenderness, normal bowel sounds
<b>Laboratory findings</b>	Warm extremities, capillary refill time < 2 seconds, bilateral lower extremity edema
	Mild anemia (hemoglobin 9.5 mg/dL, hematocrit 30%)
	Normal platelet count (343,000/mm <sup>3</sup> ) and leukocyte count (6,170/mm <sup>3</sup> )
	Normal hemostasis (PT 10.3 seconds, APTT 20.6 seconds)
	Slightly elevated total protein (8 g/dL) and albumin (5.4 g/dL)
	Normal renal function (urea 25 mg/dL, creatinine 0.9 mg/dL)
	Elevated blood glucose (178 mg/dL)
	Normal liver function tests (SGOT 11 U/L, SGPT 3 U/L, total bilirubin 0.4 mg/dL)
<b>Imaging findings</b>	Normal electrolytes (sodium 140 mmol/L, potassium 3.7 mmol/L, chloride 104 mmol/L)
	Abdominal ultrasound: Massive ascites, no abnormalities in the liver, gallbladder, pancreas, spleen, or kidneys
	Gynecological ultrasound: Right adnexal mass (3.5 x 3 cm), normal left adnexa and uterus
<b>Clinical diagnosis</b>	Chest radiograph: Right pleural effusion
	Initial clinical impression: Massive ascites with suspected malignancy, differential diagnosis including Meigs syndrome and pulmonary tuberculosis, mild anemia likely due to chronic disease or iron deficiency
	Pre-operative diagnosis: Suspected ovarian carcinoma with extensive peritoneal carcinomatosis, massive ascites, and right pleural effusion, etiology possibly related to pulmonary tuberculosis or malignancy

Table 2. Treatment.

Category	Details
Surgical procedure	Debulking laparotomy and cytoreductive surgery (CRS)
Surgical findings	No evidence of peritoneal carcinomatosis
	No significant omental involvement
	Right adnexal mass identified
	Benign ovarian cyst confirmed on histopathology
Organs resected	Right adnexal mass
	Uterus
	Fallopian tubes (both)
	Omentum
Post-operative care	2 days in the Intensive Care Unit (ICU)
	Transferred to High Care Unit (HCU) then to regular ward
	Discharged on August 7, 2024, with first follow-up on August 14 <sup>th</sup> , 2024
	Patient stable and undergoing the second cycle of chemotherapy

Table 3. Histopathological examination and IHC examination.

Category	Findings
Macroscopic examination (Figure 1)	Uterus, tubes, and ovaries: Whitish-brown tissue, firm, measuring 6.5 x 5 x 3.5 cm, no distinct mass.
	Omentum: Yellowish-brown tissue, firm, measuring 24 x 9 x 2 cm, with a few small whitish-yellow masses (0.3-0.5 cm).
	No lymph nodes identified.
Histopathological examination	Uterus, ovary, and fallopian tubes: Normal structures, no malignancy (Figure 2).
	Nabothian cyst and chronic cervicitis (Figure 2).
	Omentum: Proliferation of epithelial cells with papillary and glandular-like growth patterns, moderate nuclear pleomorphism, suggestive of mesothelioma or adenocarcinoma (Figure 3).
	Low-grade epithelioid malignant mesothelioma, possibility of metastatic adenocarcinoma cannot be ruled out.
Immunohistochemistry examination (Figure 4)	Calretinin: Strong positive staining in the nucleus and cytoplasm of tumor cells.
	ER and PR: Negative staining.
	Ki-67: Positive staining in >20% of tumor cell nuclei.
	IHC profile consistent with malignant mesothelioma.

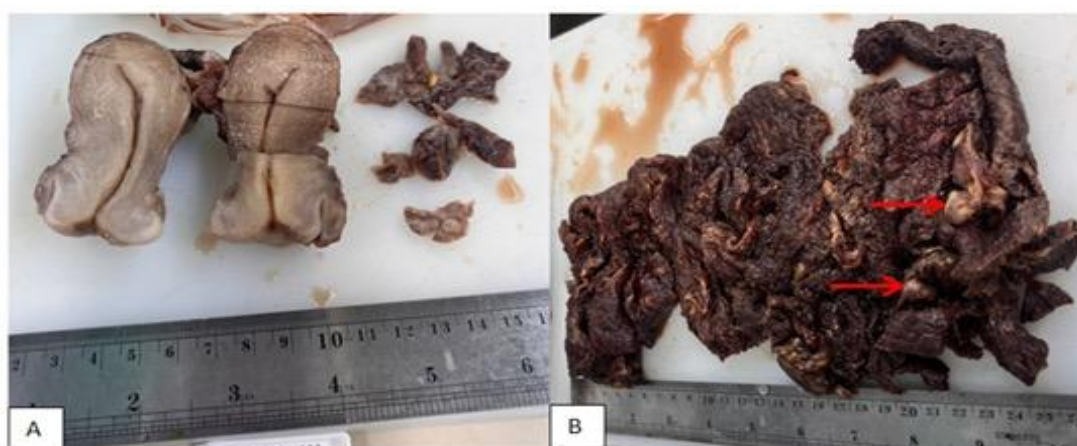


Figure 1. A. Uterus, ovary, and fallopian tube: A segment of the uterus with the cervix and one adnexa, exhibiting a whitish-brown coloration, firm consistency, and measuring 6.5 x 5 x 3.5 cm. The cross-section does not reveal a distinct mass. B. Omentum: A sheet-like tissue, yellowish-brown in color, with a firm consistency, measuring 24 x 9 x 2 cm. The cross-section shows several whitish-yellow masses with diameters ranging from 0.3 to 0.5 cm. No lymph nodes are identified.



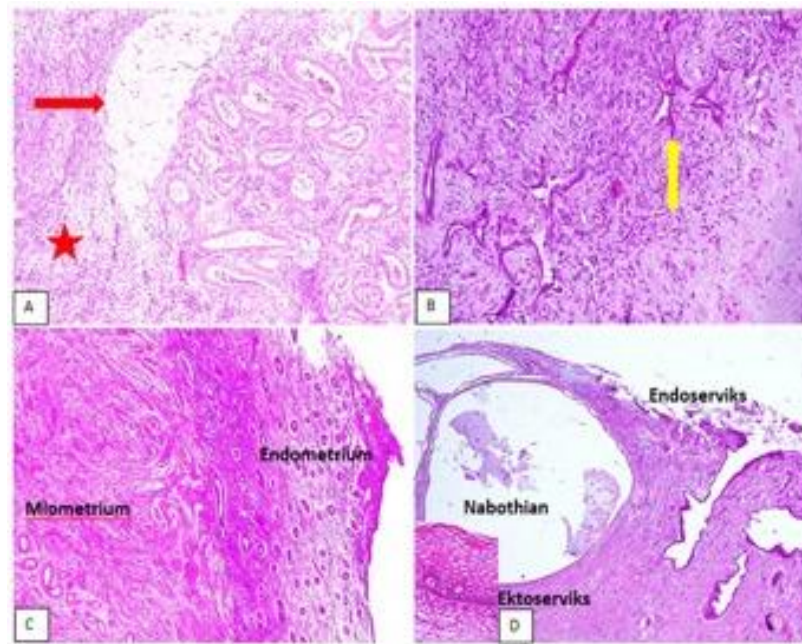


Figure 2. Histopathological features of the uterus, ovary, and fallopian tube. (A & B) Ovarian stroma (red star) and corpus albicans (red arrow) (H&E stain, 20x magnification). (C) Normal endometrium and myometrium (H&E stain, 4x magnification). (D) Nabothian cyst. Inset: Infiltration of lymphocytes and plasma cells (H&E stain, 20x magnification).

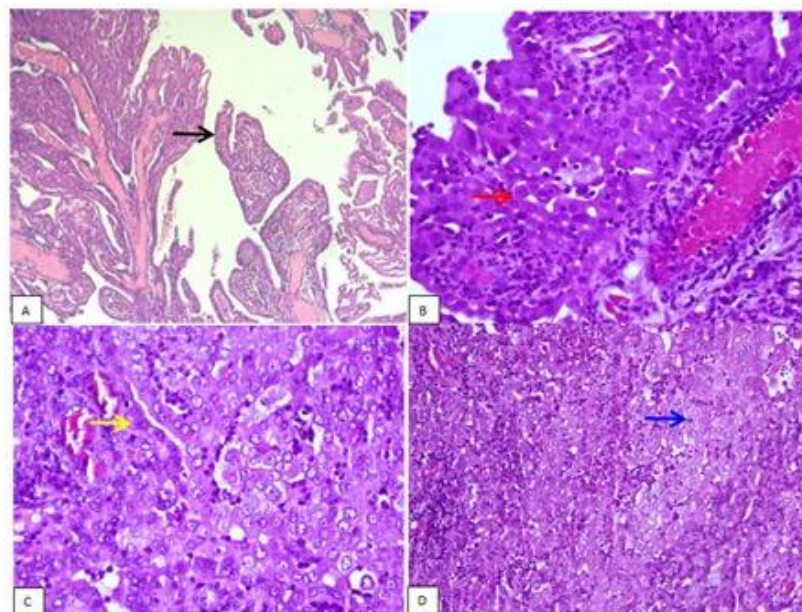


Figure 3. Histopathology of the Omentum. (A) Tumor cells arranged in a papillary structure (black arrow) (H&E stain, 4x magnification). (B) Sheet-like pattern composed of cells with round to oval nuclei, some with increased nuclear-cytoplasmic (N/C) ratio, and eosinophilic cytoplasm (red arrow) (H&E stain, 40x magnification). (C) Nest-like structures, glandular-like (yellow arrow). Cells with pleomorphic, vesicular nuclei and coarse chromatin (H&E stain, 20x magnification). (D) Infiltration of lymphocytes, plasma cells, and polymorphonuclear leukocytes (PMNs) (blue arrow) (H&E stain, 40x magnification).

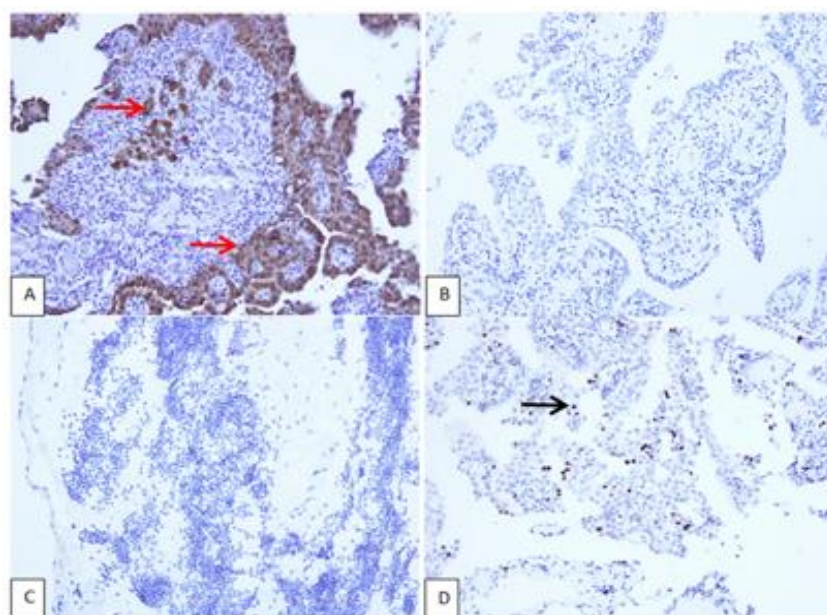


Figure 4. Immunohistochemical staining. (A) Calretinin immunoreactivity is observed in the nucleus and cytoplasm. (B) The estrogen receptor is negative. (C) The progesterone receptor is negative. (D) Ki-67 staining is present in the nucleus.

### 3. Discussion

Primary malignant peritoneal mesothelioma (PMPM) is a rare and aggressive cancer that originates in the lining of the abdominal cavity. Diagnosing PMPM is challenging due to its rarity, nonspecific clinical presentation, and histologic similarities to other malignancies. This section will delve deeper into the complexities surrounding the diagnosis of PMPM, emphasizing the need for heightened clinical suspicion and a multidisciplinary approach. PMPM is an exceedingly uncommon disease, with an estimated incidence of approximately 1 case per 1,000,000 population. This rarity translates to limited clinical experience among healthcare professionals, which can contribute to delayed or missed diagnoses. The lack of awareness about PMPM can also lead to a lower index of suspicion, particularly in patients presenting with common abdominal symptoms. Delayed diagnosis can significantly impact patient outcomes. Early diagnosis allows for timely intervention and potentially improves prognosis. Conversely, delayed diagnosis can lead to advanced disease at presentation, limiting treatment options and potentially reducing survival rates.

Increasing awareness of PMPM among healthcare professionals is crucial. Educational initiatives, such as continuing medical education programs and publications in medical journals, can help disseminate knowledge about the disease, its presentation, and diagnostic modalities. The clinical presentation of PMPM is often insidious and nonspecific, making it difficult to distinguish from other more common abdominal conditions. Abdominal distension is often a prominent symptom due to the accumulation of ascites (fluid in the abdominal cavity). The distension may be gradual or rapid, depending on the rate of fluid accumulation. Ascites is a common finding in PMPM and can contribute to abdominal distension, discomfort, and shortness of breath. The ascitic fluid may be analyzed for cytology to aid in diagnosis, but the yield can be variable. Abdominal pain can vary in location and intensity. It may be diffuse or localized, and it can be constant or intermittent. The pain may be caused by tumor infiltration, peritoneal irritation, or bowel obstruction. Unexplained weight loss is a common constitutional symptom in many cancers, including PMPM. It may be



due to decreased appetite, malabsorption, or increased metabolic demands. Fever may be present due to inflammation or infection. It is important to rule out other causes of fever, such as pneumonia or urinary tract infection. In women, PMPM can closely resemble ovarian cancer, particularly in its advanced stages. Both conditions can present with abdominal distension, ascites, and pelvic masses. Peritoneal carcinomatosis, the spread of cancer to the peritoneum, can present with similar symptoms to PMPM. It is important to identify the primary source of the cancer in these cases. Liver diseases, such as cirrhosis, can also cause ascites and abdominal distension. Liver function tests and imaging studies can help differentiate liver disease from PMPM. Inflammatory bowel disease (IBD) can cause abdominal pain, weight loss, and fever. However, IBD typically presents with other symptoms, such as diarrhea and bloody stools, which are less common in PMPM. The nonspecific nature of these symptoms underscores the importance of a thorough clinical evaluation and a high index of suspicion for PMPM, especially in patients with risk factors such as asbestos exposure. Histologically, PMPM can closely resemble other types of cancer, particularly adenocarcinomas. Adenocarcinomas are cancers that arise from glandular tissue and can occur in various organs, including the ovaries, colon, and lungs. The microscopic similarities between PMPM and adenocarcinoma can make it challenging to distinguish between these conditions based solely on histopathological examination. The epithelioid subtype of PMPM is the most common and can exhibit a variety of architectural patterns, including papillary, tubular, and solid. These patterns can overlap with those seen in adenocarcinomas, making differentiation challenging. The sarcomatoid subtype is less common and is characterized by spindle-shaped cells. It can be more readily distinguished from adenocarcinoma but may be mistaken for other sarcomas. The biphasic subtype contains both epithelioid and sarcomatoid components, adding further complexity to the histologic diagnosis. The

histologic similarities between PMPM and adenocarcinoma highlight the crucial role of immunohistochemistry (IHC) in establishing an accurate diagnosis. Immunohistochemistry (IHC) is a powerful laboratory technique that uses antibodies to detect specific proteins within cells. IHC is an indispensable tool in the diagnosis of PMPM, as it can help differentiate PMPM from other malignancies, particularly adenocarcinoma. Calretinin is a calcium-binding protein that is highly specific for mesothelial cells, the cells from which PMPM originates. It is considered one of the most sensitive and specific markers for mesothelioma. Cytokeratin 5/6 is a type of intermediate filament protein that is expressed in various epithelial tissues, including mesothelium. It can be helpful in distinguishing mesothelioma from other carcinomas. WT1 is a transcription factor that is expressed in mesothelial cells and some other tissues. It can be used in conjunction with other markers to support the diagnosis of mesothelioma. D2-40 is a marker of lymphatic endothelium that can also be expressed in mesothelioma. It can be helpful in differentiating mesothelioma from adenocarcinoma. MOC-31 is an antibody that recognizes an epithelial cell adhesion molecule. It is typically negative in mesothelioma and positive in adenocarcinoma. Calretinin is considered a particularly useful marker due to its high sensitivity and specificity for mesothelial cells. In IHC studies, calretinin has consistently demonstrated high accuracy in differentiating PMPM from adenocarcinoma. The sensitivity of calretinin for mesothelioma is reported to be as high as 95%, meaning that it correctly identifies 95% of true mesothelioma cases. The specificity of calretinin is also high, around 87%, meaning that it correctly identifies 87% of non-mesothelioma cases. While calretinin is a valuable marker, a panel of IHC markers is often used to increase diagnostic accuracy. The combination of calretinin with other markers, such as cytokeratin 5/6 and WT1, can further improve the diagnostic yield. Imaging studies, such as ultrasound, computed tomography (CT) scans, and magnetic resonance imaging (MRI), play an important

role in the evaluation of patients with suspected PMPM. However, imaging findings alone are not sufficient to definitively diagnose PMPM. Ultrasound can be used as an initial screening tool to assess for ascites, masses, or thickening of the peritoneum. It is a readily available and non-invasive modality. CT scans provide more detailed images of the abdomen and pelvis and can help identify the extent of disease, including the presence of lymphadenopathy or distant metastases. MRI offers excellent soft tissue contrast and can be helpful in characterizing masses and assessing their relationship to surrounding structures. While imaging studies can raise suspicion for PMPM, a definitive diagnosis requires histologic examination and IHC confirmation. Diagnosing and managing PMPM often necessitates a multidisciplinary approach involving a team of healthcare professionals with expertise in various disciplines. Gastroenterologists can evaluate gastrointestinal symptoms, perform endoscopic procedures, and provide expertise in managing ascites. Gynecologists are essential in evaluating women with suspected PMPM, as the clinical presentation can mimic ovarian cancer. Surgeons play a critical role in obtaining tissue biopsies for diagnosis and performing cytoreductive surgery to remove as much tumor as possible. Medical oncologists are responsible for administering systemic chemotherapy and other targeted therapies. Pathologists are crucial for interpreting biopsies and performing IHC studies to confirm the diagnosis of PMPM. Radiologists interpret imaging studies and provide guidance for biopsies and other procedures. This multidisciplinary approach ensures that patients receive comprehensive and coordinated care, optimizing their chances of a favorable outcome.<sup>11-13</sup>

Immunohistochemistry (IHC) plays a pivotal role in the diagnosis of primary malignant peritoneal mesothelioma (PMPM). This technique involves the use of antibodies to detect specific proteins within cells, providing valuable insights into their origin and differentiation. In the case of PMPM, IHC is essential for differentiating it from other malignancies,

particularly adenocarcinomas, which can share similar clinical and histologic features. The diagnosis of PMPM can be challenging due to its rarity, nonspecific clinical presentation, and histologic similarities to other malignancies. IHC helps overcome these challenges by providing a more definitive way to identify PMPM. Adenocarcinomas, cancers that develop from glandular tissue, can occur in many different organs and often metastasize to the peritoneum. These metastatic adenocarcinomas can mimic PMPM in their clinical presentation and histologic appearance. IHC allows for the identification of specific markers that can differentiate between these two entities. IHC markers used in the diagnosis of PMPM have high sensitivity and specificity, meaning they are very accurate in identifying true cases of PMPM and ruling out other conditions. This accuracy is crucial for making the correct diagnosis and guiding appropriate treatment decisions. The accurate diagnosis of PMPM through IHC has significant implications for treatment planning. PMPM and adenocarcinoma require different treatment approaches, and using the wrong treatment can negatively impact patient outcomes. A panel of IHC markers is typically used to diagnose PMPM. These markers target specific proteins found in mesothelial cells, the cells from which PMPM originates. Calretinin, a calcium-binding protein predominantly expressed in mesothelial cells, making it a highly sensitive and specific marker for PMPM. Cytokeratin 5/6, a type of intermediate filament protein found in epithelial tissues, including mesothelium. It can help differentiate PMPM from other carcinomas. WT1, a transcription factor expressed in mesothelial cells and some other tissues. It can be used in conjunction with other markers to support the diagnosis of PMPM. D2-40, a marker of lymphatic endothelium that can also be expressed in PMPM. It can be helpful in differentiating PMPM from adenocarcinoma. MOC-31, an antibody that recognizes an epithelial cell adhesion molecule. It is typically negative in PMPM and positive in adenocarcinoma, making it a useful marker for distinguishing between the two. Calretinin is

considered a key marker in the diagnosis of PMPM due to its high sensitivity and specificity for mesothelial cells. It has been shown to be particularly useful in differentiating epithelioid mesothelioma, the most common subtype of PMPM, from adenocarcinoma. Calretinin staining is typically observed in both the nucleus and cytoplasm of mesothelial cells. This distinct staining pattern helps pathologists identify PMPM with greater confidence. Studies have shown that calretinin has a sensitivity of 95% and a specificity of 87% in differentiating epithelioid mesothelioma from adenocarcinoma. This means that calretinin correctly identifies 95% of true mesothelioma cases and correctly rules out 95% of non-mesothelioma cases. In addition to its role in diagnosis, IHC can also provide information about the prognosis of PMPM. Ki-67 is a marker of cellular proliferation, and its expression can be used to assess the aggressiveness of the tumor. A higher Ki-67 index indicates a more rapidly growing tumor, which may be associated with a poorer prognosis. IHC can help differentiate between the epithelioid and sarcomatoid subtypes of PMPM. The epithelioid subtype generally has a better prognosis than the sarcomatoid subtype.<sup>14,15</sup>

The accurate diagnosis of primary malignant peritoneal mesothelioma (PMPM) has profound therapeutic and prognostic implications. A correct diagnosis guides treatment strategies, facilitates appropriate patient counseling, and informs clinical trial eligibility. Distinguishing PMPM from other peritoneal malignancies, particularly metastatic adenocarcinoma, is crucial because the treatment approaches for these conditions can differ significantly. The mainstay of treatment for PMPM is cytoreductive surgery (CRS) combined with hyperthermic intraperitoneal chemotherapy (HIPEC). CRS involves the removal of all visible tumor deposits within the abdominal cavity, while HIPEC delivers heated chemotherapy directly to the affected area during surgery. This aggressive approach aims to eliminate all macroscopic disease and improve the penetration of chemotherapy into microscopic

deposits. The treatment of metastatic adenocarcinoma often involves systemic chemotherapy, targeted therapy, or immunotherapy, depending on the primary origin of the cancer and its molecular profile. Surgical intervention may be considered in selected cases but is less likely to be curative compared to PMPM. Misdiagnosing PMPM as adenocarcinoma could lead to inappropriate treatment, potentially compromising patient outcomes. For instance, if a patient with PMPM is treated with systemic chemotherapy alone, they may miss the opportunity for potentially curative CRS and HIPEC. Conversely, subjecting a patient with adenocarcinoma to unnecessary CRS and HIPEC could expose them to significant risks without substantial benefits. The prognosis of PMPM is generally poor, but the accurate diagnosis allows for more informed prognostication and personalized patient counseling. The epithelioid subtype of PMPM tends to have a better prognosis compared to the sarcomatoid or biphasic subtypes. This is partly due to its higher likelihood of responding to CRS and HIPEC. The sarcomatoid and biphasic subtypes are generally associated with a less favorable prognosis. They are often more aggressive and less responsive to current therapies. Accurate diagnosis through immunohistochemistry (IHC) helps determine the subtype of PMPM, which in turn informs the prognosis and helps set realistic treatment expectations. A definitive diagnosis of PMPM is often a prerequisite for enrollment in clinical trials. Clinical trials are essential for advancing the understanding and treatment of rare cancers like PMPM. Clinical trials provide access to novel therapies, such as targeted therapies and immunotherapies, that may not be available outside of a research setting. Participation in clinical trials can offer hope for improved outcomes and contribute to the development of more effective treatments for future patients. An accurate diagnosis of PMPM enables healthcare providers to engage in more personalized and meaningful discussions with patients and their families. Understanding the diagnosis and prognosis allows patients to make informed decisions about their

treatment options and end-of-life care. Healthcare providers can offer support and connect patients with resources to help them cope with the emotional and psychological challenges associated with a PMPM diagnosis.<sup>16,17</sup>

The management of primary malignant peritoneal mesothelioma (PMPM) is a complex undertaking that necessitates a multidisciplinary approach to optimize patient outcomes. This involves the seamless collaboration of various healthcare professionals, each contributing their specialized expertise to different facets of PMPM care. This collaborative model ensures that patients receive comprehensive and individualized treatment plans tailored to their specific needs and disease characteristics. Surgeons are at the forefront of the surgical management of PMPM. Their expertise is crucial in performing biopsies for diagnostic purposes and conducting cytoreductive surgery (CRS) with the aim of removing all visible tumor deposits. They also administer hyperthermic intraperitoneal chemotherapy (HIPEC) during the surgical procedure. The surgeon's role extends beyond the operating room, encompassing patient education, pre-operative assessment, and post-operative care. Surgeons experienced in CRS and HIPEC are essential for maximizing tumor removal and minimizing complications. These procedures are technically demanding and require specialized training. Surgeons work closely with medical oncologists, radiation oncologists, and radiologists to determine the best surgical approach and timing of surgery in the context of the overall treatment plan. Medical oncologists are pivotal in the systemic treatment of PMPM. They are responsible for administering chemotherapy, targeted therapy, and immunotherapy, often in conjunction with surgery. They collaborate closely with other team members to develop individualized treatment plans tailored to the patient's specific needs and disease stage. Medical oncologists have in-depth knowledge of various chemotherapy regimens, targeted therapies, and immunotherapies, allowing them to select the most appropriate treatment options for each patient. They closely monitor patients' response to treatment,

adjusting the plan as needed to optimize efficacy and minimize side effects. While not always a primary treatment modality for PMPM, radiation oncologists may be involved in selected cases. Their expertise is sought for palliative treatment of unresectable tumors or for preventing recurrence after surgery. Radiation therapy can be used to relieve symptoms such as pain or bleeding caused by unresectable tumors. In some cases, radiation therapy may be given after surgery to destroy any remaining microscopic cancer cells and reduce the risk of recurrence. Pathologists play an indispensable role in diagnosing PMPM. They meticulously examine tissue biopsies and perform immunohistochemical (IHC) studies to confirm the diagnosis and determine the specific subtype of mesothelioma. Their accurate assessment is crucial for guiding treatment decisions and prognostication. Pathologists are skilled in interpreting IHC staining patterns to differentiate PMPM from other malignancies and determine the subtype of mesothelioma. They may also perform molecular testing on tumor samples to identify genetic mutations that could inform treatment decisions or predict prognosis. Radiologists are integral to the diagnostic and treatment planning process. They interpret imaging studies, such as CT scans and MRIs, to assess the extent of the disease, guide biopsies, and assist in surgical planning. Radiologists utilize advanced imaging techniques, such as PET scans and MRI with contrast, to provide detailed information about the location and extent of the tumor. They may perform image-guided biopsies to obtain tissue samples for diagnosis, ensuring accurate sampling and minimizing complications. Palliative care specialists focus on improving the quality of life for patients with PMPM. They work to manage symptoms, provide emotional support, and coordinate care to ensure the patient's comfort and well-being throughout their treatment journey. Palliative care specialists address a wide range of symptoms, including pain, fatigue, nausea, and shortness of breath. They provide emotional and spiritual support to patients and their families, helping them cope with

the challenges of living with a serious illness. Nurses are at the forefront of direct patient care. They administer medications, monitor vital signs, provide wound care, and educate patients and their families about PMPM and its treatment. Nurses play a vital role in educating patients and their families about PMPM, its treatment, and potential side effects. They provide emotional support and encouragement to patients and their families, helping them navigate the challenges of their illness. Social workers provide invaluable support to patients and their families as they navigate the complexities of living with PMPM. They connect patients with resources and support services, assist with financial concerns, and address psychosocial needs. Social workers help patients access resources such as financial assistance, transportation, and home healthcare services. They provide counseling and support to patients and their families, helping them cope with the emotional and social impact of PMPM. Patients receive comprehensive care that addresses all aspects of their disease, from the initial diagnosis and treatment to ongoing symptom management and psychosocial support. This holistic approach ensures that patients' physical, emotional, and social needs are met throughout their cancer journey. Treatment plans are carefully tailored to each patient's specific needs and disease characteristics. This personalized approach ensures that patients receive the most appropriate and effective care based on their individual circumstances, including their age, overall health, and the stage and subtype of their mesothelioma. Studies have demonstrated that multidisciplinary care can lead to improved outcomes for patients with PMPM. This includes increased survival rates, better quality of life, and reduced treatment-related complications. The collaborative nature of multidisciplinary care allows for more informed decision-making and optimized treatment strategies. A multidisciplinary team fosters open communication and coordination among healthcare professionals. This ensures that everyone involved in the patient's care is working together seamlessly towards the common goal of providing optimal

treatment and support. Regular team meetings and shared medical records facilitate efficient information exchange and coordinated care delivery. Patients who receive multidisciplinary care report higher levels of satisfaction with their care. They feel more involved in their treatment decisions and have greater confidence in the expertise of their healthcare team. This sense of empowerment and trust can positively impact their emotional well-being and overall treatment experience. Tumor boards are a key component of multidisciplinary cancer care. These meetings bring together specialists from various disciplines to discuss complex cases and develop individualized treatment plans. Detailed review of individual patient cases, including their medical history, imaging studies, pathology reports, and treatment response. Collaborative development of personalized treatment plans, considering the patient's specific needs and disease characteristics. Input from multiple specialists, ensuring that patients benefit from a wide range of expertise and perspectives. Discussion of potential clinical trial options for eligible patients, providing access to novel therapies and research opportunities. Coordinating the schedules and communication of multiple healthcare professionals can be logistically complex. Multidisciplinary care may require additional resources, such as dedicated clinic space and administrative support. Differences in communication styles and medical jargon can sometimes hinder effective communication among team members. Despite these challenges, the benefits of multidisciplinary care for PMPM far outweigh the drawbacks. Healthcare institutions should strive to overcome these challenges and prioritize the implementation of multidisciplinary teams to optimize patient outcomes.<sup>18-20</sup>

#### **4. Conclusion**

This case underscores the challenges in diagnosing PMPM and highlights the critical role of immunohistochemistry in differentiating it from metastatic adenocarcinoma. Accurate diagnosis is essential for determining appropriate management



strategies and providing prognostic information. The patient's clinical presentation, mimicking ovarian carcinoma, emphasizes the importance of considering PMPM in the differential diagnosis of women with abdominal distension, ascites, and adnexal masses. The initial suspicion of ovarian carcinoma, based on imaging and clinical findings, underscores the limitations of relying solely on these modalities for definitive diagnosis. The histopathological examination of the omental tissue, revealing a proliferation of epithelial cells with papillary and glandular-like growth patterns, further complicated the diagnostic process. The moderate nuclear pleomorphism observed in these cells raised the possibility of either mesothelioma or adenocarcinoma, highlighting the need for ancillary diagnostic techniques. Immunohistochemical staining played a crucial role in resolving this diagnostic dilemma. The strong positivity for calretinin, a mesothelial marker, confirmed the mesothelial origin of the tumor. The absence of ER and PR expression effectively ruled out an ovarian or endometrial origin. This case reinforces the importance of a multidisciplinary approach in the management of PMPM. The collaboration of surgeons, medical oncologists, pathologists, and radiologists ensured accurate diagnosis, appropriate treatment selection, and comprehensive patient care.

## 5. References

1. Teng F, Huang D, Wang X, Cui H. Malignant peritoneal mesothelioma with liver metastasis: a case report and literature review. *Asian J Surg.* 2024; 47(10): 4589–91.
2. Lief S, Patibandla S, Ansari AZ, Bhatt N, Gulraiz A, Beauti SM, et al. Ascites as a rare manifestation of malignant peritoneal mesothelioma: a case report. *Cureus.* 2024; 16(10): e70982.
3. Fujiwara S, Kano Y, Maejima Y, Fujioka T, Tamura K, Kirimura S, et al. Clinical response of primary malignant pericardial mesothelioma with peritoneal dissemination to nivolumab. *Intern Med.* 2024; 63(4): 513–9.
4. Luo J, Pan J, Zhong C, Wang L, Zhang H. Malignant peritoneal mesothelioma presenting with bilateral hydronephrosis and renal insufficiency: a case report and literature review. *Front Surg.* 2024; 11: 1342657.
5. Potesta MA Jr, Guld E, Laman J. Dual malignancies discovered: a rare case of malignant peritoneal epithelioid mesothelioma and lung adenocarcinoma. *Cureus.* 2024; 16(5): e59962.
6. Altshuler PC, Newman AL, Garibay JA. Rapid progression of malignant peritoneal mesothelioma mimicking a postoperative complication in a young woman: a case report. *Am J Case Rep.* 2024; 25: e942948.
7. Wang L, Wang X, Sun N, Liu W. High mobility group box 1 mediates inflammatory responses in malignant peritoneal mesothelioma. *Int Immunopharmacol.* 2024; 133(112039): 112039.
8. Strauss GZ, Gondra H, Schwartz I, Appel S, Weitzen R, Berger Y, et al. Immune checkpoint inhibitors in advanced malignant peritoneal mesothelioma: Clinical insights, immunopathologic profiling, and prognostic implications from a single-center study. *J Clin Oncol.* 2024; 42(Suppl\_16): e14665–e14665.
9. Khan S, Malik A, Qureshi S, Cohen B, Nadir A. Incidental diagnosis of malignant peritoneal mesothelioma during liver transplantation surgery: a case report. *Am J Case Rep.* 2024; 25: e943787.
10. Strauss GZ, Gondra H, Schwartz I, Appel S, Weitzen R, Berger Y, et al. Immune checkpoint inhibitors in advanced malignant peritoneal mesothelioma: Clinical insights, immunopathologic profiling, and prognostic implications from a single-center study. *J Clin Oncol.* 2024; 42(Suppl\_16): e14665–e14665.
11. Khan S, Malik A, Qureshi S, Cohen B, Nadir A. Incidental diagnosis of malignant peritoneal mesothelioma during liver

- transplantation surgery: a case report. *Am J Case Rep.* 2024; 25: e943787.
12. Mollaoğlu MC, Karabacak U, Bostancı ME, Seven TE, Karadayı K. Is extreme cytoreductive surgery beneficial to survival in malignant peritoneal mesothelioma? *Acta Chir Belg.* 2024; 124(4): 281–9.
  13. Ma X, Lembersky D, Kim ES, Becich MJ, Testa JR, Bruno TC, et al. Spatial landscape of malignant pleural and peritoneal mesothelioma tumor immune microenvironments. *Cancer Res Commun.* 2024; 4(8): 2133–46.
  14. Ma X, Lembersky D, Kim ES, Becich MJ, Testa JR, Bruno TC, et al. Data from spatial landscape of malignant pleural and peritoneal mesothelioma tumor immune microenvironments. *Am Assoc Cancer Res.* 2024.
  15. Li Y, Yang J, Zheng B, Yan N, Yang W, Xie X, et al. Case report: ATM A1159T mutation in malignant peritoneal mesothelioma may be associated with tumor recurrence. *SAGE Open Med Case Rep.* 2024; 12: 2050313X241271818.
  16. Su Y-D, Ma R, Fu Y-B, Wu H-L, Liang X-L, Liu Y-T, et al. Drug sensitivity tumor cell clusters in malignant peritoneal mesothelioma. *J Surg Oncol.* 2024.
  17. Yaşar S, Yılmaz F, Utkan G, Algın E, Bayram D, Tamam S, et al. Analysis of treatment strategies and outcomes in malignant peritoneal mesothelioma: Insights from a multi-center study. *Ann Surg Oncol.* 2024; 31(9): 6228–36.
  18. Liang X-L, Li X-B, Fu Y-B, Su Y-D, Ma R, Yang R, et al. Research progress of malignant peritoneal mesothelioma with paraneoplastic syndrome: a review. *J Surg Oncol.* 2024; 130(3): 533–42.
  19. Yaşar S. ASO author reflections: Analysis of treatment strategies and outcomes in malignant peritoneal mesothelioma: Insights from a multi-center study. *Ann Surg Oncol.* 2024; 31(9): 6276–7.
  20. Drigotas C, Loftus AW, Ammori JB, Rothermel LD, Hoehn RS. Perfusion strategies for cytoreductive surgery with heated intraperitoneal chemotherapy for malignant peritoneal mesothelioma. *J Surg Oncol.* 2024.