



Bioscientia Medicina: Journal of Biomedicine & Translational Research

Journal Homepage: www.bioscmed.com

A Multidisciplinary Approach to Managing Multiple Tuberous Xanthomas in a Pediatric Patient with Familial Hypercholesterolemia Type II: A Rare Case

Clarissa Maharani Putri^{1*}, Rina Gustia¹, Ennesta Asri¹, Mutia Sari¹, Indah Indria Sari¹

¹Department of Dermatology, Venereology and Aesthetics, Faculty of Medicine, Universitas Andalas/Dr. M. Djamil General Hospital, Padang, Indonesia

ARTICLE INFO

Keywords:

Familial hypercholesterolemia
Multidisciplinary approach
Pediatric
Surgical excision
Tuberous xanthoma

*Corresponding author:

Clarissa Maharani Putri

E-mail address:

2150308203.clarissa@student.unand.ac.id

All authors have reviewed and approved the final version of the manuscript.

<https://doi.org/10.37275/bsm.v9i3.1214>

ABSTRACT

Background: Familial hypercholesterolemia (FH) is a rare inherited disorder characterized by high cholesterol levels, primarily high levels of low-density lipoprotein cholesterol (LDL-C). This condition can lead to premature cardiovascular disease. A less recognized but significant manifestation of FH is the development of multiple tuberous xanthomas, which are exogenous masses or fatty deposits on the skin. **Case presentation:** This report describes the case of a 4-year-old female child who presented to the Dermatology, Venereology, and Aesthetics Department of Dr. M. Djamil General Hospital Padang with multiple yellowish, painless, and non-itchy lumps on her body. These lumps were located on her knuckles, hands, elbows, buttocks, knees, back of knees, ankles, and feet. The lumps had been progressively increasing in size over the past month. Her medical history revealed that she first developed a yellowish lump on her right ankle two years prior, which gradually spread to other areas of her body. A dermoscopic examination showed a yellow-brown structureless area, and laboratory tests confirmed hypercholesterolemia with elevated LDL levels. Her triglycerides were normal, and both of her parents also had hypercholesterolemia. A histopathology examination confirmed the diagnosis of xanthoma. The patient was diagnosed with tuberous xanthomas and treated with simvastatin 1x10 mg, along with surgical excision of the xanthomas and flap reconstruction under general anesthesia. **Conclusion:** This case highlights the importance of a multidisciplinary approach in managing multiple tuberous xanthomas in a child with FH. While surgical excision can effectively remove the lesions, ongoing lipid-lowering therapy is crucial to prevent recurrence and reduce cardiovascular risks associated with FH. Collaboration among dermatologists, pediatric cardiologists, and pediatric nutritionists is vital to ensure comprehensive care and enhance the patient's overall quality of life.

1. Introduction

Xanthomas are localized lipid deposits in the skin or tendons, resulting from abnormal lipid metabolism. They manifest as yellowish papules, nodules, or plaques, often clustered around joints or tendons. These deposits are not merely cosmetic concerns; they serve as visible indicators of underlying lipid disorders, often hyperlipidemia, and the associated increased risk of cardiovascular disease. Familial hypercholesterolemia (FH) is a common cause of hyperlipidemia. It is an autosomal dominant genetic

disorder characterized by high levels of total cholesterol and low-density lipoprotein cholesterol (LDL-C). The prevalence of the heterozygous form of FH (HeFH) is 1 in 250 individuals, while the homozygous form (HoFH) is much rarer, affecting approximately 1 in 1 million individuals.¹⁻⁴

Elevated LDL-C levels play a pivotal role in the pathogenesis of xanthomas. LDL-C particles accumulate in the extracellular matrix of the skin and tendons, triggering an inflammatory response. This response attracts macrophages, which engulf the

lipids, transforming into foam cells. These foam cells aggregate, forming the characteristic xanthoma lesions. Tuberous xanthomas are typically found on the extensor surfaces of joints, such as the elbows, knees, and buttocks. They are characterized by firm, yellow or skin-colored nodules, ranging in size from a few millimeters to several centimeters. These lesions can be solitary or multiple and may coalesce to form larger plaques.⁵⁻⁷

In children, the presence of multiple tuberous xanthomas is particularly concerning, as it signifies a high risk of premature cardiovascular disease. Early diagnosis and intervention are crucial to mitigate this risk and improve the patient's quality of life.⁸⁻¹⁰ This case report presents a 4-year-old female child with multiple tuberous xanthomas associated with FH.

2. Case Presentation

This case report details the presentation and management of a 4-year-old female child who presented to the Dermatology, Venereology, and Aesthetics Department of Dr. M. Djamil General Hospital Padang with multiple yellowish lumps on her body. The patient's mother reported that the lumps, which were neither painful nor itchy, first appeared on the child's right ankle two years prior. Over the past month, these lesions had progressively increased in size and number, spreading to the knuckles, hands, elbows, buttocks, knees, back of knees, ankles, and feet. The child had no history of pain, itching, or any other symptoms associated with the lesions. Furthermore, there was no family history of similar skin conditions or known genetic disorders, including hypercholesterolemia or cardiovascular disease. The child's dietary habits were typical for her age, consisting of three meals a day with rice and side dishes, including fried foods and vegetables, and packaged snacks or candy once a day. A comprehensive review of systems was negative for fatigue, syncope, chest pain, shortness of breath, palpitations, cold intolerance, weight gain, constipation, fatigue, dry skin, bedwetting, excessive thirst, frequent hunger, weight loss, genital itching,

jaundice, cloudy urination, whitish stool, decreased urination, foamy stool, decreased appetite, and swelling of the eyes, face, abdomen, or legs. The child had no history of alcohol consumption, long-term medication use, skin malignancy, keloids, diabetes mellitus, or easy bleeding. She was born from a non-consanguineous marriage with an uneventful prenatal, natal, and postnatal history. Upon physical examination, multiple skin-colored to yellowish papules, nodules, and tumors were observed on the patient's knuckles, hands, elbows, buttocks, knees, back of knees, ankles, and feet. These lesions were non-tender, non-fluctuant, and firm on palpation. The smallest lesion measured 0.4 x 0.5 x 0.2 cm, while the largest measured 4.0 x 4.0 x 0.5 cm. The patient had Fitzpatrick skin phototype IV. Her general appearance indicated mild illness. Vital signs were within normal limits: blood pressure 120/70 mmHg, pulse rate 86 bpm, respiratory rate 20 breaths per minute, and temperature 36.7°C. She had good nutrition and normal stature. Examination of the eyes, ears, nose, and throat were all unremarkable. A cardiovascular examination revealed a regular heart rate with no murmurs. Respiratory examination showed normal breath sounds with no wheezes or rales. Abdominal examination revealed no hepatosplenomegaly or distension. Extremities showed good perfusion, warm acral, and no axillary hair. No lymph node enlargement was detected. A dermoscopic examination of the lesions revealed a characteristic yellow-brown structureless area. This finding, while not specific, is consistent with the clinical suspicion of xanthomas. Laboratory investigations revealed significant hypercholesterolemia, with an elevated LDL cholesterol level of 1098 mg/dL. This finding was particularly alarming given the patient's young age. Triglyceride levels were within the normal range at 157 mg/dL, while HDL cholesterol levels were low at 32 mg/dL. Further investigation revealed that both parents also had hypercholesterolemia, with the father's total cholesterol at 320 mg/dL and the mother's at 293 mg/dL. This family history of hypercholesterolemia further supported the diagnosis

of familial hypercholesterolemia in the child. Other laboratory tests, including a complete blood count, liver function tests, kidney function tests, and blood glucose levels, were all within normal limits. A chest X-ray was also performed and showed no abnormalities. A skin biopsy was taken from one of the lesions and sent for histopathological examination. The biopsy revealed clusters of "foamy macrophages," lymphocytes, and plasma cells in the dermis and subcutaneous fat. These foamy macrophages are characteristic of xanthoma lesions and represent lipid-laden macrophages. Hyperemic skin appendages and capillaries were also observed. The overall microscopic picture was consistent with the diagnosis of xanthoma. Based on the clinical presentation, dermoscopic findings, laboratory investigations, and histopathological examination, a diagnosis of tuberous xanthomas with familial hypercholesterolemia type II was made. The presence of multiple tuberous xanthomas at such a young age, coupled with the significantly elevated LDL cholesterol levels and family history of hypercholesterolemia, strongly suggested the diagnosis of familial hypercholesterolemia type II, which is characterized by defects in the LDL receptor gene (Table 1).

The patient was started on simvastatin at a dose of 10 mg daily to lower her cholesterol levels. Simvastatin is a hydroxymethylglutaryl-coenzyme A (HMG-CoA) reductase inhibitor, commonly known as a statin. Statins work by inhibiting the enzyme HMG-CoA reductase, which is responsible for a key step in cholesterol synthesis. This leads to a reduction in the production of cholesterol in the liver, thereby lowering LDL-C levels in the blood. In addition to pharmacological treatment, lifestyle modifications were emphasized. These included dietary changes with a focus on reducing saturated fat intake and increasing the consumption of vegetables and fish. Fried foods were limited. Regular exercise was also encouraged to promote overall health and wellbeing. Following the surgical procedure, the patient was prescribed cefixime, a cephalosporin antibiotic, at a dose of 75 mg twice daily for 7 days to prevent

infection. Paracetamol was also prescribed at a dose of 180 mg three times a day for 7 days for pain management. Topical fusidic acid ointment 2% was applied to the surgical wounds pre-operatively, post-operatively, and during wound dressing changes. Fusidic acid is a topical antibiotic that is effective against a range of bacteria commonly involved in skin infections. The patient was advised to consume a high carbohydrate and protein diet, including foods like boiled egg whites and snakehead fish extract, to promote wound healing. Furthermore, the importance of regular follow-up with a pediatric nutritionist and pediatric cardiologist was emphasized. This multidisciplinary approach aimed to ensure continuous monitoring of cholesterol levels, assess cardiovascular risk, and provide comprehensive care. Surgical intervention was deemed necessary to address the multiple xanthomas. The procedure was performed under general anesthesia. Various excision techniques were employed depending on the location and size of the lesions. Elliptical excisions were performed on the knee, ankle, and feet lesions. Punch excisions were used for the lesions on the hands. Primary closure was achieved for the wounds on both hands, knees, both ankles, and the right foot. For the left foot lesion, a keystone flap modified type C was used. This type of flap involves creating a rectangular flap of skin with a triangular extension at one end, which is then rotated to cover the defect. This technique is particularly useful for closing larger wounds and minimizing tension on the wound edges. Simple interrupted sutures and horizontal mattress sutures with 5-0 T-lene were used for wound closure. These suturing techniques provide secure closure and minimize scarring. All post-hectic wounds were treated with 0.1% gentamicin ointment, covered with gauze, and bandaged. Gentamicin is a broad-spectrum topical antibiotic that helps prevent infection. Before the surgery, the patient and her family were thoroughly counseled about the procedure and potential complications. This included a discussion about the risks of infection, necrosis, scarring (including keloids and hypertrophic scars),

and injury to nerves and blood vessels during surgery. They were also instructed on proper wound care, emphasizing the importance of keeping the bandages clean, dry, and undisturbed. Close post-operative monitoring was crucial to ensure proper wound healing and assess the patient's overall progress. On day 8 post-surgery, the patient reported mild pain in the surgical area. There was some swelling but no signs of massive bleeding, infection, or necrosis. There was no fever or discharge from the dressings. The stitches were not yet ready for removal. Minimal erythema and edema were observed, but there was no pus. The flap remained intact. The lipid profile showed total cholesterol at 849 mg/dL, HDL cholesterol at 28 mg/dL, LDL cholesterol at 805 mg/dL, and triglycerides at 80 mg/dL. On day 14 post-surgery, the patient continued to report mild pain, but the swelling had subsided. There were no signs of bleeding, infection, or necrosis, and no fever or discharge. The

stitches were still not ready for removal. Minimal erythema was present, but there was no edema or pus. The flap remained intact. The patient was seen every 3 days for wound dressing changes and assessment. All wounds were healing well. Lipid levels were monitored regularly to evaluate the effectiveness of the medical treatment and guide any necessary adjustments. The patient was advised to continue long-term medication and attend regular follow-up appointments for wound checks and lipid monitoring. The importance of adherence to the prescribed medication and lifestyle modifications was reinforced. After the initial intensive follow-up period, the patient was advised to continue with regular check-ups with the pediatric nutritionist and pediatric cardiologist for ongoing management of her familial hypercholesterolemia and cardiovascular risk assessment (Table 2).

Table 1. Anamnesis, physical examination, dermoscopic examination, laboratory, histopathological examination, and diagnosis.

Category	Observation
Anamnesis	4-year-old female child- Yellowish lumps that are not painful or itchy on knuckles, hands, elbows, buttocks, knees, back of knees, ankles, and feet. - The lumps have been progressively increasing in size over the past month. - The patient first developed a yellowish lump on her right ankle two years prior, which gradually spread to other areas. - No history of pain, itching, or any other associated symptoms. - No family history of similar skin lesions or any known genetic disorders. - No family history of high cholesterol or cardiovascular disease. - Dietary habits: Eats 3 times a day with rice and side dishes, including fried foods and vegetables. Eats packaged snacks or candy once a day. - Denies fatigue, syncope, chest pain, shortness of breath, and palpitations. - Denies cold intolerance, weight gain, constipation, fatigue, and dry skin. - Denies bedwetting, excessive thirst, frequent hunger, weight loss, and genital itching. - Denies jaundice, cloudy urination, whitish stool. - Denies decreased urination, foamy stool, decreased appetite, and swelling of the eyes, face, abdomen, and legs. - Denies consuming alcohol. - Denies the use of long-term medication. - Denies history of skin malignancy or keloids. - Denies history of diabetes mellitus or easy bleeding. - Born from a non-consanguineous marriage with an uneventful prenatal, natal, and postnatal history.
Physical Examination	- Multiple skin-colored to yellowish papules, nodules, and tumors on the patient's knuckles, hands, elbows, buttocks, knees, back of knees, ankles, and feet. - Lesions are non-tender, non-fluctuant, and firm on palpation. - The smallest lesion measures 0.4 x 0.5 x 0.2 cm, and the largest lesion measures 4.0 x 4.0 x 0.5 cm (Figure 1). - Fitzpatrick skin phototype IV. - General appearance: Mild illness. - Vital signs: Blood pressure 120/70 mmHg, pulse rate 86 bpm, respiratory rate 20 breaths per minute, temperature 36.7°C. - Nutritional state: Good nutrition with normal stature. - Eyes: Conjunctiva and sclera are normal. - Ear, nose, and throat (ENT): Within normal limits. - Cardiovascular system: Regular heart rate, no murmurs. - Respiratory system: Normal breath sounds, no wheezes or rales. - Abdomen: No hepatosplenomegaly, no distension. - Extremities: Good perfusion, warm acral, no axillary hair. - Lymph nodes: No enlargement.
Dermoscopic Examination	Yellow-brown structureless area (Figure 2).
Laboratory Investigations	- Hypercholesterolemia with elevated LDL cholesterol levels (1098 mg/dL). - Normal triglyceride levels (157 mg/dL). - Low HDL cholesterol levels (32 mg/dL). - Both parents have hypercholesterolemia (father's total cholesterol: 320 mg/dL, mother's total cholesterol: 293 mg/dL). - Complete blood count, liver function tests, kidney function tests, and blood glucose levels are all within normal limits. - Chest X-ray: Within normal limits.
Histopathological Examination	- Skin biopsy shows clusters of "foamy macrophages," lymphocytes, and plasma cells in the dermis and subcutaneous fat. - Hyperemic skin appendages and capillaries are also observed. - The microscopic picture is consistent with xanthoma (Figure 4).
Diagnosis	Tuberous xanthomas with familial hypercholesterolemia type II.

Table 2. Medical treatment, surgical treatment, and follow-up.

Category	Observation
Medical treatment	- Simvastatin 1x10 mg daily to lower cholesterol levels. - Lifestyle modifications, including dietary changes (low in saturated fat and greater intake of vegetables and fish, reducing fried foods) and regular exercise. - Cefixime 2 x 75 mg po after the procedure for 7 days. - Paracetamol 3 x 180 mg po after the procedure for 7 days. - Fusidic acid ointment 2% is applied pre-operation, postoperatively, and during wound dressing. - Advise patient to consume a high carbohydrate and protein diet (boiled egg white and snakehead fish extract) for speed wound healing. - Advise patient to do routine checks with a pediatric nutritionist and pediatric cardiologist for regular cholesterol checks and cardiovascular risk screening.
Surgical treatment	- Excision surgery + flap reconstruction under general anesthesia. - Elliptical excision and punch excision on hand lesions. - Elliptical excision on knee, ankle, and foot lesions. - Primary closure for both hands, knees, ankles and right foot. - Keystone flap modified type C for the left foot lesion. - Simple interrupted suture technique and horizontal mattress sutures with T-lene 5-0. - All post-hectic wounds are treated with 0.1% gentamicin ointment, covered with gauze, and bandaged. - Explain to the patient and her family about the risk of infection, necrosis, and scars on wounds such as keloids and hypertrophic scars and injury to nerves and blood vessels during surgery. - Explain to the patient that the bandage should not be wet, or dirty, and should not be opened by the patient (Figure 3).
Follow up	- Day-8 Post Surgery: Pain in the surgical area was mild. There was swelling of the post-operative area without massive bleeding, infection, or necrosis. No fever and no discharge leak from dressing. The stitches had been not completely removed, erythema (+) minimal, edema (+), pus (-), flap intact. Total cholesterol 849 mg/dL, HDL cholesterol 28 mg/dL, LDL cholesterol 805 mg/dL, Triglyceride 80 mg/dL. - Day-14 Post Surgery: Pain in the surgical area was mild. There was no swelling of the post-operative area without massive bleeding, infection, and necrosis. No fever and no discharge leak from the dressing. The stitches had not been completely removed, erythema (+) minimal, edema (+), pus (-), and flap intact. - Every 3 days showed all wounds were healing well. - Lipid levels were monitored. - Surgical wounds were checked for healing. - Advised to continue long-term medication and evaluate the therapeutic response by monitoring lipid levels. - After surgery, the patient needs to come regularly for wound dressing twice weekly.

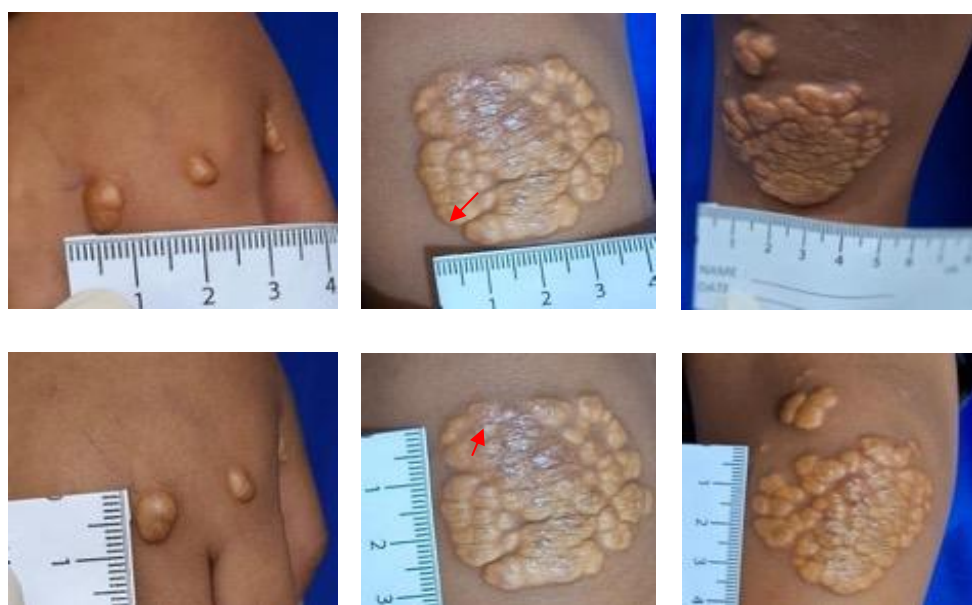


Figure 1. Skin-colored-to-yellowish papules, nodules, and tumours of varying sizes: the smallest one measuring 0,4 x 0,5 x 0,2 cm, and the largest one measuring 4,0 x 4,0 x 0,5 cm on knuckles, hands, elbow, buttock, knee, back of the knee, ankle and both of feet.

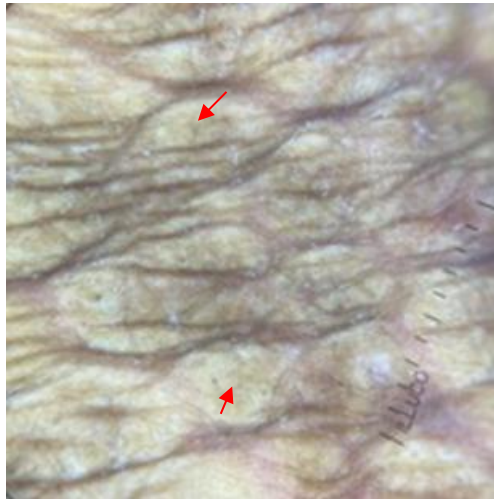


Figure 2. A dermoscopy examination showed a yellow-brown structureless area (red arrow).

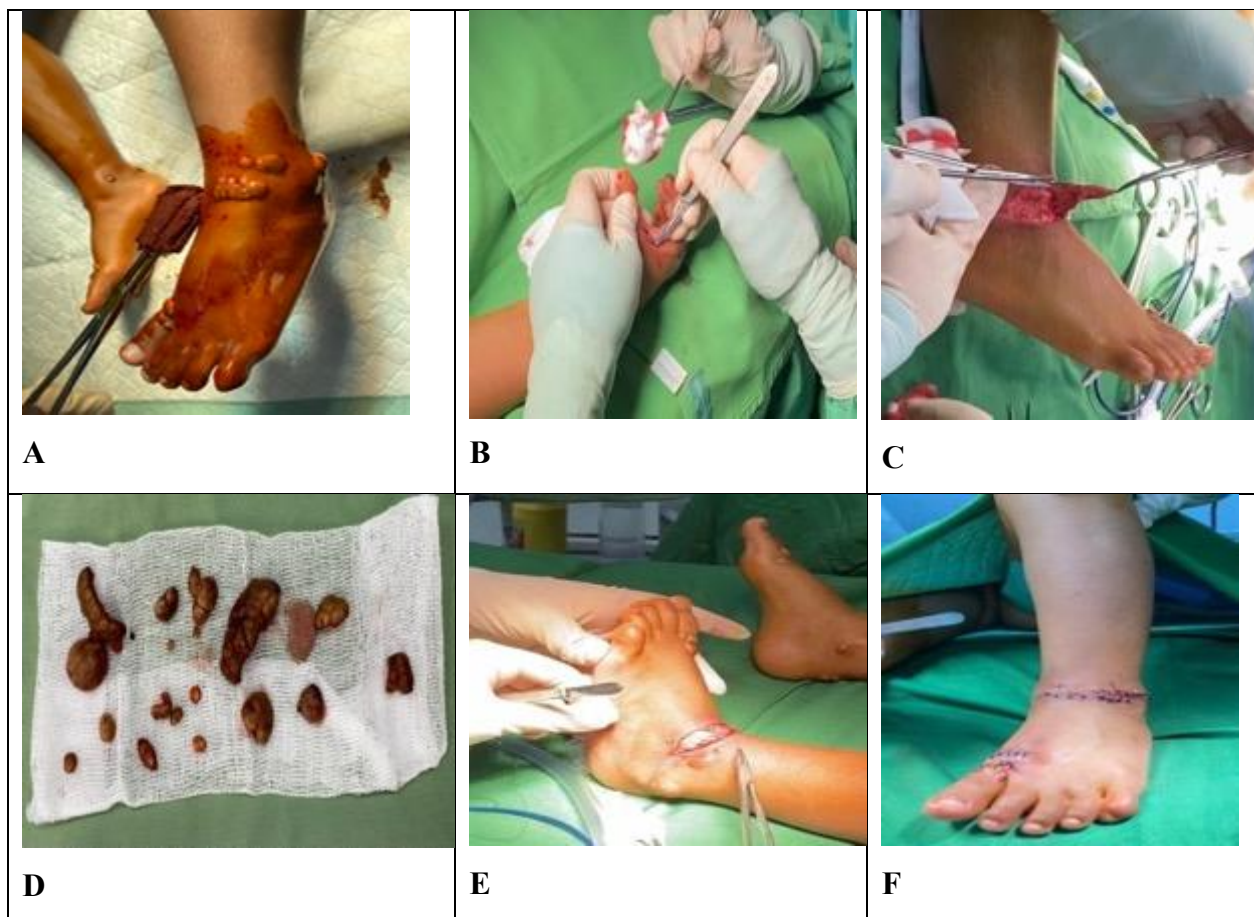

Figure 3. Surgical Procedure for Removal of Tumors and Closure of Defects. A. Asepsis technique. B. Excision of lesion. C. Undermining lesion. D. Tumors have been removed. E. left foot was repaired with Keystone flap modified type C. F. The wound was completely sutured.

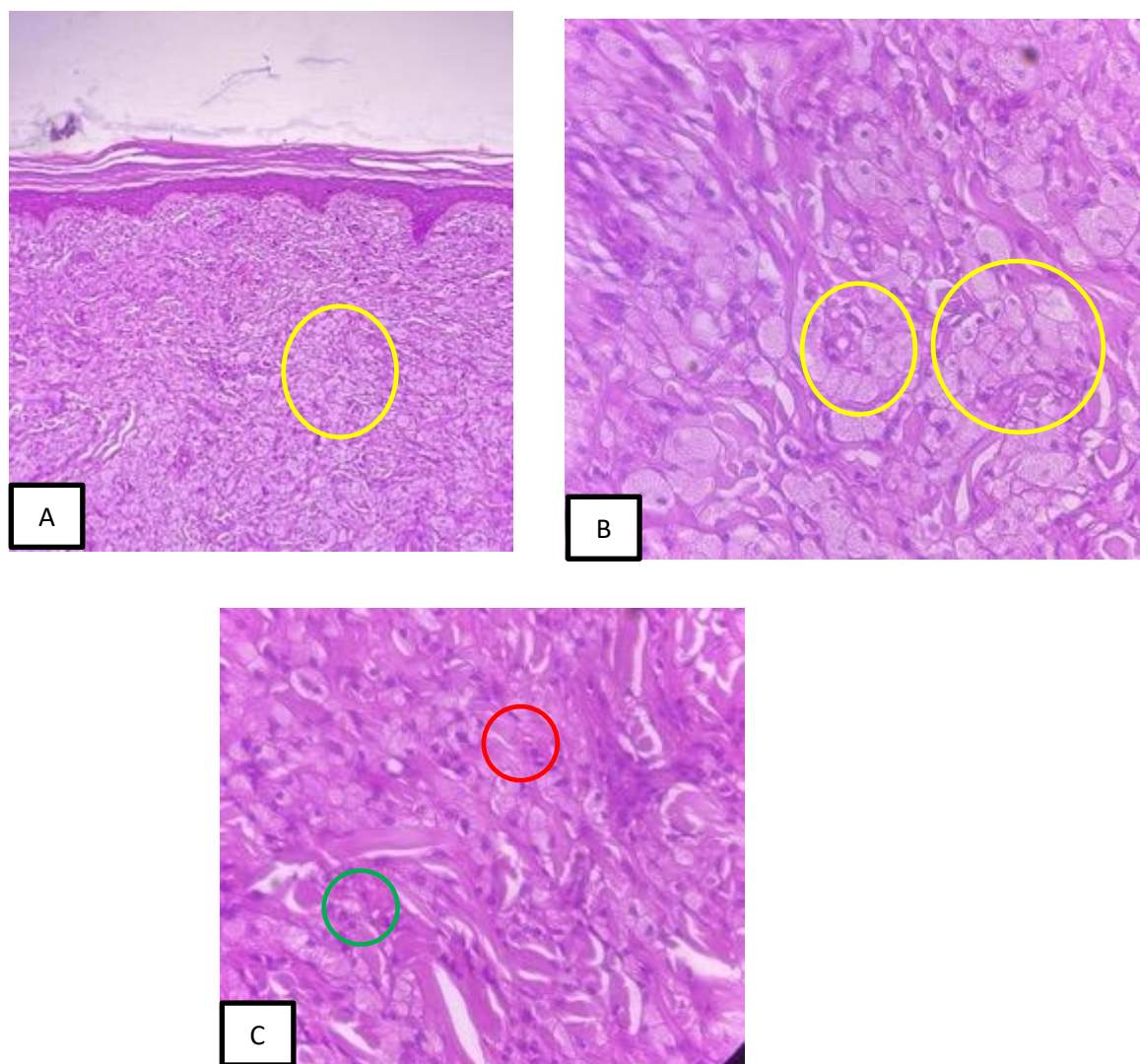


Figure 4. A. Magnification 100x. B.C. Magnification 400x. The histopathological features found "foamy macrophages"(yellow circle), clusters and clusters of lymphocytes (green circle), and plasma cells (red circle), in the subcutaneous layer (fat tissue).

3. Discussion

This case presents a 4-year-old female child with multiple tuberous xanthomas, a visible cutaneous manifestation of Familial Hypercholesterolemia (FH). The child's initial presentation involved multiple, progressively enlarging, yellowish lumps across her body, highlighting the insidious nature of xanthoma development. These lesions, characteristically painless and non-itchy, often lead to delayed diagnosis due to their asymptomatic nature. Detailed medical history included the child's past medical history, family history, and a thorough review of systems. The child's mother reported the initial appearance of the

lumps on the child's right ankle two years prior, with a recent increase in their size and number. The mother denied any family history of similar skin conditions or known genetic disorders, including hypercholesterolemia or cardiovascular disease. A comprehensive review of systems was negative for any symptoms suggestive of underlying systemic conditions. A detailed physical examination was performed, noting the location, size, and characteristics of the skin lesions. Multiple skin-colored to yellowish papules, nodules, and tumors were observed on the patient's knuckles, hands, elbows, buttocks, knees, back of knees, ankles, and

feet. These lesions were non-tender, non-fluctuant, and firm on palpation. The smallest lesion measured 0.4 x 0.5 x 0.2 cm, while the largest measured 4.0 x 4.0 x 0.5 cm. The patient's vital signs were within normal limits, and a systemic examination revealed no other significant findings. Dermoscopy, a non-invasive technique used to visualize skin lesions, was performed. The examination revealed a characteristic yellow-brown structureless area, consistent with the clinical suspicion of xanthomas. Laboratory tests played a crucial role in confirming the diagnosis. The investigations revealed significant hypercholesterolemia, with an elevated LDL cholesterol level of 1098 mg/dL. This finding was particularly alarming given the patient's young age. Triglyceride levels were within the normal range, while HDL cholesterol levels were low. Further investigation revealed that both parents also had hypercholesterolemia, supporting the diagnosis of familial hypercholesterolemia in the child. Other laboratory tests, including a complete blood count, liver function tests, kidney function tests, and blood glucose levels, were all within normal limits. A chest X-ray was also performed and showed no abnormalities. A skin biopsy was taken from one of the lesions for histopathological analysis. The biopsy revealed clusters of "foamy macrophages," lymphocytes, and plasma cells in the dermis and subcutaneous fat. These foamy macrophages, representing lipid-laden macrophages, are characteristic of xanthoma lesions. Hyperemic skin appendages and capillaries were also observed. The overall microscopic picture was consistent with the diagnosis of xanthoma. Based on the collective findings from these diagnostic modalities, a diagnosis of tuberous xanthomas with familial hypercholesterolemia type II was made. The presence of multiple tuberous xanthomas at such a young age, coupled with the significantly elevated LDL cholesterol levels and family history of hypercholesterolemia, strongly suggested the diagnosis of familial hypercholesterolemia type II, which is characterized by defects in the LDL receptor gene. Tuberous

xanthomas are a type of xanthoma that typically present as firm, yellow or skin-colored nodules, ranging in size from a few millimeters to several centimeters. They are commonly found on the extensor surfaces of joints, such as the elbows, knees, and buttocks. In this case, the child presented with multiple tuberous xanthomas on various locations including knuckles, hands, elbows, buttocks, knees, back of knees, ankles, and feet. Familial hypercholesterolemia (FH) is an autosomal dominant genetic disorder characterized by high levels of total cholesterol and low-density lipoprotein cholesterol (LDL-C). The prevalence of the heterozygous form of FH (HeFH) is 1 in 250 individuals, while the homozygous form (HoFH) is much rarer, affecting approximately 1 in 1 million individuals. Elevated LDL-C levels play a pivotal role in the pathogenesis of xanthomas. LDL-C particles accumulate in the extracellular matrix of the skin and tendons, triggering an inflammatory response. This response attracts macrophages, which engulf the lipids, transforming into foam cells. These foam cells aggregate, forming the characteristic xanthoma lesions. In this case, the child presented with multiple tuberous xanthomas at a young age, which is concerning as it signifies a high risk of premature cardiovascular disease. Early diagnosis and intervention are crucial to mitigate this risk and improve the patient's quality of life. The diagnostic process in this case involved a comprehensive evaluation, including a detailed medical history, physical examination, dermoscopic examination, laboratory investigations, and histopathological examination. The convergence of findings from these various diagnostic modalities allowed for a definitive diagnosis and paved the way for appropriate management strategies to address both the cutaneous manifestations and the underlying lipid disorder.¹¹⁻¹³

The management of multiple tuberous xanthomas in a child with FH requires a multidisciplinary approach, involving dermatologists, pediatric cardiologists, and pediatric nutritionists. The primary goals of treatment are to reduce the size and number

of xanthomas, prevent their recurrence, and mitigate the cardiovascular risks associated with FH. This involves a combination of surgical intervention to address the existing lesions and medical management to target the underlying hypercholesterolemia. Surgical excision of the xanthomas was performed in this case to address the lesions and improve the patient's quality of life. The decision to pursue surgical intervention was based on several factors, including the size and location of the lesions, the patient's age, and the potential impact of the lesions on her physical and psychological well-being. Prior to the surgical procedure, a thorough pre-operative evaluation was conducted to assess the patient's overall health and suitability for surgery. This included a review of her medical history, a physical examination, and laboratory tests to ensure that she was in optimal condition for the procedure. The surgical procedure was performed under general anesthesia to ensure the patient's comfort and safety throughout the operation. The anesthesia team carefully monitored the patient's vital signs and maintained adequate anesthesia throughout the procedure. Various excision techniques were employed, tailored to the specific characteristics of each lesion. Elliptical excisions were performed on the larger lesions located on the knee, ankle, and feet. This technique involves removing the lesion along with an elliptical-shaped portion of the surrounding skin, allowing for complete removal of the xanthoma and facilitating primary closure of the wound. Punch excisions were used for the smaller lesions on the hands. This technique involves using a circular punch biopsy tool to remove the lesion, leaving a small, circular wound that can heal by secondary intention or be closed with sutures. Primary closure was achieved for the wounds on both hands, knees, both ankles, and the right foot. This involves bringing the edges of the wound together and securing them with sutures, promoting optimal healing and minimizing scarring. For the left foot lesion, which was larger and more complex, a keystone flap modified type C was used. This type of flap involves creating a rectangular flap of skin with a triangular extension at

one end, which is then rotated to cover the defect. This technique is particularly useful for closing larger wounds and minimizing tension on the wound edges, promoting optimal healing and reducing the risk of complications. Simple interrupted sutures and horizontal mattress sutures with 5-0 T-lene were used for wound closure. These suturing techniques provide secure closure and minimize scarring. The choice of suture material and technique depends on the location and size of the wound, as well as the surgeon's preference. All post-operative wounds were treated with 0.1% gentamicin ointment, covered with gauze, and bandaged. Gentamicin is a broad-spectrum topical antibiotic that helps prevent infection. Proper wound care is essential to promote healing and prevent complications such as infection or dehiscence. Before the surgery, the patient and her family were thoroughly counseled about the procedure and potential complications. This included a discussion about the risks of infection, necrosis, scarring (including keloids and hypertrophic scars), and injury to nerves and blood vessels during surgery. They were also instructed on proper wound care, emphasizing the importance of keeping the bandages clean, dry, and undisturbed. Patient education and counseling are crucial to ensure informed consent and promote adherence to post-operative instructions. In addition to surgical intervention, medical treatment was necessary to address the underlying hypercholesterolemia and prevent recurrence of xanthomas. The patient was started on simvastatin at a dose of 10 mg daily to lower her cholesterol levels. Simvastatin is a hydroxymethylglutaryl-coenzyme A (HMG-CoA) reductase inhibitor, commonly known as a statin. Statins work by inhibiting the enzyme HMG-CoA reductase, which is responsible for a key step in cholesterol synthesis. This leads to a reduction in the production of cholesterol in the liver, thereby lowering LDL-C levels in the blood. The choice of statin and dosage depends on the patient's age, lipid profile, and other individual factors. These included dietary changes with a focus on reducing saturated fat intake and increasing the consumption of vegetables and

fish. Fried foods were limited. Regular exercise was also encouraged to promote overall health and wellbeing. Lifestyle modifications play a crucial role in managing hypercholesterolemia and reducing cardiovascular risk. Following the surgical procedure, the patient was prescribed cefixime, a cephalosporin antibiotic, at a dose of 75 mg twice daily for 7 days to prevent infection. Antibiotics are often prescribed prophylactically after surgical procedures to reduce the risk of infection. Paracetamol was also prescribed at a dose of 180 mg three times a day for 7 days for pain management. Pain management is an important aspect of post-operative care to ensure the patient's comfort and promote healing. Topical fusidic acid ointment 2% was applied to the surgical wounds pre-operatively, post-operatively, and during wound dressing changes. Fusidic acid is a topical antibiotic that is effective against a range of bacteria commonly involved in skin infections. Topical antibiotics help prevent infection and promote wound healing. The patient was advised to consume a high carbohydrate and protein diet, including foods like boiled egg whites and snakehead fish extract, to promote wound healing. Adequate nutrition is essential for wound healing and overall recovery. The importance of regular follow-up with a pediatric nutritionist and pediatric cardiologist was emphasized. This multidisciplinary approach aimed to ensure continuous monitoring of cholesterol levels, assess cardiovascular risk, and provide comprehensive care. Regular follow-up is crucial to monitor the patient's progress, assess the effectiveness of treatment, and adjust the management plan as needed. The treatment strategies employed in this case reflect a comprehensive approach to managing both the cutaneous manifestations and the underlying lipid disorder in a pediatric patient with FH. The multidisciplinary involvement of dermatologists, pediatric cardiologists, and pediatric nutritionists ensures that all aspects of the patient's condition are addressed, promoting optimal outcomes and improving the patient's quality of life.¹⁴⁻¹⁶

The long-term implications of FH in pediatric patients are significant, primarily due to the increased risk of premature cardiovascular disease. This necessitates a proactive and comprehensive approach to management, focusing not only on addressing the immediate cutaneous manifestations but also on mitigating the long-term cardiovascular risks and ensuring the overall well-being of the child. FH is a major risk factor for premature atherosclerosis, the buildup of plaque in the arteries, which can lead to various cardiovascular diseases, including coronary artery disease, stroke, and peripheral artery disease. Children with FH have a significantly higher risk of developing these conditions at a younger age compared to their peers without FH. This increased risk is attributed to the persistently elevated levels of LDL cholesterol, which contributes to the development of atherosclerosis. If left untreated, FH can significantly reduce life expectancy. Individuals with FH have a 10- to 20-fold increased risk of premature death due to cardiovascular disease. This underscores the critical importance of early diagnosis and aggressive management of hypercholesterolemia in children with FH to prevent premature mortality and improve long-term survival. The presence of xanthomas, especially in visible areas, can negatively impact a child's quality of life. Children with xanthomas may experience self-consciousness, social stigma, and emotional distress due to the appearance of these lesions. This can affect their self-esteem, social interactions, and overall well-being. Addressing the cutaneous manifestations of FH through surgical or medical interventions can significantly improve the child's quality of life and reduce the psychological burden associated with the condition. The diagnosis of FH and the need for lifelong treatment and lifestyle modifications can also have a psychosocial impact on children and their families. Children with FH may experience anxiety, depression, and difficulty coping with their condition. The chronic nature of FH and the need for ongoing medical care and lifestyle adjustments can be challenging for children and their families to manage. Providing psychosocial support

and counseling can help them cope with the emotional and social challenges associated with FH. Early diagnosis and aggressive management of hypercholesterolemia are crucial to mitigate the long-term risks associated with FH and improve the patient's overall prognosis. Early detection of FH allows for prompt initiation of treatment and lifestyle interventions, which can significantly reduce the risk of cardiovascular complications. Identifying children with FH at a young age enables early intervention, which can help prevent the development of atherosclerosis and reduce the risk of future cardiovascular events. Aggressive lipid-lowering therapy with statins is the cornerstone of FH management. Statins have been shown to effectively reduce LDL-C levels and decrease the risk of cardiovascular events in both children and adults with FH. Early initiation of statin therapy in children with FH can help prevent the progression of atherosclerosis and reduce the risk of future cardiovascular complications. Lifestyle modifications, including a heart-healthy diet, regular exercise, and maintaining a healthy weight, are also essential for managing FH and reducing cardiovascular risk. Encouraging healthy lifestyle habits from a young age can help children with FH maintain optimal cardiovascular health and reduce their risk of future complications. Family screening is important to identify other family members who may also have FH. Early detection and treatment of FH in family members can help prevent cardiovascular complications. Since FH is an inherited condition, screening family members of affected individuals can help identify those who may also be at risk and enable early intervention. Regular follow-up with a multidisciplinary team is essential to monitor the patient's progress, assess cardiovascular risk, and ensure adherence to the treatment plan. Regular monitoring of lipid levels is crucial to evaluate the effectiveness of treatment and adjust the management plan as needed. Monitoring LDL-C levels helps assess the response to lipid-lowering therapy and allows for adjustments in medication dosage or lifestyle interventions as needed. Regular assessment of

cardiovascular risk factors, such as blood pressure, blood sugar levels, and body mass index, is important to identify and manage any potential complications. Monitoring these risk factors helps identify any early signs of cardiovascular disease and allows for prompt intervention to prevent further progression. Regular follow-up visits provide an opportunity to reinforce the importance of adherence to the treatment plan, including medication adherence and lifestyle modifications. Maintaining open communication with the patient and their family and addressing any concerns or challenges they may face can help improve adherence to the treatment plan. Regular follow-up visits also provide an opportunity to provide ongoing support and education to the patient and their family about FH and its management. Educating the patient and their family about the importance of long-term management, including medication adherence, lifestyle modifications, and regular follow-up, can empower them to take an active role in their care and improve their long-term health outcomes. Regular check-ups with the multidisciplinary team, including dermatologists, pediatric cardiologists, and pediatric nutritionists, are essential to monitor the patient's overall health and manage any complications. These check-ups allow for comprehensive assessment of the patient's cardiovascular health, lipid profile, and any other relevant health issues. Adherence to lipid-lowering medications is crucial for long-term cardiovascular health. Emphasizing the importance of medication adherence and addressing any barriers to adherence, such as cost, side effects, or forgetfulness, can help improve medication compliance and optimize treatment outcomes. Maintaining a heart-healthy lifestyle, including a healthy diet, regular exercise, and avoiding smoking, is essential for reducing cardiovascular risk. Providing ongoing education and support for lifestyle modifications can help patients and their families make sustainable changes that promote long-term cardiovascular health. Providing psychosocial support to the patient and their family can help them cope with the challenges of living with

FH. Addressing the emotional and social impact of FH and providing access to counseling or support groups can help patients and their families navigate the challenges of living with a chronic condition. Educating the patient and their family about FH, its long-term implications, and the importance of adherence to the treatment plan is crucial for empowering them to take an active role in their care. Providing comprehensive education about FH and its management can help patients and their families make informed decisions about their care and improve their long-term health outcomes. By providing comprehensive long-term care, the multidisciplinary team can help children with FH achieve optimal health outcomes and live full and productive lives.¹⁷⁻²⁰

4. Conclusion

This case underscores the importance of a multidisciplinary approach to managing multiple tuberous xanthomas in a child with FH. Surgical excision effectively removes the lesions, and ongoing lipid-lowering therapy is crucial to prevent recurrence and reduce cardiovascular risks associated with FH. Collaboration among dermatologists, pediatric cardiologists, and pediatric nutritionists ensures comprehensive care and enhances the patient's quality of life. Early diagnosis and aggressive management of hypercholesterolemia are crucial to mitigating the long-term risks of premature atherosclerosis and cardiovascular disease associated with FH and improving the patient's overall prognosis. Aggressive lipid-lowering therapy with statins, combined with lifestyle modifications, including a heart-healthy diet and regular exercise, effectively reduces LDL-C levels and decreases the risk of cardiovascular events in both children and adults with FH. Family screening is important to identify other family members who may also have FH, leading to early detection and treatment. Regular follow-up with a multidisciplinary team is essential to monitor the patient's progress, assess cardiovascular risk, and ensure adherence to the treatment plan. By providing comprehensive long-term care, the multidisciplinary

team can help children with FH achieve optimal health outcomes and live full and productive lives.

5. References

1. Okada T, Koseki M, Kato H, Tomita K, Tanaka K, Chang J, et al. A case with sitosterolemia accompanied with macrothrombocytopenia and bilateral elbow tuberous xanthomas. *Atherosclerosis*. 2021; 331: e137.
2. Virk JS, Arora D, Bhaker P, Jain S. Extensive giant tuberous and tendon xanthomas in a 48-year-old gentleman: a case report. *J Orthop Case Rep*. 2021; 11(8): 33–6.
3. Kazmi A, Frewen J, McDonald B, Davison J, O'Toole E. Tuberous xanthoma secondary to homozygous familial hypercholesterolaemia: a life-threatening diagnosis. *Clin Exp Dermatol*. 2022; 47(12): 2336–8.
4. Narasimhan M, Muthu P, Ramakrishnan R, Sriram V. Tuberous xanthoma with cardiac failure in a child. *J Family Med Prim Care*. 2022; 11(6): 3290–2.
5. Gupta D, Kaushal M, Jain S. Multiple tuberous xanthomas diagnosed on fine-needle aspiration cytology - Report of a rare case. *Cytojournal*. 2022; 19(37): 37.
6. Bonnet J-B, Couvert P, Di-Filippo M, Boissiere F, Cristol J-P, Sutra T, et al. Tuberous xanthomatosis is not necessarily associated with increased plasma concentrations of cholestanol in cerebrotendinous xanthomatosis. *J Intern Med*. 2023; 293(1): 121–3.
7. Abramov D, Zaman T, Tarascin I. A case of large elbow tuberous xanthoma. *Cureus*. 2023; 15(5): e39044.
8. Sharanya BS, Logeshwari J, Pinjala P, Thakur RS. A case report of giant tuberous xanthoma with type IIa familial hypercholesterolemia. *Ind J Paediatr Derm*. 2024; 25(1): 31–3.
9. Li F-Z, Zhou K-Y, Fang S. Vigilance against coronary heart disease in patients with

- multiple tuberous xanthomas. *Coron Artery Dis.* 2024; 35(8): 703–4.
10. Sinha R, Singh S, Syed VS. Tuberous xanthoma in type 1 familial hypercholesterolemia. *Int J Contemp Pediatr.* 2024; 11(9): 1317–9.
 11. Matthias AT, Fernandopulle ANR. Tuberous xanthoma: a clue to the diagnosis of familial hypercholesterolemia. *Indian J Clin Cardiol.* 2024; 5(3): 298–9.
 12. Bhagwat PV, Tophakhane RS, Kudligi C, Noronha TM, Thirunavukkarasu A. Familial combined hypercholesterolemia type II b presenting with tuberous xanthoma, tendinous xanthoma and pityriasis rubra pilaris-like lesions. *Indian J Dermatol Venereol Leprol.* 2010; 76(3): 293–6.
 13. Gupta A, Sharma Y, Deo K, Kothari P. “Giant” tuberous xanthomas in a 9-year-old child with homozygous familial hypercholesterolemia. *Ind J Paediatr Derm.* 2015; 16(4): 270.
 14. Savith A, Mandhana S, Srinivasan, Uma, Ponnambalam R. Tendon and tuberous xanthomas, a clinical sign of familial hypercholesterolemia. *J Evid Based Med Healthc.* 2015; 2(12): 1912–4.
 15. Ghosh SK, Majumder B, Dutta A. Tuberous xanthoma as a presenting feature of familial homozygous hypercholesterolemia with aortic regurgitation. *J Pediatr.* 2015; 166(1): 198.
 16. Agirbasli D, Hyatt T, Agirbasli M. Familial hypercholesterolemia with extensive coronary artery disease and tuberous and tendinous xanthomas: a case report and mutation analysis. *J Clin Lipidol.* 2018; 12(4): 863–7.
 17. Dung PTV, Son TT, Thuy TTH, Chien VH, Duy TT, Le Van Huy. Surgical treatment of multiple large tuberous xanthomas in familial hypercholesterolemia: a case report. *Int J Surg Case Rep.* 2021; 89(106596): 106596.
 18. Sharanya BS, Logeshwari J, Pinjala P, Thakur RS. A case report of giant tuberous xanthoma with type IIa familial hypercholesterolemia. *Ind J Paediatr Derm.* 2024; 25(1): 31–3.
 19. Sinha R, Singh S, Syed VS. Tuberous xanthoma in type 1 familial hypercholesterolemia. *Int J Contemp Pediatr.* 2024; 11(9): 1317–9.
 20. Matthias AT, Fernandopulle ANR. Tuberous xanthoma: a clue to the diagnosis of familial hypercholesterolemia. *Indian J Clin Cardiol.* 2024; 5(3): 298–9.