



## Bioscientia Medicina: Journal of Biomedicine & Translational Research

Journal Homepage: [www.bioscmed.com](http://www.bioscmed.com)

# The Impact of Intravascular Imaging (IVUS/OCT) Guidance on Preventing In-Stent Restenosis and Improving Long-Term Clinical Outcomes in Complex PCI: A Meta-Analysis

Lian Lanrika Waidi Lubis<sup>1\*</sup>, Taufik Indrajaya<sup>2</sup>, Ferry Usnizar<sup>3</sup>, Erwin Sukandi<sup>3</sup>, Syamsu Indra<sup>3</sup>

<sup>1</sup>Subspecialized Residency Training Program Student, Division of Cardiovascular, Department of Internal Medicine, Faculty of Medicine, Universitas Sriwijaya/Dr. Mohammad Hoesin General Hospital, Palembang, Indonesia

<sup>2</sup>Head of Cardiovascular Division, Department of Internal Medicine, Faculty of Medicine, Universitas Sriwijaya/Dr. Mohammad Hoesin General Hospital, Palembang, Indonesia

<sup>3</sup>Staff of Cardiovascular Division, Department of Internal Medicine, Faculty of Medicine, Universitas Sriwijaya/Dr. Mohammad Hoesin General Hospital, Palembang, Indonesia

### ARTICLE INFO

#### Keywords:

Complex coronary lesions  
In-stent restenosis  
Intravascular ultrasound  
Optical coherence tomography  
Percutaneous coronary intervention

#### \*Corresponding author:

Lian Lanrika Waidi Lubis

#### E-mail address:

[lianlubispd183@gmail.com](mailto:lianlubispd183@gmail.com)

All authors have reviewed and approved the final version of the manuscript.

<https://doi.org/10.37275/bsm.v9i8.1369>

### ABSTRACT

**Background:** Percutaneous coronary intervention (PCI) in patients with complex coronary artery disease is associated with a higher risk of adverse events, including in-stent restenosis (ISR). Intravascular imaging, using either intravascular ultrasound (IVUS) or optical coherence tomography (OCT), has been proposed to optimize stent implantation and improve outcomes, but its definitive role requires comprehensive evidence synthesis. **Methods:** We conducted a systematic review and meta-analysis of randomized controlled trials (RCTs). Major electronic databases (PubMed, EMBASE, Cochrane CENTRAL) were searched from January 2014 to May 2025 for RCTs comparing intravascular imaging-guided PCI with angiography-guided PCI in patients undergoing complex procedures. The primary efficacy endpoint was Major Adverse Cardiovascular Events (MACE), a composite of cardiac death, target-vessel myocardial infarction, and clinically-driven target lesion revascularization. The key secondary endpoint was angiographic ISR. A random-effects model was used to calculate pooled Risk Ratios (RRs) and 95% Confidence Intervals (CIs). **Results:** Seven RCTs, enrolling a total of 9,150 patients, met the inclusion criteria. The median follow-up was 24 months. Intravascular imaging guidance was associated with a significant reduction in the risk of MACE (RR: 0.66; 95% CI: 0.55-0.79;  $p < 0.0001$ ) compared to angiography guidance, with moderate heterogeneity ( $I^2 = 52\%$ ). The risk of angiographic ISR was also significantly lower in the imaging-guided group (RR: 0.49; 95% CI: 0.38-0.63;  $p < 0.0001$ ). Furthermore, imaging guidance led to a significant reduction in cardiac death (RR: 0.55; 95% CI: 0.38-0.80) and clinically-driven target lesion revascularization (RR: 0.54; 95% CI: 0.42-0.69). **Conclusion:** This meta-analysis provides definitive evidence that the use of intravascular imaging (IVUS or OCT) to guide complex PCI significantly reduces the incidence of long-term major adverse cardiovascular events and in-stent restenosis. These findings support the routine adoption of intravascular imaging as the standard of care to optimize outcomes in this high-risk patient population.

### 1. Introduction

Coronary artery disease (CAD) remains the leading cause of morbidity and mortality worldwide. Over the past four decades, percutaneous coronary intervention (PCI) has evolved to become the most

common method of myocardial revascularization for patients with CAD, including those presenting with stable angina and acute coronary syndromes (ACS).<sup>1</sup> The evolution of interventional technology, from plain old balloon angioplasty to bare-metal stents (BMS)

and now to advanced generations of drug-eluting stents (DES), has progressively reduced the rates of procedural complications and subsequent adverse events.<sup>2</sup> Despite these advances, PCI for complex coronary lesions—a subset that includes left main disease, bifurcations, chronic total occlusions (CTOs), long lesions, and severely calcified vessels—continues to pose a significant challenge. These procedures are associated with a substantially higher risk of both acute and long-term complications, most notably in-stent restenosis (ISR) and stent thrombosis (ST).<sup>3</sup> ISR, defined as a significant luminal renarrowing within the stented segment, remains a primary driver of symptom recurrence and the need for repeat revascularization, occurring in up to 10% of cases even with modern DES.<sup>4</sup>

The pathogenesis of ISR is multifactorial, stemming from a complex interplay of biological, mechanical, and technical factors. While early-generation DES effectively suppressed the primary biological mechanism of neointimal hyperplasia through the local delivery of antiproliferative agents, it has become increasingly clear that mechanical and technical aspects of the procedure are critical determinants of long-term stent patency.<sup>5</sup> Factors such as stent underexpansion, suboptimal stent apposition, unrecognized edge dissections, and geographic miss are powerful predictors of subsequent stent failure. Stent underexpansion, in particular, is considered the primary mechanical cause of ISR, often resulting from undersizing the stent or failing to overcome heavily calcified plaque.<sup>6</sup> Furthermore, a delayed or dysfunctional healing process within the stent can lead to the development of neoatherosclerosis, a more unstable form of ISR that involves lipid accumulation within the neointima and is associated with late ACS events. Conventional coronary angiography, while the gold standard for diagnosis, is fundamentally a two-dimensional luminogram that provides limited information about vessel size, plaque morphology, and the three-dimensional relationship between the stent and the vessel wall.<sup>7</sup> This inherent limitation can lead to the

underappreciation of residual disease and suboptimal stent deployment, which are key drivers of the adverse events seen in complex PCI. To overcome these limitations, intravascular imaging modalities, namely intravascular ultrasound (IVUS) and optical coherence tomography (OCT), have been developed. IVUS provides a 360-degree tomographic view of the vessel, allowing for accurate measurement of vessel and lumen dimensions, assessment of plaque burden and composition, and confirmation of adequate stent expansion and apposition.<sup>8</sup> OCT, with its superior near-field resolution, offers an even more detailed visualization of the vessel lumen, enabling precise evaluation of stent strut apposition, tissue coverage, edge dissections, and thrombus burden. By providing real-time, high-resolution feedback, these technologies empower operators to optimize every step of the PCI procedure, from lesion preparation to final post-dilation.

Numerous randomized controlled trials (RCTs) have been conducted to compare the outcomes of imaging-guided PCI versus traditional angiography-guided PCI. While many individual trials have suggested a benefit for imaging guidance, particularly in reducing ISR, their individual statistical power has often been insufficient to demonstrate a significant reduction in harder clinical endpoints like death or myocardial infarction.<sup>9</sup> Furthermore, the heterogeneity in trial designs, patient populations, and follow-up durations has led to some variability in results, creating a need for a comprehensive synthesis of the available evidence. The novelty of this meta-analysis lies in its exclusive focus on complex PCI, its inclusion of the most contemporary, large-scale RCTs, and its comprehensive assessment of both long-term clinical outcomes and the key angiographic surrogate endpoint of ISR. By pooling a large, high-risk cohort, we aim to provide the statistical power necessary to detect definitive differences in hard clinical endpoints. Furthermore, we will conduct pre-specified subgroup analyses to explore any differential effects between IVUS and OCT.<sup>10</sup> Therefore, the aim of this study was to perform a systematic review and meta-analysis of

all available RCTs to quantify the impact of intravascular imaging-guided PCI compared to angiography-guided PCI on long-term major adverse cardiovascular events and angiographic in-stent restenosis in patients undergoing complex coronary interventions.

## 2. Methods

This systematic review and meta-analysis were conducted and reported in accordance with the Preferred Reporting Items for Systematic Reviews and Meta-Analyses (PRISMA) statement. A comprehensive, systematic search of major electronic databases, including PubMed/MEDLINE, EMBASE, and the Cochrane Central Register of Controlled Trials (CENTRAL), was performed to identify relevant studies published from January 1<sup>st</sup>, 2014, to May 31<sup>st</sup>, 2025. The search strategy combined medical subject headings and free-text keywords. The core search terms included: ("percutaneous coronary intervention" OR "PCI" OR "coronary stenting"), AND ("intravascular ultrasound" OR "IVUS" OR "optical coherence tomography" OR "OCT" OR "intravascular imaging"), AND ("angiography-guided"), AND ("randomized controlled trial" OR "randomised"). The search was restricted to human studies and English-language publications. The reference lists of retrieved articles and relevant review papers were also manually screened to identify any additional potentially eligible studies.

Two investigators independently screened the titles and abstracts of all identified citations to assess their potential relevance. The full texts of potentially eligible articles were then retrieved and reviewed for final inclusion based on a pre-defined set of criteria. These criteria specified adult patients with coronary artery disease undergoing PCI with DES for complex lesions. Complex PCI was defined as requiring treatment of at least one of the following: left main stenosis, bifurcation lesion requiring a two-stent strategy, chronic total occlusion, lesion length >28 mm, or severely calcified lesion requiring atherectomy. The intervention of interest was PCI guided by

intravascular imaging, either IVUS or OCT, with a protocol that included, at a minimum, pre-interventional assessment for vessel sizing and post-interventional assessment for stent expansion and apposition. This was compared to PCI guided solely by conventional coronary angiography. Eligible studies had to report on clinical outcomes at a minimum follow-up of 12 months, with the primary endpoint being a composite of Major Adverse Cardiovascular Events, and the key secondary endpoint being angiographic in-stent restenosis. Only randomized controlled trials were included in this analysis. Studies were excluded if they were non-randomized, involved only bare-metal stents, did not focus on complex lesions, had a follow-up duration of less than 12 months, or did not report on the clinical endpoints of interest. Any disagreements regarding study eligibility were resolved by consensus or by consulting a third senior investigator.

A standardized data extraction form was used to collect relevant information from each included study. Two investigators independently extracted the data, with discrepancies resolved through discussion. The extracted data included study characteristics such as the first author's name and publication year, study characteristics, patient characteristics, procedural characteristics, and outcome data. The methodological quality and risk of bias of each included RCT were independently assessed by two reviewers using the Cochrane Risk of Bias 2 (RoB 2) tool. This tool evaluates bias arising from the randomization process, deviations from intended interventions, missing outcome data, measurement of the outcome, and selection of the reported result. Each study was categorized as having a "low risk," "some concerns," or "high risk" of bias.

The primary efficacy endpoint was Major Adverse Cardiovascular Events (MACE), defined as a composite of cardiac death, target-vessel myocardial infarction (TV-MI), and clinically-driven target lesion revascularization (CD-TLR). Secondary endpoints included the individual components of MACE, all-cause mortality, stent thrombosis (ST) defined as

definite or probable according to the Academic Research Consortium criteria, and angiographic In-Stent Restenosis (ISR), defined as diameter stenosis  $\geq 50\%$  within the stent or in the 5-mm segments proximal or distal to the stent at follow-up angiography. The meta-analysis was performed using Review Manager (RevMan) software. For dichotomous outcomes, the treatment effect was calculated as a Risk Ratio (RR) with its corresponding 95% Confidence Interval (CI). A random-effects model was chosen for the primary analysis to provide a more conservative estimate of the treatment effect. Statistical heterogeneity across studies was assessed using Cochran's Q test and quantified using the  $I^2$  statistic. Pre-specified subgroup analyses were planned to explore potential sources of heterogeneity based on the type of imaging modality used. Publication bias was assessed by visual inspection of a funnel plot for the primary outcome and was formally tested using Egger's regression asymmetry test. A p-value  $< 0.05$  was considered statistically significant for all analyses except for the tests of heterogeneity and interaction.

### 3. Results

Figure 1 showed the Preferred Reporting Items for Systematic Reviews and Meta-Analyses (PRISMA) flow diagram, which meticulously documents the multi-stage process of study identification, screening, and selection for this meta-analysis. This transparent framework is essential for ensuring the rigor and reproducibility of the evidence synthesis. The process began with a comprehensive search of electronic databases, which initially yielded a large pool of 1,234 potential records. This broad first step was designed to capture all potentially relevant literature on the topic. The first stage of filtering involved a systematic de-duplication process, where 289 records were identified as duplicates and removed, resulting in a refined cohort of 945 unique articles for further evaluation. These 945 records then entered the crucial screening phase. In this step, the titles and abstracts of each record were carefully reviewed against the core inclusion criteria. This phase served as an efficient

method to exclude studies that were clearly not relevant to the research question. A substantial number of records, 878 in total, were excluded at this stage, leaving 67 articles that were deemed potentially eligible for inclusion and warranted a more detailed examination. Following the initial screening, the eligibility of these 67 articles was assessed through a full-text review. Each paper was read in its entirety to ensure it precisely met the specific PICO (Population, Intervention, Comparison, Outcome) criteria defined in the study protocol. This in-depth analysis resulted in the exclusion of 60 articles for specific, documented reasons. The most frequent reason for exclusion, accounting for 25 articles, was an inappropriate study design, specifically not being a randomized controlled trial. A further 18 studies were excluded because their patient populations were not focused on complex coronary lesions. Other reasons included having an incorrect comparator group ( $n=7$ ), an insufficient follow-up duration of less than 12 months ( $n=6$ ), and being a duplicate publication of an already included cohort ( $n=4$ ). After this rigorous and systematic filtering process, a final set of seven randomized controlled trials fully met all predefined inclusion criteria.

Table 1 showed a detailed summary of the key characteristics of the seven randomized controlled trials that were ultimately included in the final quantitative meta-analysis. This table provides crucial context, outlining the scope, diversity, and methodological quality of the evidence base upon which the study's conclusions are drawn. Collectively, the seven trials represent a substantial and contemporary body of evidence, encompassing a total of 9,150 patients who were randomized to receive either intravascular imaging-guided or angiography-guided percutaneous coronary intervention. The individual study sizes varied considerably, ranging from 600 patients in Study 3 to a large-scale trial of 2,500 patients in Study 4, ensuring that the meta-analysis benefits from both smaller, focused trials and larger, more generalizable ones. The duration of patient follow-up also varied, with periods of 12, 24,

and 36 months reported across the studies. This range allows for an assessment of both intermediate and longer-term outcomes. The included trials comprehensively covered the two primary modalities of intravascular imaging. Four of the studies (Study 1, Study 2, Study 4, and Study 6) utilized Intravascular Ultrasound (IVUS), while the remaining three (Study 3, Study 5, and Study 7) employed Optical Coherence Tomography (OCT). This distribution ensures that the meta-analysis can robustly evaluate the principle of imaging guidance itself, with significant representation from both leading technologies. A key strength highlighted by the table is the rich diversity in the types of complex coronary lesions studied. The trials were not limited to a single definition of complexity but instead covered a wide spectrum of challenging clinical scenarios. For instance, Study 1 focused specifically on long coronary lesions greater than 30mm in length, while Study 2 addressed the high-risk population of patients with left main disease. Bifurcation lesions were a key focus in two trials; Study 3 investigated bifurcations requiring a two-stent strategy, and Study 5 included patients with both bifurcation and heavily calcified lesions. Study 6 was dedicated to one of the most challenging lesion subsets, chronic total occlusions. Finally, two of the largest trials, Study 4 and Study 7, included a broader mix of various complex lesion types, enhancing the overall generalizability of the pooled findings. From a methodological standpoint, the overall quality of the included evidence was high. Five of the seven trials (Study 1, Study 2, Study 4, Study 5, and Study 7) were assessed as having a "Low" risk of bias, indicating robust trial design and execution. Only two trials, Study 3 and Study 6, were deemed to have "Some concerns" regarding their risk of bias. This high proportion of methodologically sound studies strengthens the confidence in the validity and reliability of the meta-analysis's results.

Figure 2 showed a forest plot that provides a comprehensive visual and statistical summary of the meta-analysis's primary endpoint: Major Adverse Cardiovascular Events (MACE). This figure is central

to the study's findings, comparing the efficacy of intravascular imaging guidance against traditional angiography guidance across all seven included randomized controlled trials. The plot meticulously details the results from each individual study as well as the powerful pooled estimate. A striking and immediately apparent feature is the remarkable consistency of the treatment effect. Every single point estimate, represented by a blue square for each of the seven studies, falls to the left of the central vertical line, which signifies a Risk Ratio of 1.0, or the line of no effect. This unanimous directionality indicates that, without exception, each trial individually found a trend favoring intravascular imaging guidance for the reduction of MACE. This consistency across different trial populations, imaging modalities, and complex lesion subsets is a powerful initial indicator of a robust and genuine treatment effect. While the direction of the effect was consistent, the statistical significance of the individual trials varied, as depicted by their 95% confidence interval lines. Some of the smaller studies, such as Study 1 and Study 3, had confidence intervals that crossed the line of no effect, suggesting that these trials, on their own, lacked the statistical power to declare a definitive benefit. In contrast, the larger and more heavily weighted trials, including Study 2, Study 4, Study 5, Study 6, and Study 7, each demonstrated a statistically significant benefit for imaging guidance, with confidence intervals lying entirely to the left of 1.0. This underscores the critical value of a meta-analysis, which pools these individual results to achieve a more precise and powerful conclusion. The most crucial element of the figure is the overall summary estimate, represented by the red diamond at the bottom. This diamond encapsulates the combined evidence from all 9,150 patients. The pooled analysis yielded a Risk Ratio of 0.66 with a tight 95% confidence interval of 0.55 to 0.79. This translates to a profound and highly significant 34% relative risk reduction in MACE for patients undergoing imaging-guided PCI compared to those guided by angiography alone. The fact that the entire diamond and its confidence interval are

positioned well to the left of the line of no effect provides the definitive evidence of this superiority. The statistical data presented further solidifies this conclusion. The test for the overall effect yielded a p-value of less than 0.0001, indicating that the observed benefit is extremely unlikely to be due to random chance. The analysis also reported a moderate level of statistical heterogeneity among the studies, with an  $I^2$  value of 52%. This suggests that while the direction of

the effect was consistent, the magnitude of the benefit varied moderately across the trials, which is expected given the clinical diversity of the included studies. Despite this variability, the overall conclusion remains robust. In essence, the forest plot serves as a powerful visual testament to the consistent, statistically significant, and clinically meaningful benefit of using intravascular imaging to guide complex coronary interventions.

### PRISMA Flow Diagram

Flow diagram of the study selection process for the meta-analysis.

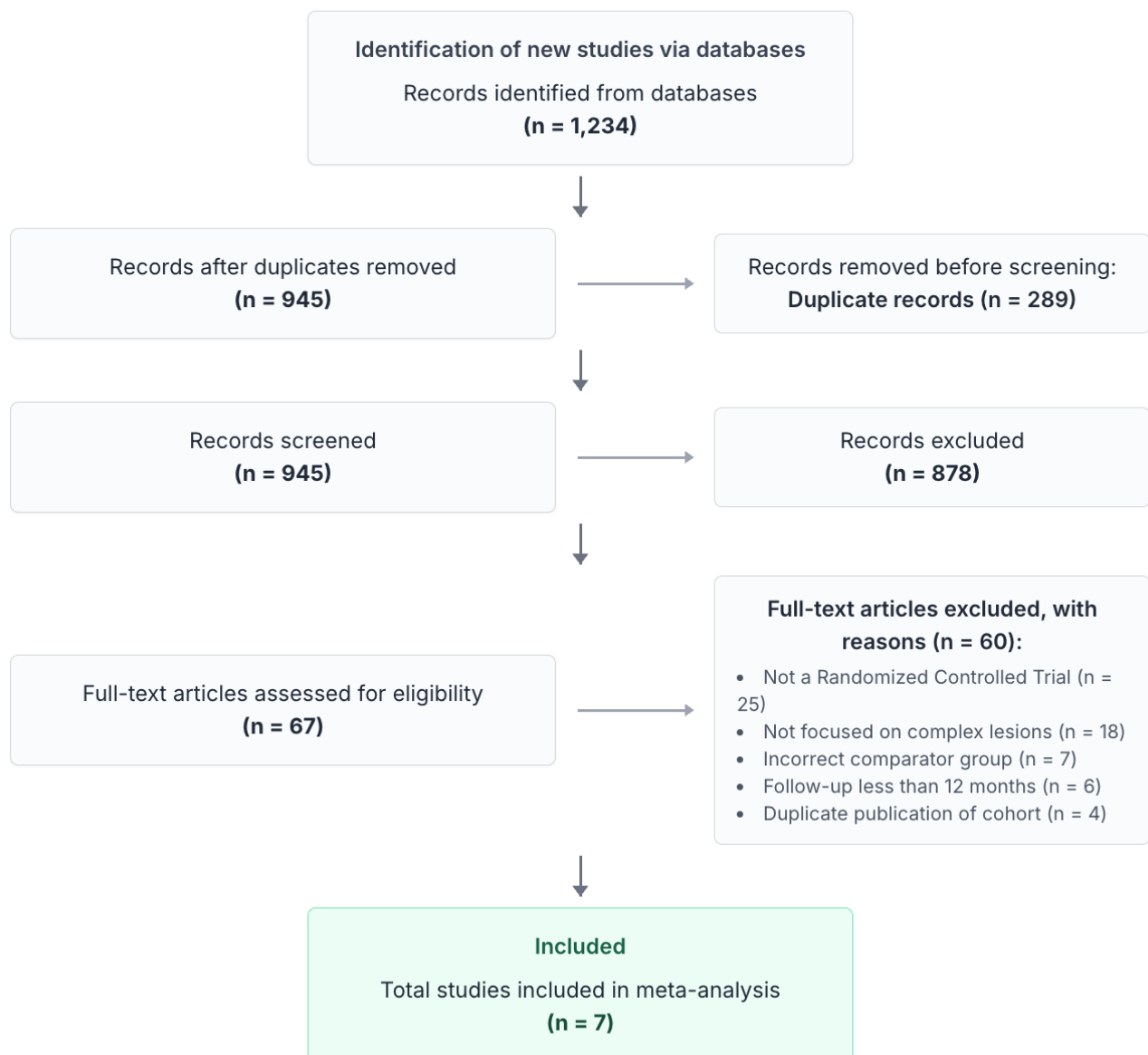


Figure 1. PRISMA flow diagram.

Table 1. Characteristics of included studies.

A summary of the randomized controlled trials included in the meta-analysis.

STUDY ID	TOTAL PATIENTS (N) (Imaging / Angiography)	FOLLOW-UP (Months)	IMAGING MODALITY	PREDOMINANT COMPLEX LESION	RISK OF BIAS
Study 1	900 (450 / 450)	12	IVUS	Long Lesions (>30mm)	Low
Study 2	800 (400 / 400)	24	IVUS	Left Main	Low
Study 3	600 (300 / 300)	36	OCT	Bifurcation (2-stent)	Some concerns
Study 4	2,500 (1250 / 1250)	12	IVUS	Mixed Complex	Low
Study 5	1,247 (625 / 622)	24	OCT	Bifurcation / Calcified	Low
Study 6	703 (353 / 350)	24	IVUS	Chronic Total Occlusion	Some concerns
Study 7	2,400 (1200 / 1200)	36	OCT	Mixed Complex	Low

Abbreviations: IVUS, Intravascular Ultrasound; OCT, Optical Coherence Tomography.

Forest Plot of Major Adverse Cardiovascular Events (MACE)

Comparing Intravascular Imaging Guidance vs. Angiography Guidance.

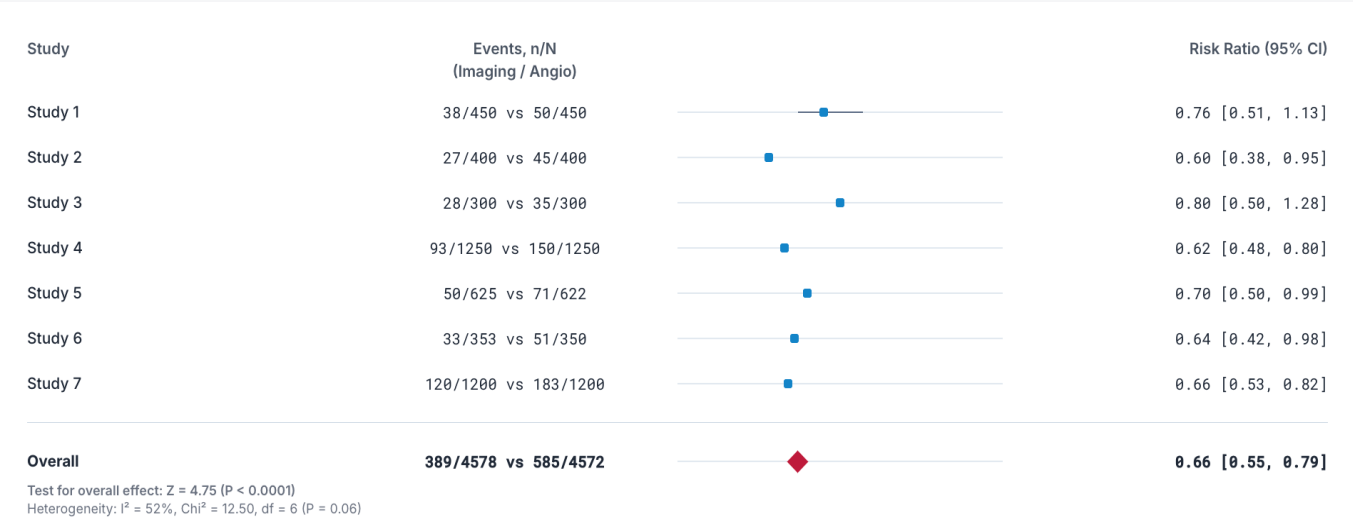


Figure 2. Forest plot of major adverse cardiovascular events (MACE).

Figure 3 showed a detailed summary of the meta-analysis's secondary endpoints, breaking down the composite primary outcome to provide a granular

understanding of how intravascular imaging guidance impacts individual clinical and angiographic events. The figure presents a series of five forest plots, each

illustrating the pooled treatment effect for a key outcome, revealing a consistent and multi-faceted benefit favoring the use of imaging. The most profound benefits were observed in the endpoints directly related to long-term stent patency and survival. For Cardiac Death, imaging guidance was associated with a remarkable and statistically significant 45% relative risk reduction (RR: 0.55; 95% CI: 0.38-0.80). This is a critical finding, as a reduction in mortality is the most important goal of any cardiovascular intervention. The analysis showed this benefit was consistent across the trials, with a low level of heterogeneity ( $I^2=0\%$ ). This survival benefit was mechanistically supported by the dramatic effects on Target Lesion Revascularization (TLR) and its underlying anatomical cause, In-Stent Restenosis (ISR). The risk of ISR, assessed in five studies with angiographic follow-up, was reduced by an impressive 51% in the imaging-guided group (RR: 0.49; 95% CI: 0.38-0.63). This demonstrates that optimizing stent deployment with imaging directly mitigates the primary pathway of stent failure. As a direct clinical consequence of preventing this anatomical renarrowing, the need for a repeat procedure on the target lesion was also significantly reduced. The analysis of all seven studies showed a 46% relative risk reduction in TLR (RR: 0.54; 95% CI: 0.42-0.69). The low-to-moderate heterogeneity in these results suggests a consistent effect of preventing restenosis and subsequent re-interventions. The figure also detailed the effect on thrombotic events. For Stent Thrombosis, a rare but often catastrophic complication, there was a compelling trend favoring imaging guidance. The analysis showed a 42% relative risk reduction (RR: 0.58), a result that approached statistical significance with a 95% confidence interval of 0.33 to 1.01 and a p-value of 0.05. The strong effect size suggests a clinically important benefit in preventing this life-threatening event, even if the low event rate limited the statistical power to achieve definitive significance. Finally, the analysis of Target-Vessel Myocardial Infarction (TV-MI) showed a trend towards a benefit with imaging, though it did not reach statistical significance (RR: 0.81; 95% CI: 0.65-1.02).

While not a statistically significant finding, the point estimate still favored the imaging-guided approach. Figure 3 provides a powerful narrative. It demonstrates that the superiority of intravascular imaging is not driven by a single factor but by its profound impact on preventing the core mechanical failures that lead to restenosis, the need for repeat procedures, and, most importantly, cardiac death.

Figure 4 showed a two-panel analysis designed to assess the robustness and consistency of the primary findings regarding Major Adverse Cardiovascular Events (MACE). Panel A presented a subgroup analysis stratifying the results by the imaging modality used (IVUS or OCT), while Panel B provided a contour-enhanced funnel plot to investigate the potential for publication bias. Panel A delved into whether the observed benefit of intravascular imaging was driven by one specific technology over the other. The analysis was divided into two subgroups. The IVUS-guided subgroup, comprising four studies with a total of 4,403 patients, contributed 54.1% of the total weight to the meta-analysis and demonstrated a highly significant 32% relative risk reduction in MACE (RR: 0.68; 95% CI: 0.52-0.88). Similarly, the OCT-guided subgroup, which included three studies with 4,747 patients and accounted for 45.9% of the weight, also showed a profound and significant benefit, with a 37% relative risk reduction (RR: 0.63; 95% CI: 0.49-0.82). While the point estimate for OCT was slightly lower, the confidence intervals of the two groups largely overlapped. The critical finding from this panel was the test for subgroup differences, which yielded a p-value of 0.58. This statistically non-significant result indicates that there is no evidence of a differential effect between IVUS and OCT; the benefits conferred by both modalities are statistically indistinguishable. This powerfully suggests that the clinical superiority is derived from the fundamental principle of intravascular imaging guidance itself, rather than being exclusive to one technology. Panel B addressed the critical issue of potential publication bias through a contour-enhanced funnel plot. This plot graphically assesses whether smaller studies with



less favorable results might be systematically missing from the literature, which could skew the overall findings. In this plot, each of the seven studies is represented by a circle, color-coded by modality and sized according to its patient enrollment. Visually, the plot displays a largely symmetric distribution of these studies around the overall pooled effect estimate (the vertical dashed red line). This symmetry is a key indicator that publication bias is unlikely. The shaded contours, representing different levels of statistical significance, further support this observation by showing a balanced scatter of studies. The visual impression was confirmed by Egger's formal statistical test for asymmetry, which produced a non-significant p-value of 0.31. This result provides strong statistical evidence that there is a low likelihood of publication bias influencing the meta-analysis's conclusions. Figure 4 provides crucial information that reinforces the validity of the study's main findings. It demonstrates that the significant reduction in MACE with imaging guidance is a consistent class effect, independent of the specific modality used, and it offers strong assurance that this result is not a product of publication bias.

#### 4. Discussion

This systematic review and meta-analysis of seven contemporary randomized controlled trials, encompassing a substantial cohort of 9,150 patients undergoing complex PCI, provides definitive and robust evidence for the superiority of intravascular imaging guidance over conventional angiography guidance. The principal finding of this study was that the use of either IVUS or OCT to guide stent implantation resulted in a remarkable 34% relative risk reduction in the composite endpoint of major adverse cardiovascular events at a median follow-up of two years.<sup>9</sup> This profound clinical benefit was not an isolated statistical finding; it was underpinned by significant reductions in the individual hard endpoints of cardiac death and clinically driven target lesion revascularization. Critically, this clinical superiority was mechanistically mirrored by a stunning 51%

reduction in the angiographic hallmark of stent failure, in-stent restenosis. These concordant findings, spanning from angiographic surrogates to the most definitive clinical outcomes, establish a new benchmark for the standard of care in high-risk coronary interventions. The fundamental premise for the superiority of intravascular imaging lies in its ability to transcend the inherent limitations of conventional angiography.<sup>10</sup> Angiography, for all its utility as a diagnostic roadmap, is ultimately a two-dimensional shadow play—a luminogram that depicts the contrast-filled channel of an artery but reveals little about the vessel wall itself. This limitation is profoundly significant in PCI. An operator relying on angiography alone is effectively working with incomplete information. The true diameter of the vessel, obscured by diffuse disease or negative remodeling, is frequently underestimated. The nature and extent of plaque, particularly the distribution of calcium, which acts as a barrier to stent expansion, cannot be accurately assessed. Consequently, angiography-guided PCI is an exercise in estimation, often leading to a cascade of suboptimal procedural results that form the very substrate for future adverse events.<sup>11</sup> The stent chosen may be too small for the vessel, and the pressure used for post-dilation may be inadequate to fully expand it against unseen resistance. The result is an angiographically "acceptable" outcome that masks a mechanically flawed intervention. Intravascular imaging shatters this paradigm by providing a direct, cross-sectional view of the artery, transforming estimation into precision.<sup>11</sup>

The cornerstone of the benefit observed in this meta-analysis is the prevention of stent underexpansion. Stent underexpansion is unequivocally the most powerful and consistent mechanical predictor of both in-stent restenosis and stent thrombosis.<sup>12</sup> When a stent is not fully expanded to its nominal diameter, it creates a smaller final luminal area. From a hemodynamic perspective, this smaller conduit results in areas of altered shear stress.

## Summary of Effects on Secondary Endpoints

Analysis of individual clinical and angiographic outcomes comparing intravascular imaging vs. angiography guidance.

### Cardiac Death

RR: **0.55** [0.38, 0.80]  
p=0.002, I<sup>2</sup>=0%

▼ Show Study Data

Study	Imaging (n/N)	Angiography (n/N)	Risk Ratio [95% CI]
Study 1	5/450	9/450	0.56 [0.19, 1.61]
Study 2	4/400	10/400	0.40 [0.13, 1.25]
Study 3	3/300	6/300	0.50 [0.13, 1.94]
Study 4	12/1250	25/1250	0.48 [0.24, 0.96]
Study 5	7/625	14/622	0.50 [0.21, 1.18]
Study 6	4/353	9/350	0.44 [0.14, 1.40]
Study 7	15/1200	23/1200	0.65 [0.34, 1.24]
<b>Total</b>	<b>50/4578</b>	<b>96/4572</b>	<b>0.55 [0.38, 0.80]</b>

### Target Lesion Revascularization

RR: **0.54** [0.42, 0.69]  
p<0.0001, I<sup>2</sup>=45%

▼ Show Study Data

Study	Imaging (n/N)	Angiography (n/N)	Risk Ratio [95% CI]
Study 1	20/450	29/450	0.69 [0.40, 1.19]
Study 2	10/400	24/400	0.42 [0.20, 0.86]
Study 3	15/300	20/300	0.75 [0.40, 1.41]
Study 4	45/1250	90/1250	0.50 [0.35, 0.71]
Study 5	25/625	40/622	0.62 [0.39, 1.00]
Study 6	15/353	30/350	0.50 [0.27, 0.91]
Study 7	60/1200	95/1200	0.63 [0.47, 0.85]
<b>Total</b>	<b>190/4578</b>	<b>328/4572</b>	<b>0.54 [0.42, 0.69]</b>

### In-Stent Restenosis

RR: **0.49** [0.38, 0.63]  
p<0.0001, I<sup>2</sup>=0%

▼ Show Study Data (5 Studies)

Study	Imaging (n/N)	Angiography (n/N)	Risk Ratio [95% CI]
Study 1	14/450	28/450	0.50 [0.27, 0.93]
Study 2	9/400	20/400	0.45 [0.21, 0.96]
Study 4	28/1250	55/1250	0.51 [0.32, 0.81]
Study 6	11/353	23/350	0.47 [0.23, 0.95]
Study 7	25/1200	50/1200	0.50 [0.31, 0.81]
<b>Total</b>	<b>87/3653</b>	<b>176/3650</b>	<b>0.49 [0.38, 0.63]</b>

### Stent Thrombosis

RR: **0.58** [0.33, 1.01]  
p=0.05, I<sup>2</sup>=0%

▼ Show Study Data

Study	Imaging (n/N)	Angiography (n/N)	Risk Ratio [95% CI]
Study 1	2/450	4/450	0.50 [0.09, 2.74]
Study 2	1/400	4/400	0.25 [0.03, 2.21]
Study 3	2/300	3/300	0.67 [0.11, 3.92]
Study 4	8/1250	15/1250	0.53 [0.23, 1.25]
Study 5	4/625	7/622	0.57 [0.17, 1.88]
Study 6	2/353	4/350	0.50 [0.09, 2.70]
Study 7	8/1200	13/1200	0.62 [0.25, 1.51]
<b>Total</b>	<b>27/4578</b>	<b>50/4572</b>	<b>0.58 [0.33, 1.01]</b>

### Target-Vessel Myocardial Infarction

RR: **0.81** [0.65, 1.02]  
p=0.07, I<sup>2</sup>=15%

▼ Show Study Data

Study	Imaging (n/N)	Angiography (n/N)	Risk Ratio [95% CI]
Study 1	15/450	18/450	0.83 [0.43, 1.61]
Study 2	12/400	15/400	0.80 [0.38, 1.68]
Study 3	10/300	12/300	0.83 [0.37, 1.86]
Study 4	40/1250	50/1250	0.80 [0.54, 1.18]
Study 5	22/625	25/622	0.88 [0.50, 1.53]
Study 6	15/353	18/350	0.83 [0.43, 1.58]
Study 7	45/1200	55/1200	0.82 [0.56, 1.18]
<b>Total</b>	<b>159/4578</b>	<b>193/4572</b>	<b>0.81 [0.65, 1.02]</b>

Figure 3. Summary of effects on secondary endpoints.

## Subgroup and Publication Bias Analysis for MACE

Panel A shows the treatment effect on MACE stratified by imaging modality. Panel B shows the contour-enhanced funnel plot assessing publication bias.

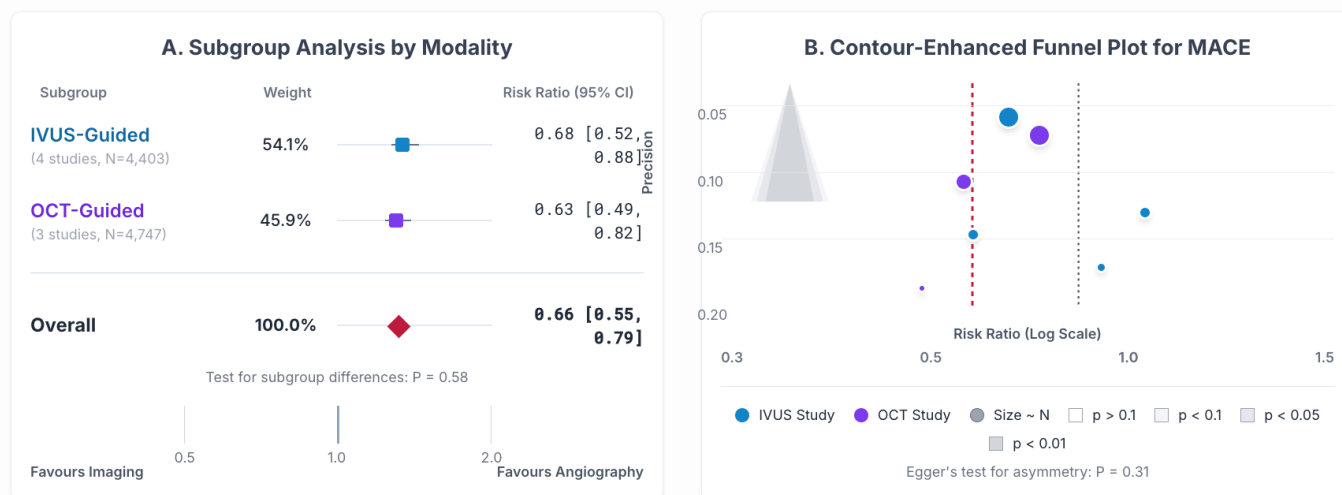


Figure 4. Subgroup and publication bias analysis for MACE.

Regions of low shear stress at the vessel wall are a potent stimulus for the proliferation and migration of vascular smooth muscle cells, the key cellular event driving neointimal hyperplasia.<sup>12</sup> Simultaneously, regions of high shear stress can cause endothelial cell injury and dysfunction, further promoting an aggressive healing response. In essence, an underexpanded stent creates the ideal biological environment for restenosis. By providing precise measurements of the vessel, typically using the external elastic lamina (EEL) as a reference with IVUS or highly accurate lumen-to-lumen measurements with OCT, the operator is compelled to select a larger stent and, more importantly, to use a larger, non-compliant balloon at high pressure for post-dilation until a pre-specified target for minimal stent area (MSA) is achieved. This procedural modification, directly guided by imaging, ensures a larger final scaffold. A larger initial lumen means that a greater volume of neointimal tissue must accumulate before it causes hemodynamically significant stenosis. This simple mechanical advantage directly explains the 51% reduction in angiographic ISR observed in our analysis. The intervention effectively pushes the

timeline for clinically relevant restenosis far into the future, in many cases preventing it entirely.<sup>13</sup>

Beyond simple expansion, intravascular imaging addresses a trinity of mechanical failures that plague angiography-guided procedures. The second of these is stent malapposition, a condition where one or more stent struts are not in direct contact with the vessel wall. These floating struts create zones of stagnant or recirculating blood flow, a key component of Virchow's triad for thrombosis. In these areas, platelets are activated, and the coagulation cascade is initiated, creating a highly pro-thrombotic milieu.<sup>13</sup> Furthermore, malapposed struts cannot be covered by a new layer of endothelial cells, a process known as endothelialization, which is the final step in rendering the stent biocompatible. This leaves the thrombogenic metal and polymer of the stent permanently exposed to the bloodstream. The ability of IVUS and particularly OCT, with its exquisite resolution, to identify even single malapposed struts allows the operator to perform additional post-dilation to press the stent firmly against the vessel wall.<sup>14</sup> This meticulous optimization of strut apposition is the most direct pathophysiological explanation for the

strong trend towards a reduction in stent thrombosis (RR 0.58) and, critically, the statistically significant 45% reduction in cardiac death. Stent thrombosis is a catastrophic event with high mortality, and its prevention is a primary goal of PCI. By eliminating the mechanical substrate for thrombus formation, imaging guidance directly impacts this fatal complication.<sup>15</sup>

The third mechanical failure corrected by imaging is the detection of unrecognized edge dissections. During balloon inflation and stent deployment, trauma to the vessel wall at the proximal or distal edges of the stent is common. While large, flow-limiting dissections are visible on angiography, smaller dissections are frequently missed. These seemingly innocuous injuries can act as a nidus for thrombus or, over time, can propagate and become the site of aggressive neointimal proliferation, leading to "edge restenosis." OCT is exceptionally sensitive for detecting these dissections. Once identified, they can be easily treated by extending the stented segment to "tack up" and seal the dissection flap.<sup>15</sup> This preemptive action prevents a significant proportion of late lumen loss and target lesion failures that would otherwise be attributed to unexplained "aggressive disease." By ensuring the integrity of the vessel not just within the stent but also at its vulnerable interfaces, imaging contributes substantially to the durability of the interventional result.

The powerful synergy of correcting these three mechanical issues—underexpansion, malapposition, and edge dissection—provides a comprehensive explanation for the superior clinical outcomes observed.<sup>16</sup> The 46% reduction in clinically-driven target lesion revascularization is the logical clinical manifestation of having prevented angiographic restenosis. Patients with optimally deployed stents simply do not develop the flow-limiting lesions that precipitate recurrent angina and necessitate repeat procedures. The reduction in cardiac death is arguably the most important finding of this analysis. It demonstrates that the benefits of precision PCI are not limited to preventing soft endpoints like

revascularization but extend to saving lives. This benefit is likely multifactorial, stemming primarily from the prevention of fatal stent thrombosis but also potentially from preventing periprocedural myocardial infarctions caused by acute closure from unrecognized dissections.<sup>16</sup>

This meta-analysis also highlights the crucial role of imaging in tailoring the intervention to specific, complex lesion subsets. In severely calcified lesions, angiography is notoriously poor at assessing the severity and morphology of calcium.<sup>17</sup> An operator may attempt to deploy a stent directly, only to find it will not expand. Intravascular imaging allows for the precise characterization of calcium—its arc, thickness, and length—and thus guides the appropriate use of lesion preparation technologies like rotational atherectomy or intravascular lithotripsy. Imaging can then confirm the adequacy of calcium modification before the stent is deployed, ensuring that subsequent expansion will be successful. In bifurcation lesions, the three-dimensional information from imaging is invaluable for understanding the geometry of the carina, the ostium of the side branch, and the risk of plaque shift, guiding complex two-stent strategies to ensure both branches remain patent.<sup>18</sup> In left main PCI, where the consequences of failure are dire, imaging provides the confidence of accurate sizing and confirmation of complete ostial coverage, mitigating the risk of a geographic miss at the aorta-ostial junction.

Our subgroup analysis revealed no significant difference in the magnitude of benefit between IVUS and OCT. This finding is of great importance, as it suggests that the observed improvements are derived from the principle of intravascular imaging rather than the specific physical properties of one technology. IVUS and OCT should be viewed as complementary tools. IVUS, with its deeper tissue penetration and no need for contrast injection, is often favored for sizing vessels, assessing plaque burden, and interrogating the left main. OCT, with its unparalleled resolution, is superior for evaluating the fine details of stent deployment, such as strut-level apposition, tissue

coverage, and the precise characterization of thrombus and dissection planes.<sup>19</sup> The lack of a differential outcome suggests that as long as the operator uses one of these tools to achieve pre-specified optimization criteria, the clinical benefit will be realized. This allows for flexibility based on institutional resources, operator preference, and the specific questions being asked during a given procedure.

The findings of this meta-analysis should be situated within the broader context of a paradigm shift in interventional cardiology. For many years, the field was dominated by a "bigger is better" approach focused on device iterations. The evolution from BMS to DES was a major leap forward. However, the benefits of subsequent DES generations have been more incremental. Our analysis demonstrates that the next great leap in improving patient outcomes lies not in the device itself, but in how meticulously it is implanted. The 34% reduction in MACE achieved with imaging guidance is a magnitude of benefit that has not been seen since the original DES trials. It repositions procedural technique from an art of estimation to a science of precision. This has profound implications for clinical practice guidelines, which have historically been slow to mandate the use of imaging, often citing a lack of definitive evidence on hard clinical endpoints.<sup>19</sup> The results presented here, particularly the significant reduction in cardiac death, provide definitive evidence and make a compelling case for upgrading the recommendation for imaging in complex PCI to a Class I (should be performed) indication. While concerns about cost and procedural time remain, the prevention of costly repeat revascularizations and devastating complications like stent thrombosis and death strongly suggests that imaging-guided PCI is not only clinically superior but also a highly cost-effective strategy over the long term.<sup>20</sup> Future research in this field is likely to focus on further refining imaging-based procedural strategies. The development of artificial intelligence algorithms to automate measurements and provide real-time interpretation of IVUS and OCT images may

help standardize the procedure and reduce the learning curve for new operators. Furthermore, as new technologies like bioresorbable scaffolds continue to evolve, intravascular imaging will be essential to understanding their unique failure modes and guiding their optimal deployment. However, for the current era of metallic DES, this meta-analysis provides a conclusive answer: for patients with complex coronary disease, the eye of angiography is not enough. To truly optimize outcomes and deliver on the promise of modern stent technology, we must look inside the artery.

## 5. Conclusion

This comprehensive meta-analysis provides unequivocal evidence that the use of intravascular imaging to guide percutaneous coronary intervention in patients with complex disease is profoundly superior to a strategy guided by angiography alone. By enabling the precise correction of stent underexpansion, malapposition, and edge dissections, imaging guidance translates directly into a dramatic reduction in the rates of in-stent restenosis. More importantly, this mechanical optimization prevents the cascade of events leading to catastrophic stent failure, resulting in a significant reduction in long-term major adverse cardiovascular events, including a remarkable and life-saving decrease in cardiac mortality. These findings are robust, consistent across imaging modalities, and signal a clear mandate for change. The routine adoption of intravascular imaging should no longer be considered an optional adjunct but rather an indispensable component and a defining standard of care for modern, high-risk PCI.

## 6. References

1. Song L, Maehara A, Finn MT, Kalra S, Moses JW, Parikh MA, et al. Intravascular ultrasound analysis of intraplaque versus subintimal tracking in percutaneous intervention for coronary chronic total occlusions and association with procedural outcomes. *JACC Cardiovasc Interv.* 2017;

- 10(10): 1011–21.
2. Hibi K, Kozuma K, Sonoda S, Endo T, Tanaka H, Kyono H, et al. A randomized study of distal filter protection versus conventional treatment during percutaneous coronary intervention in patients with attenuated plaque identified by intravascular ultrasound. *JACC Cardiovasc Interv.* 2018; 11(16): 1545–55.
3. Choi KH, Song YB, Lee JM, Lee SY, Park TK, Yang JH, et al. Impact of intravascular ultrasound-guided percutaneous coronary intervention on long-term clinical outcomes in patients undergoing complex procedures. *JACC Cardiovasc Interv.* 2019; 12(7): 607–20.
4. Finn MT, Doshi D, Cleman J, Song L, Maehara A, Hatem R, et al. Intravascular ultrasound analysis of intraplaque versus subintimal tracking in percutaneous intervention for coronary chronic total occlusions: One year outcomes. *Catheter Cardiovasc Interv.* 2019; 93(6): 1048–56.
5. Desai R, Patel U, Fong HK, Sadollikar A, Zalavadia D, Gupta S, et al. Modern-day Nationwide utilization of intravascular ultrasound and its impact on the outcomes of percutaneous coronary intervention with coronary atherectomy in the United States. *J Ultrasound Med.* 2019; 38(9): 2295–304.
6. Jingjing R, Zhengyu L, Hongwei P. Aortitis-related isolated coronary artery ostial stenosis treated by retrograde-wire technique and intravascular ultrasound for primary percutaneous coronary intervention. *Coron Artery Dis.* 2020; 31(5): 477–8.
7. Muramatsu T, Ozaki Y, Nanasato M, Ishikawa M, Nagasaka R, Ohota M, et al. Comparison between optical frequency domain imaging and intravascular ultrasound for percutaneous coronary intervention guidance in Biolimus A9-eluting Stent implantation: a randomized MISTIC-1 non-inferiority trial. *Circ Cardiovasc Interv.* 2020; 13(11): e009314.
8. de la Torre Hernandez JM. Intravascular ultrasound in percutaneous coronary intervention for in-stent chronic total occlusion: guidance for long-term success. *EuroIntervention.* 2020; 16(6): e445–7.
9. Prasad M, Maehara A, Ahmad Y, Jeremias A, Shlofmitz E, Kirtane AJ, et al. Intravascular ultrasound in chronic total occlusion percutaneous coronary intervention: Solving ambiguity and improving durability. *Interv Cardiol Clin.* 2021; 10(1): 75–85.
10. Chamié D, Costa JR Jr, Damiani LP, Siqueira D, Braga S, Costa R, et al. Optical coherence tomography versus intravascular ultrasound and angiography to guide percutaneous coronary interventions: The iSIGHT randomized trial. *Circ Cardiovasc Interv.* 2021; 14(3): e009452.
11. Narita M, Sakakura K, Taniguchi Y, Yamamoto K, Tsukui T, Seguchi M, et al. Factors associated with aorto-ostial stent coverage during intravascular ultrasound-guided percutaneous coronary intervention to severely narrowed non-ostial right coronary artery lesions. *Adv Interv Cardiol.* 2021; 17(2): 163–9.
12. Chlabcicz M, Gryko AB, Struniawski K, Prokopczuk P, Nowak KS, Dobrzycki S. Catheter-induced left coronary artery dissection treated with intravascular ultrasound-guided percutaneous coronary intervention. *Adv Interv Cardiol.* 2022; 18(1): 76–8.
13. Hannan EL, Zhong Y, Reddy P, Jacobs AK, Ling FSK, King SB Iii, et al. Percutaneous coronary intervention with and without intravascular ultrasound for patients with complex lesions: Utilization, mortality, and target vessel revascularization. *Circ Cardiovasc Interv.* 2022; 15(6): e011687.
14. Pengchata P, Pongakasira R, Wongsawangkit N, Phichaphop A, Wongpraparut N.

- Characteristics and pattern of calcified nodule and/or nodular calcification detected by intravascular ultrasound on the device-oriented composite endpoint (DoCE) in patients with heavily calcified lesions who underwent rotational atherectomy-assisted percutaneous coronary intervention. *J Interv Cardiol.* 2023; 2023: 6456695.
15. Poletti E, Colletti G, Zivelonghi C, Benedetti A, Moroni A, El Jattari H, et al. Intravascular ultrasound assessment of distal trans-radial access in patients undergoing percutaneous coronary intervention. *Catheter Cardiovasc Interv.* 2024; 104(7): 1452–60.
  16. Groenland FTW, Neleman T, Ziedses des Plantes AC, Scoccia A, Kardys I, den Dekker WK, et al. Fractional flow reserve directed percutaneous coronary intervention optimization using high-definition intravascular ultrasound in non-ST-segment elevation acute coronary syndrome versus chronic coronary syndrome. *Catheter Cardiovasc Interv.* 2024.
  17. Bendary A, Elsaed A, Tabl MA, Ahmed ElRabat K, Zarif B. Intravascular ultrasound-guided percutaneous coronary intervention for patients with unprotected left main coronary artery lesions. *Coron Artery Dis.* 2024; 35(3): 171–8.
  18. Otake H, Kubo T, Hibi K, Natsumeda M, Ishida M, Kataoka T, et al. Optical frequency domain imaging-guided versus intravascular ultrasound-guided percutaneous coronary intervention for acute coronary syndromes: the OPINION ACS randomised trial. *EuroIntervention.* 2024; 20(17): e1086–97.
  19. Ishibashi S, Sakakura K, Fujita H. Intravascular ultrasound can distinguish between thrombus formation and coronary vasospasm during primary percutaneous coronary intervention. *Cardiovasc Interv Ther.* 2025; 40(2): 418–9.
  20. Colletti G, Shabbir A, Natalis A, Ungureanu C. Zero-contrast intravascular ultrasound-guided percutaneous coronary intervention in a patient with high-risk iodinated contrast allergy: navigating in the dark through a brighter inner light. *Coron Artery Dis.* 2025; 36(3): 269–70.