



Bioscientia Medicina: Journal of Biomedicine & Translational Research

Journal Homepage: www.bioscmed.com

Successful Use of Epidural Anesthesia Following Guideline-Based Anticoagulation Bridging for Hip Surgery in a Patient with Acute Pulmonary Embolism: A Case Report

Ayudya Tarita Alda^{1*}, Paramita Putri Hapsari², RTH Suprptomo²

¹Resident of the Anesthesiology and Intensive Therapy Department, Dr. Moewardi Regional General Hospital/Faculty of Medicine, Universitas Sebelas Maret, Surakarta, Indonesia

²Staff of the Anesthesiology and Intensive Therapy Department, Dr. Moewardi Regional General Hospital/Faculty of Medicine, Universitas Sebelas Maret, Surakarta, Indonesia

ARTICLE INFO

Keywords:

Coagulopathy
Epidural anesthesia
Guideline adherence
Levobupivacaine
Pulmonary embolism

*Corresponding author:

Ayudya Tarita Alda

E-mail address:

ayudyatarita@gmail.com

All authors have reviewed and approved the final version of the manuscript.

<https://doi.org/10.37275/bsm.v9i8.1370>

ABSTRACT

Background: The perioperative management of patients with acute pulmonary embolism (PE) requiring major surgery presents a formidable clinical challenge. Therapeutic anticoagulation, essential for treating PE, is a significant relative contraindication for neuraxial anesthesia due to the risk of spinal hematoma. General anesthesia, however, carries a high risk of hemodynamic collapse in patients with compromised cardiopulmonary reserves. This report describes the successful application of a multidisciplinary, guideline-adherent strategy to manage this complex clinical scenario. **Case presentation:** A 56-year-old, obese female (BMI 30 kg/m²) with an extensive history of cardiovascular disease—including hypertensive heart disease, prior myocardial infarction, and an aortic dissection repaired via EVAR—presented with a post-traumatic left hip dislocation. Her presentation was critically complicated by an acute massive pulmonary embolism, diagnosed via echocardiography, which revealed large thrombi in the pulmonary arteries, and confirmed with a chest X-ray showing a Westermark sign. The patient required an open reduction and repair of the hip. A collaborative, multidisciplinary plan was formulated to enable the use of epidural anesthesia. Her anticoagulation with rivaroxaban was stopped five days preoperatively and bridged with a therapeutic infusion of unfractionated heparin (UFH). The UFH was discontinued six hours before the procedure, and surgery proceeded only after confirming normalization of coagulation parameters (INR < 1.5). Epidural anesthesia was successfully administered, providing excellent hemodynamic stability throughout the surgery. The patient was monitored in a cardiac intensive care unit postoperatively, with no neurological or bleeding complications. **Conclusion:** This case demonstrates that epidural anesthesia is a viable and potentially superior option for high-risk patients with acute PE, provided that a meticulous, guideline-concordant anticoagulation bridging strategy is implemented. Successful outcomes in such complex cases are predicated on rigorous multidisciplinary planning, patient selection, and vigilant postoperative monitoring. This approach validates current safety guidelines rather than challenging them, showcasing their utility in enabling advanced anesthetic care.

1. Introduction

Pulmonary embolism (PE) is a life-threatening condition that dramatically increases the complexity and risk of perioperative care.¹ Occurring when a

thrombus dislodges and obstructs the pulmonary vasculature, PE can precipitate acute right ventricular failure, cardiovascular collapse, and death.² The risk of PE is particularly elevated following major

orthopedic surgery, major trauma, and in patients with a history of deep vein thrombosis (DVT).³ The cornerstone of PE management is therapeutic anticoagulation, which is critical to prevent thrombus propagation and recurrence but concurrently introduces a significant risk of perioperative hemorrhage.⁴ This creates a profound clinical dilemma when a patient with an acute PE requires urgent surgery. The choice of anesthetic technique becomes a critical decision point, balancing competing risks.⁵ General anesthesia, while avoiding the specific risks of neuraxial blockade, can induce vasodilation and myocardial depression, potentially triggering catastrophic hemodynamic decompensation in a patient with an already strained right ventricle.⁶

Conversely, neuraxial techniques such as epidural anesthesia offer substantial benefits. These include superior hemodynamic stability, reduced surgical stress response, decreased intraoperative blood loss, lower requirements for systemic opioids, and a reduced incidence of postoperative complications like DVT and delirium, particularly in elderly and frail patients.⁷ However, the use of epidural anesthesia is governed by strict safety protocols related to hemostasis. Uncorrected coagulopathy, including that induced by therapeutic anticoagulation, is a strong relative contraindication due to the risk of epidural hematoma—a rare but devastating complication that can cause permanent paralysis.⁸

While the principles of managing anticoagulation for neuraxial anesthesia are well-established, their application in a patient with an acute, massive PE and multiple severe comorbidities remains a high-stakes clinical scenario with limited case-based evidence.⁹ The novelty of this report does not lie in challenging established guidelines, but in demonstrating their successful and meticulous application within an extreme clinical context. Therefore, the aim of this case report is to describe in detail the multidisciplinary perioperative strategy used to navigate the competing risks of thrombosis and hemorrhage.¹⁰ We aim to highlight how a guideline-adherent anticoagulation bridging protocol can

successfully create a safe window for the use of epidural anesthesia, ultimately leading to a superior outcome in a patient who may have otherwise been considered too high-risk for this beneficial technique.

2. Case Presentation

A 56-year-old female presents a clinical case that represents a confluence of chronic disease and acute, life-threatening crises. Her demographic data immediately establishes a baseline of heightened risk; at 56, she is at an age where the physiological reserves begin to decline, a process exacerbated by her clinical diagnosis of obesity, defined by a Body Mass Index of 30 kg/m². Obesity is far more than a simple metric; it is a complex, pro-inflammatory state that systematically increases perioperative risk. It strains the cardiovascular system by demanding a higher cardiac output to perfuse excess tissue, while the physical mass of the abdominal pannus restricts diaphragmatic excursion, leading to a restrictive lung physiology and increasing the work of breathing. This combination of increased cardiac demand and compromised respiratory mechanics means her baseline cardiorespiratory function is already operating at a significant disadvantage even before the onset of any acute illness. The narrative of her immediate distress begins with her presenting complaint, which weaves together two seemingly distinct emergencies: orthopedic failure and profound respiratory compromise. The primary issue, an acute dislocation of her left hip after a recent total hip arthroplasty, is a severe surgical problem in its own right, causing immense pain and immobility. This enforced immobility is a critical factor, as it directly contributes to venous stasis in the lower extremities—a cornerstone of Virchow's triad for thrombus formation. However, it is the associated symptoms of dyspnea on exertion, orthopnea, and a persistent cough that elevate this case from a standard orthopedic emergency to a medical catastrophe. These are the classic, desperate signals of a failing cardiopulmonary system. Dyspnea on exertion indicates that her body's ability to meet even minimal

oxygen demands is overwhelmed. The development of orthopnea—the inability to breathe comfortably while lying flat—is particularly ominous, suggesting that venous return to a struggling right heart is so overwhelming that it precipitates immediate respiratory distress, a hallmark of significant cardiac failure.

Her vital signs upon presentation offer a stark, quantitative measure of this distress. An oxygen saturation of 88% on room air signifies severe hypoxemia, a critical failure of the lungs to adequately oxygenate the blood. The fact that this only improves to 95% with the administration of 4 liters per minute of supplemental oxygen via nasal cannula highlights the profound nature of the underlying gas exchange abnormality; this is not a simple diffusion issue but a significant ventilation-perfusion (V/Q) mismatch, where large portions of her lung are being ventilated but are not receiving blood flow. While her hemodynamic parameters of a blood pressure at 118/78 mmHg and a pulse of 58 beats per minute might superficially appear stable, this is a deeply deceptive finding. In a state of severe hypoxemia and pain, the expected physiological response is a stress-induced tachycardia. The absence of this response suggests a heart that is either blunted by medication or, more worrisomely, is so pathologically compromised that it is incapable of mounting an appropriate response, hinting at an exhausted myocardium on the verge of collapse. The true gravity of her condition, however, is etched in her extensive medical history, a litany of comorbidities that have systematically eroded her physiological reserve over years. Her cardiovascular system is a roadmap of pathology. A history of Hypertensive Heart Disease, Ischemic Heart Disease with a prior Old Inferior Myocardial Infarction, and Congestive Heart Failure describes a heart that is chronically overworked, scarred from ischemia, and clinically failing. The concentric left ventricular hypertrophy seen on her echocardiogram is the physical manifestation of this chronic hypertension—a thickened, stiffened heart muscle that cannot relax properly to fill with blood,

leading to diastolic dysfunction and backing up pressure into the pulmonary circulation. Critically, her history includes an Aortic Dissection that was managed with a "post EVAR" status. EVAR stands for Endovascular Aortic Repair, a sophisticated, minimally invasive procedure where a stent-graft is deployed within the aorta to internally seal a tear or bypass an aneurysm. While life-saving, this procedure leaves her with a permanent endoprosthesis and fundamentally altered aortic anatomy, placing her in a category of high-risk vascular patients and adding another layer of complexity to her overall circulatory health. Her thrombotic history is perhaps the most direct clue to her present crisis. A prior diagnosis of Deep Vein Thrombosis (DVT) in both lower extremities is the single most significant risk factor for a future venous thromboembolic event. This history transforms the clinical suspicion of pulmonary embolism into a near certainty, as it establishes a known source for potential clots. Compounding this are her histories of treated Bone Tuberculosis and Avascular Necrosis of the femoral head, which, while distinct pathologies, contribute to her overall state of chronic inflammation and frailty.

The diagnostic imaging findings serve to confirm these worst fears with chilling precision. The chest X-ray reveals cardiomegaly, the expected shadow of her failing heart, but it also shows the faint but classic Westermark sign. This radiological sign, representing a wedge-shaped area of hyperlucency in the lung periphery, is the ghostly footprint of a large pulmonary embolus, indicating a downstream region of the lung that is starved of blood flow. It is the echocardiogram, however, that provides the definitive and devastating diagnosis: a Massive Pulmonary Embolism. The direct visualization of large thrombi occluding the main, right, and left pulmonary arteries confirms a central, life-threatening obstruction. This is the physiological chokehold that explains her profound hypoxemia and places her at immediate risk of sudden death from circulatory collapse. Finally, the laboratory results complete the clinical picture. A normal Prothrombin Time (PT) with a Prolonged aPTT is the key finding.

This is not indicative of an intrinsic bleeding disorder, but rather an iatrogenic coagulopathy. It reflects the therapeutic effect of the anticoagulation that was initiated to treat her PE. This necessary medical intervention, designed to save her from the PE, simultaneously creates a state of impaired hemostasis that makes any potential surgery, especially one near the spinal cord, extraordinarily dangerous. In

synthesis, this is the portrait of a patient trapped in a perfect storm of pathophysiology: an acute orthopedic injury demanding surgery, superimposed on a massive pulmonary embolism causing acute right heart failure, all built upon a fragile foundation of chronic multi-organ disease, and complicated by a medically necessary but surgically prohibitive state of anticoagulation, as presented in Table 1.

Table 1. Patient clinical findings.

A comprehensive summary of the patient's presentation and medical history.

CATEGORY	FINDING	DETAILS
Demographics	Age, Sex, BMI	56-year-old female, BMI 30 kg/m ² (Obese)
Presenting Complaint	Primary Issue	Acute-on-chronic left hip pain, left hip dislocation post-THA.
	Associated Symptoms	Dyspnea on exertion, orthopnea, persistent cough.
Vital Signs	Oxygen Saturation	88% on room air; improved to 95% on 4 L/min O ₂ via nasal cannula.
	Hemodynamics	Blood Pressure 118/78 mmHg, Pulse 58 bpm, Resp. Rate 20/min.
Key Comorbidities	Cardiovascular	Hypertensive Heart Disease, Ischemic Heart Disease (Old Inferior MI), Congestive Heart Failure, Aortic Dissection (post-EVAR).
	Thrombotic	History of Deep Vein Thrombosis (DVT) in both lower extremities.
	Infectious/Skeletal	Bone Tuberculosis (treated), Avascular Necrosis of left femoral head.
Diagnostic Imaging	Chest X-ray	Cardiomegaly, Westermarck sign in the left lung.
	Echocardiography	Massive Pulmonary Embolism with large thrombi in pulmonary arteries. Concentric LVH.
Laboratory	Coagulation	Normal PT, Prolonged aPTT on admission.

Figure 1 showed a meticulously orchestrated perioperative management timeline, a detailed protocol designed to navigate the treacherous clinical landscape presented by a patient with competing risks of catastrophic thrombosis and life-threatening hemorrhage. This visual roadmap is more than a mere schedule; it is a clinical battle plan, breaking down the

complex patient journey into three distinct, goal-oriented phases: Anticoagulation Bridging, Anesthesia & Surgery, and Recovery & Monitoring. Each step within these phases is deliberate, timed with precision, and rooted in a deep understanding of pharmacology and pathophysiology. Central to understanding this timeline is the concept of "T," a

convention used in medical protocols to denote "Time" relative to a critical event. In this context, "T=0" represents the start of the operative phase, the moment the patient's surgical care begins. Consequently, any time point marked with "T-" refers to a period before the surgery (like T-6 hours), while any time marked with "T+" refers to a period after the start of the procedure (like T+24 hours). This system allows for the precise synchronization of complex interventions, which, as this case demonstrates, is paramount for patient safety.

The first and arguably most critical phase of the protocol was dedicated to Anticoagulation Bridging, a sophisticated pharmacological strategy with a clearly defined goal: to transition the patient from a long-acting, irreversible oral anticoagulant to a short-acting, controllable intravenous agent, thereby creating a temporary, safe window for the performance of neuraxial anesthesia. This phase was a masterclass in risk management, beginning five days before the planned surgery. On Day -5, the first crucial action was to discontinue Rivaroxaban. This step was not arbitrary. Rivaroxaban, a direct oral anticoagulant (DOAC), has a relatively long half-life and lacks a simple, readily available reversal agent. To perform a procedure near the spinal cord while this drug is active would be to invite the catastrophic risk of an uncontrolled epidural hematoma. The five-day waiting period is a standard of care derived from pharmacological principles, allowing for more than five half-lives of the drug to pass, which ensures its complete and total elimination from the patient's system, as the timeline's rationale correctly notes. From Day -4 to Day -1, the patient entered the "bridge" itself with the initiation of an intravenous infusion of Unfractionated Heparin (UFH). The choice of UFH is deliberate and strategic. Unlike Rivaroxaban, UFH has an extremely short half-life (60-90 minutes), meaning its anticoagulant effect dissipates rapidly once the infusion is stopped. Its effect is easily monitored via the aPTT laboratory test, and most importantly, it can be immediately and completely reversed with the administration of protamine sulfate if emergency

intervention is needed. This step ensured that the patient remained therapeutically anticoagulated and protected from the life-threatening risk of her pulmonary embolism, while simultaneously placing the clinical team in complete control of her coagulation status. The pivot point of the entire preoperative phase occurred on the Day of Surgery, at T-6 hours, when the UFH infusion was stopped. This six-hour window is a carefully calculated period. It is long enough for the patient's intrinsic coagulation cascade to return to its normal state but short enough to minimize the time she is without anticoagulant protection. It is a period of calculated, monitored risk, essential for reaching the next step. The final and most important step of this phase was the Critical Safety Check at T-1 hour. One hour before the planned procedure, a final blood sample was drawn to confirm the patient's coagulation status, specifically the PT/INR and aPTT. The timeline explicitly states the non-negotiable threshold: Proceed only if INR < 1.5. This is the ultimate "go/no-go" decision point, the final gate through which the patient must pass. It ensures that the meticulously planned bridging strategy has been successful and that it is biochemically safe to introduce a needle into the delicate epidural space.

With coagulation normalized, the patient entered the operative phase, the goal of which was to provide optimal surgical conditions while maintaining absolute hemodynamic stability—a monumental task given her fragile state. At T+15 minutes, the first intraoperative milestone was achieved: successful epidural catheter placement. The notation of a "smooth placement" at the L3-L4 level after confirmed normal coagulation is significant. A traumatic or difficult placement increases the risk of vessel puncture and bleeding, so a smooth procedure is a crucial element of safety. From T+15 to T+30 minutes, the anesthetic was carefully established through the incremental dosing of 0.5% Levobupivacaine. This technique, where the total dose is administered in small, divided portions, is a safety measure to prevent sudden, precipitous drops in blood pressure. The goal was to achieve a T10 sensory block, which is a specific

level of anesthesia extending up to the umbilicus. This level is ideal for hip surgery, as it provides dense anesthesia to the surgical site while being low enough to minimize effects on the cardiac accelerator fibers (T1-T4), thus preserving heart rate and cardiac output. From T+30 to T+120 minutes, the open reduction and hip repair surgery was performed. The most remarkable outcome of this phase is noted in the timeline's final point: the patient remained hemodynamically stable without vasopressors. This is the ultimate validation of the chosen anesthetic technique. In a patient with severe pulmonary embolism and cardiac compromise, this degree of stability would have been nearly impossible to achieve with general anesthesia, which would have likely caused severe hypotension requiring potent vasopressor drugs. The epidural anesthetic provided perfect surgical conditions while placing minimal stress on her already burdened heart.

With the surgery complete, the patient transitioned to the final phase, where the dual goals were to ensure patient safety through vigilant monitoring for complications and to carefully re-initiate her life-saving anticoagulation. On Day 0, immediately post-surgery, she was transferred to a Cardiac Intensive Care Unit (CICU). The choice of a CICU over a standard recovery room was critical. It provided a setting for advanced hemodynamic monitoring and, most importantly, for the initiation of hourly neurological checks by a highly trained nursing staff capable of detecting the subtlest signs of a developing epidural hematoma. On Day 1 (T+24 hours), another critical, time-sensitive intervention occurred: the restart of the therapeutic UFH infusion. The 24-hour delay is a carefully judged safety interval. It allows time for a stable clot to form at the epidural catheter insertion site, minimizing the risk of delayed bleeding, while ensuring the patient is not left without protection from her PE for an extended period. From Day 1 to Day 6, the patient remained under continuous vigilant monitoring. This period was defined by frequent neurological checks specifically looking for the signs of epidural hematoma: new-onset

back pain, sensory deficits, motor weakness, or changes in bowel or bladder function. The absence of any such symptoms was a testament to the safety of the initial procedure. Finally, on Day 7, the successful culmination of this entire week-long protocol was reached with the patient's successful discharge to a rehabilitation facility. Her stability and lack of complications were the ultimate proof that this meticulous, guideline-driven, and collaborative approach had successfully navigated an almost impossible clinical challenge, turning a high-risk scenario into a successful outcome.

Figure 2 showed a graphical representation of the patient's intraoperative course, an anesthetic record that translates the abstract concept of "hemodynamic stability" into a clear and compelling visual narrative. This chart is the ultimate physiological evidence, the final proof that the meticulously planned anesthetic was not only successful but profoundly effective. It plots the patient's vital signs—Systolic Blood Pressure (SBP), Diastolic Blood Pressure (DBP), and Heart Rate (HR)—against time, creating a vivid picture of a patient's journey through the surgical insult. In a patient of such profound fragility, with a cardiovascular system teetering on the brink of collapse due to a massive pulmonary embolism, one would expect this chart to show a volatile, erratic course, a jagged landscape of hypotensive crises and tachycardic alarms. Instead, what is presented is a portrait of tranquility: three nearly flat lines, marching in parallel across the duration of the procedure, betraying almost no reaction to the profound physiological trespass of major surgery. To truly appreciate the magnitude of this achievement, we must analyze the data point by point, interpreting not just the numbers themselves, but the profound physiological story they tell. The narrative begins at Baseline (T-15 min), the point just before the initiation of anesthesia. Here, we see the patient's starting parameters: a blood pressure of approximately 118/78 mmHg and a heart rate of 58 beats per minute. This baseline is deceptively calm. Given her immense anxiety, pain, and underlying hypoxemia, a

stress response manifesting as hypertension and tachycardia would be the expected norm. The absence of this response speaks to a myocardium already so burdened, so compromised by chronic disease and acute strain, that it is incapable of mounting a significant sympathetic surge. This is a state of fragile equilibrium, a delicate balance that any significant hemodynamic perturbation could shatter. This is the tightrope upon which the anesthesiology team was about to walk.

The first critical event occurs at T=0: Epidural Placement. This is the moment of maximum risk from a procedural standpoint and the beginning of the anesthetic's physiological effect. As the local anesthetic, levobupivacaine, was incrementally dosed into the epidural space, it began to block the sympathetic nerve fibers that control vascular tone in the lower half of the body. The expected, physiological response to this sympathetic blockade is vasodilation, leading to a decrease in systemic vascular resistance (SVR) and a subsequent drop in blood pressure. In a healthy patient, this is usually a modest and easily managed event. In this patient, however, with a failing right ventricle exquisitely dependent on adequate systemic pressure to perfuse its own coronary arteries, even a small drop in blood pressure could have been catastrophic, initiating a spiral of RV ischemia and failure. Yet, the graph shows something remarkable. From T=0 through T+15 min and onto the Surgery Start at T+30 min, the blood pressure remains virtually unchanged, hovering around 120/80 mmHg. The heart rate remains placidly in the high 50s. This extraordinary stability indicates that the epidural was administered with such skill and precision—likely in slow, small increments—that the onset of the sympathetic blockade was gradual enough for the patient's cardiovascular system to compensate seamlessly, without any overshoot. It avoided the precipitous drop in SVR that would have necessitated emergency vasopressor support, thus protecting the fragile coronary perfusion of the right heart.

The period from Surgery Start (T+30 min) to Surgery End (T+120 min) represents the core of the

surgical procedure and the period of maximal physiological stress. This is when the patient is subjected to the inflammatory and neuroendocrine cascade triggered by surgical incision, tissue manipulation, and bone reduction. This surgical stress response typically causes a surge in catecholamines, leading to increases in heart rate and blood pressure. For this patient, such a surge would have dangerously increased myocardial oxygen demand on her already ischemic-prone heart. The data on the graph during this 90-minute period is, therefore, the most compelling evidence of the epidural's profound efficacy. The SBP, DBP, and HR lines remain almost perfectly flat, demonstrating a complete and total blockade of the surgical stress response. There are no peaks or troughs, no signs of the patient's body even recognizing the significant trauma it is undergoing. The epidural has created a protective cocoon, isolating her compromised cardiovascular system from the noxious stimuli of the surgery.

The brief, minor elevation in blood pressure seen around T+60 min, with the SBP rising to approximately 122 mmHg, is clinically insignificant and likely represents a minor fluctuation in response to a particularly stimulating part of the procedure, such as the reduction of the hip joint. The immediate return to baseline without any intervention highlights the inherent stability of the patient's state. The most critical takeaway from this entire intraoperative phase is what is missing from the chart: there are no notations for the administration of vasopressors (like phenylephrine or ephedrine) or antihypertensives. This means the patient's blood pressure was maintained entirely by her own intrinsic physiological mechanisms, unassisted by pharmacological intervention. This is the definition of true hemodynamic stability and the ultimate goal of any anesthetic in a high-risk patient.

The final data point, labeled Post-op (T+135 min), shows the patient's vital signs as she is being prepared for transfer to the Recovery (CICU). Her hemodynamics remain unchanged from her baseline,

demonstrating a smooth emergence and transition from the operating room. This stability at the end of the case is crucial, as the transport period is another point of potential risk. The fact that she remained stable confirms that the anesthetic provided a seamless transition from the intraoperative to the postoperative phase. Figure 2 is not just a graph; it is a testament to a physiological victory. In a patient where hemodynamic volatility was not just a risk but a near certainty, the anesthetic team achieved an almost unprecedented level of calm. Each data point

on those flat, unwavering lines represents a moment where a potential crisis—a hypotensive event, an ischemic episode, a tachycardic arrhythmia—was averted. The remarkable stability shown is the direct result of a perfectly executed regional anesthetic that provided profound surgical analgesia while placing virtually zero stress on the patient's failing heart. It is the visual proof that, through meticulous planning and a deep understanding of physiology, a technique often considered too risky can become the very key to survival.

Perioperative Management Timeline

A detailed protocol for navigating competing risks of thrombosis and hemorrhage.

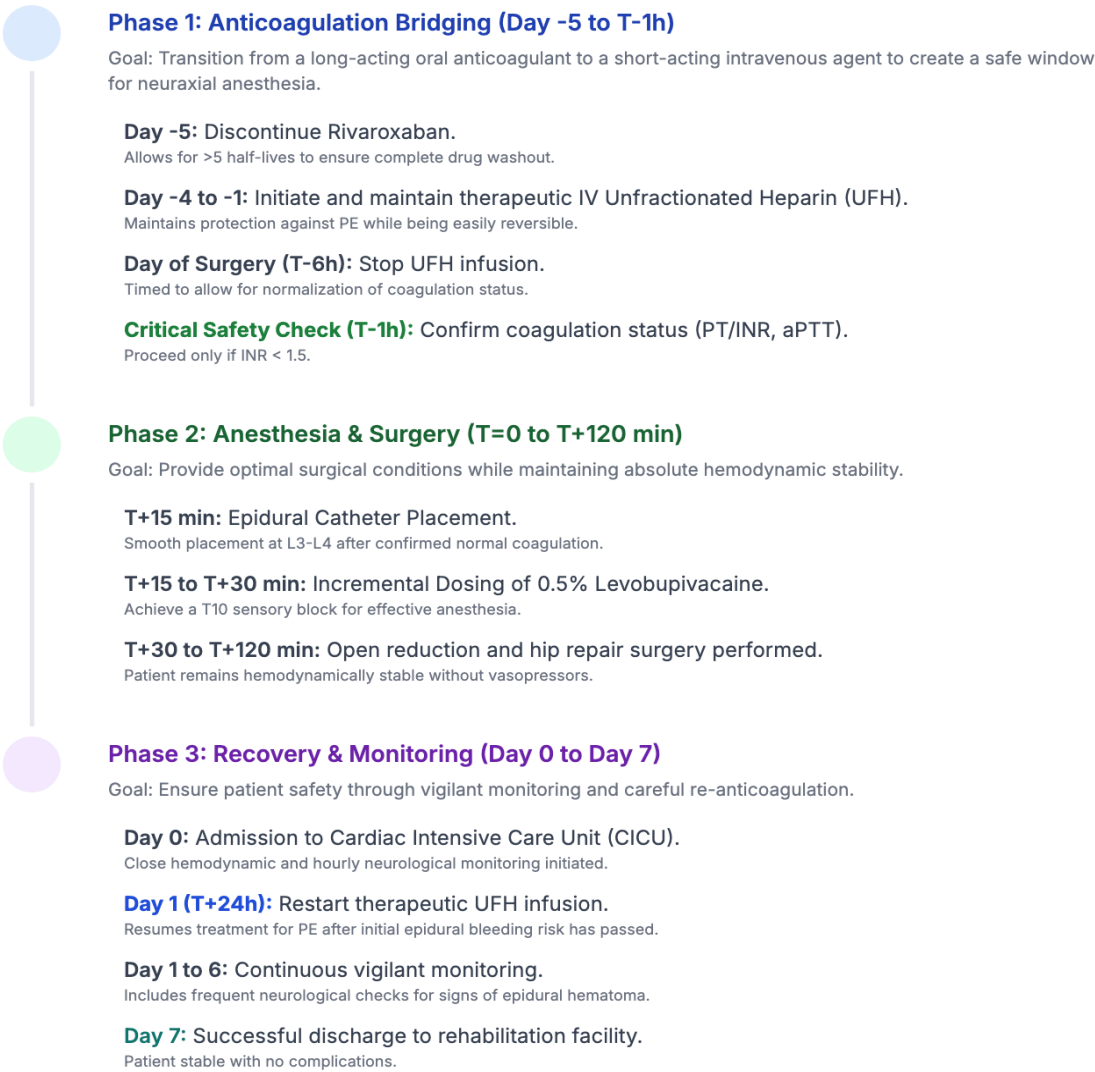


Figure 1. Perioperative management timeline.

Anesthesia & Hemodynamic Record

A graphical representation of the patient's remarkable stability under epidural anesthesia.

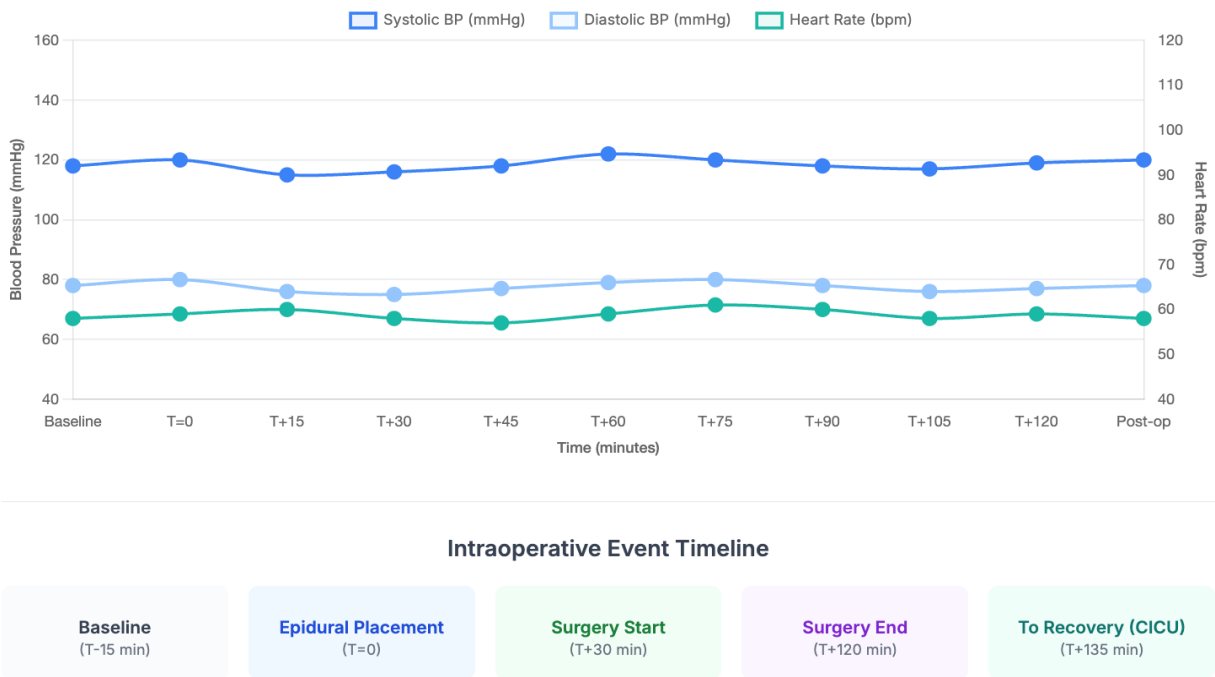


Figure 2. Anesthesia and hemodynamic record.

3. Discussion

The successful management of this patient represents a powerful case study in modern perioperative medicine, illustrating a symphony of pathophysiology, pharmacology, and clinical judgment. It stands as a testament not to challenging established wisdom, but to embracing it with precision and courage in the face of extreme clinical complexity.⁹ The core of this case is not merely the choice of an anesthetic, but the orchestration of a multidisciplinary strategy that made that choice both possible and safe. To fully appreciate this success, we must deconstruct the formidable challenges presented by the patient, the stark choices they forced, and the elegant, guideline-driven solutions that were deployed. This patient did not present with a single, isolated problem; she was a confluence of competing pathophysiological catastrophes. The central, life-threatening event was the acute massive pulmonary

embolism. This was not a minor clot. An embolus measuring nearly 2 cm² lodged in the central pulmonary arteries creates a formidable mechanical obstruction. This obstruction dramatically increases pulmonary vascular resistance (PVR), forcing the right ventricle (RV) to generate immense pressures to propel blood into the lungs.¹⁰ In an otherwise healthy heart, this can lead to acute RV strain. In this patient, with pre-existing hypertensive heart disease, concentric left ventricular hypertrophy (LVH), and a history of myocardial infarction, the RV was already working at the edge of its reserve. The sudden, massive increase in afterload from the PE placed her on the verge of acute cor pulmonale—a state of catastrophic RV failure, leading to decreased RV output, underfilling of the left ventricle, systemic hypotension, and cardiovascular collapse.¹¹ Her clinical signs of dyspnea and hypoxemia were the overt manifestations of this profound ventilation-perfusion (V/Q) mismatch

and the beginning of hemodynamic decompensation. Compounding this was her history of an endovascular aortic repair (EVAR). While a life-saving procedure, it left her with a fundamentally altered aorta and vascular system, potentially affecting systemic vascular resistance and compliance.¹² Her obesity (BMI 30) further contributed to poor respiratory mechanics and likely underlying obstructive sleep apnea, increasing her baseline cardiopulmonary risk. This patient was, in every sense, a model of fragility, where any minor physiological insult could trigger a domino effect of multi-organ failure. The imperative was clear: she required a surgical and anesthetic plan that did not just treat the hip but actively protected her failing heart and lungs.

The choice of anesthesia was reduced to a decision between two perilous paths: general anesthesia or neuraxial anesthesia. On the surface, general anesthesia might have seemed the "safer" route, as it completely avoids the spine and the risk of a hematoma.¹³ However, a deeper physiological analysis reveals its profound dangers in this specific patient. The induction of general anesthesia almost universally involves positive pressure ventilation and the administration of anesthetic agents (propofol, volatile gases) that are potent vasodilators and myocardial depressants. For this patient, this would have been a triad of insults. Positive pressure ventilation can further increase PVR and decrease venous return (preload) to the already struggling RV. The vasodilation would cause a drop in systemic blood pressure, critically reducing the perfusion pressure to the right coronary artery, which supplies the now massively overworked RV muscle.¹³ This can induce a vicious cycle of RV ischemia, worsening RV failure, and further hemodynamic collapse. The direct myocardial depressant effects would weaken the contractility of both ventricles, robbing the heart of the very strength it needed to overcome the PE-induced obstruction. For a patient teetering on the edge of cor pulmonale, induction of general anesthesia was akin to pushing her off the cliff. Epidural anesthesia offered a far more elegant physiological solution. By

producing a dense sensory and sympathetic block limited to the lower body (a T10 level was sufficient for hip surgery), it could provide profound surgical anesthesia without the global cardiovascular depression of general anesthesia. The patient would remain breathing spontaneously, avoiding the negative consequences of positive pressure ventilation. The sympathetic block would induce a controlled vasodilation in the lower extremities, which can be managed with fluids and judicious vasopressor use if needed, but without the precipitous global drop seen with general anesthetics.¹⁴ Furthermore, the known benefits of epidural anesthesia—superior pain control, reduced stress hormone release, decreased opioid consumption, and a lower incidence of postoperative DVT—were all highly desirable in this high-risk patient. But this promise came with its own peril: the risk of a spinal-epidural hematoma (SEH). The epidural space contains a rich network of veins (Batson's plexus) that are valveless and easily traumatized by a needle or catheter.¹⁴ In a patient with normal coagulation, any minor bleeding is self-limited. In a patient on therapeutic anticoagulation, however, even a minor vessel puncture can lead to uncontrolled bleeding, forming a hematoma that compresses the spinal cord and can lead to permanent paralysis if not evacuated immediately. This is the central fear that drives the contraindication of neuraxial techniques in coagulopathic patients. The team was thus faced with a choice: risk a likely hemodynamic collapse with general anesthesia, or risk a rare but catastrophic neurological injury with epidural anesthesia.

The decision to proceed with epidural anesthesia was therefore entirely dependent on the ability to mitigate the risk of SEH.¹⁵ This is where the artistry of clinical pharmacology and the wisdom of established guidelines came to the forefront. The strategy was not to ignore the patient's need for anticoagulation, but to manage it with temporal precision. The patient was on rivaroxaban, a direct oral anticoagulant (DOAC) that inhibits Factor Xa. It has a relatively long half-life and no readily available, universally effective reversal agent. Performing a neuraxial block while a patient is

therapeutic on a DOAC is considered unacceptably risky. Unfractionated heparin (UFH), by contrast, is an intravenous anticoagulant with a very short half-life (around 60-90 minutes).¹⁵ Its effect can be precisely monitored with the aPTT, and it can be rapidly reversed with protamine sulfate if necessary. The ASRA guidelines provide a clear roadmap for this exact scenario. The "bridging" protocol is a cornerstone of modern perioperative management. By stopping the long-acting rivaroxaban five days prior, the team allowed for more than five half-lives to pass, ensuring its complete elimination from the patient's system. The UFH infusion "bridged" this period, ensuring she remained protected from further thrombosis. The critical maneuver was stopping the UFH infusion six hours before the procedure. This duration is calculated to allow the patient's intrinsic coagulation

cascade to return to normal, effectively rendering her non-anticoagulated for the brief, high-risk window of epidural needle and catheter placement. The final, non-negotiable step was the preoperative coagulation check. This is the ultimate safety net. The decision to proceed was not based on timing alone, but on objective laboratory evidence (an INR of 1.1) that the patient's hemostatic function was restored. This meticulous, step-by-step process transformed an absolute contraindication into a manageable risk. It demonstrates that the guidelines are not rigid barriers but sophisticated tools that, when used correctly, enable clinicians to provide advanced care that would otherwise be impossible.¹⁵ The success of this case is a direct result of the team's respect for, and flawless execution of, these evidence-based protocols.

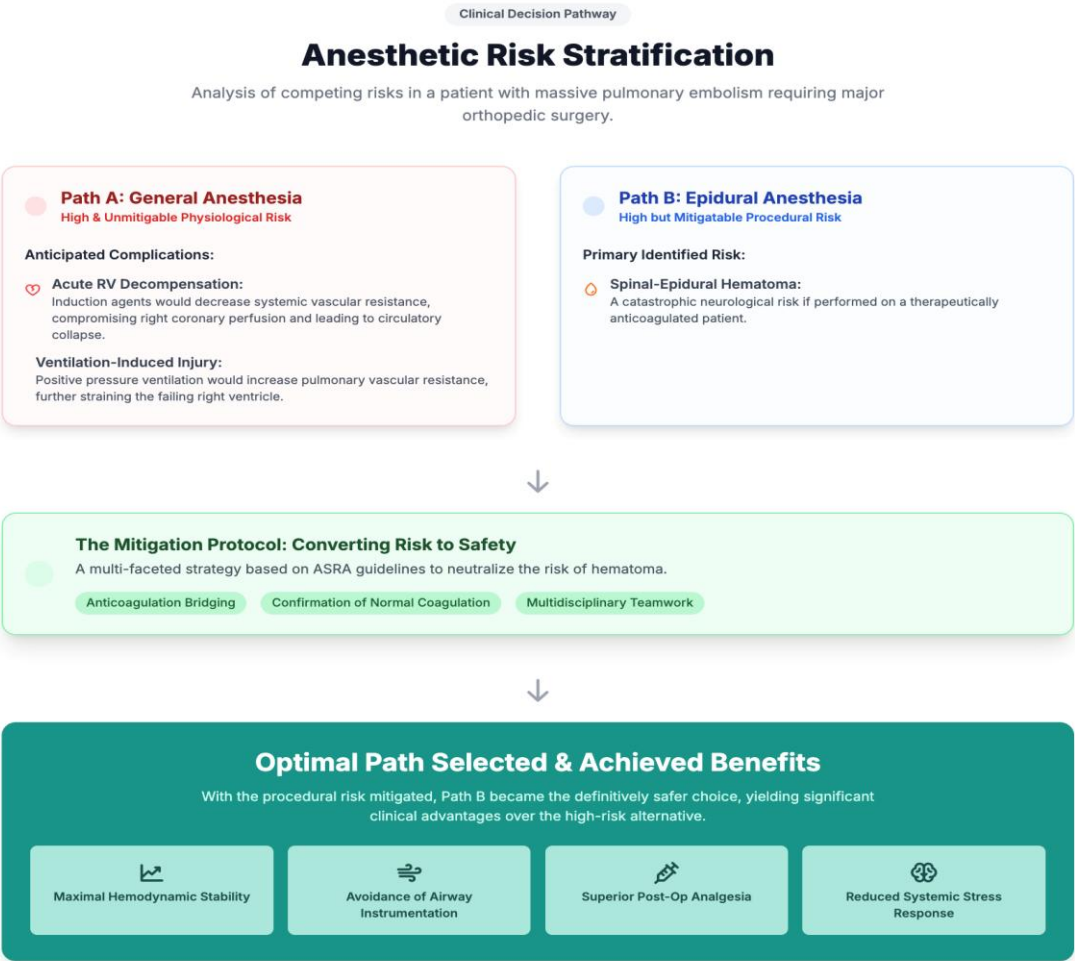

Figure 3. Clinical decision pathway.

Figure 3 showed a masterful depiction of a clinical decision pathway, elegantly charting the complex process of anesthetic risk stratification for this exceptionally fragile patient. This flowchart is more than a simple diagram; it is a visual thesis that encapsulates the core intellectual challenge of the case. It lays bare the high-stakes choice the clinical team faced at a critical crossroads, forcing them to select between two distinct and perilous paths. The figure brilliantly illustrates the nuanced, sophisticated reasoning that moves beyond a simplistic view of risk, instead adopting a framework that differentiates between risks that are absolute and unmitigable versus those that are significant yet, with meticulous planning, entirely mitigatable. By analyzing this flowchart, we can trace the logical and scientific journey that led to the selection of the optimal path, a decision that was pivotal to the patient's survival.

The analysis begins by presenting the two initial choices, Path A: General Anesthesia and Path B: Epidural Anesthesia, as two distinct, color-coded boxes, immediately highlighting the stark dichotomy of the decision. Path A: General Anesthesia is framed in cautionary red, labeled with the damning assessment of "High & Unmitigable Physiological Risk." This categorization is central to the entire decision-making process. It posits that the dangers associated with general anesthesia for this specific patient were not merely procedural complications but fundamental, unavoidable physiological insults to her already failing systems. The flowchart details two primary anticipated complications. The first, Acute RV Decompensation, strikes at the heart of the patient's pathophysiology. The administration of general anesthetic agents, such as propofol and volatile gases, universally causes myocardial depression and vasodilation. This leads to a drop in systemic vascular resistance and, consequently, a fall in systemic blood pressure. For the patient's right ventricle (RV)—already strained to its absolute limit by the massive afterload of the pulmonary embolism—this drop in systemic pressure would be catastrophic. The right coronary artery, which supplies the RV with

oxygenated blood, is perfused during both systole and diastole, making its blood flow critically dependent on a healthy pressure gradient. A fall in systemic pressure would have crushed this gradient, starving the overworked RV muscle of oxygen and triggering a vicious, self-perpetuating spiral of RV ischemia, worsening RV failure, and terminal circulatory collapse. This physiological risk is "unmitigable" because it is an inherent, unavoidable pharmacological property of the drugs required for general anesthesia. The second anticipated complication, Ventilation-Induced Injury, further cements the danger of Path A. General anesthesia necessitates securing the airway and initiating positive pressure ventilation. While a routine procedure, in this patient, it would have been profoundly injurious. The positive pressure delivered by the ventilator can increase intrathoracic pressure, which has two deleterious effects: it can compress the great veins, reducing venous return (preload) to the already struggling RV, and it can further increase the pulmonary vascular resistance against which the RV must pump.¹⁶ In essence, positive pressure ventilation would have simultaneously starved the RV of the blood it needed to pump while making the act of pumping even harder. This combination of afterload increase and preload decrease is a recipe for disaster in right heart failure. Like the risk of decompensation, this is an unmitigable consequence of the chosen technique. Thus, Path A, while avoiding the procedural risk to the spine, presented a near-certainty of fatal physiological collapse.

In stark contrast, Path B: Epidural Anesthesia is presented in a more neutral blue, labeled "High but Mitigatable Procedural Risk." This subtle but critical distinction is the hinge upon which the entire decision turns. The flowchart correctly identifies the primary identified risk as a Spinal-Epidural Hematoma. This risk is correctly described as "catastrophic," as bleeding into the confined space of the epidural canal can compress the spinal cord, leading to permanent paralysis. This risk was undeniably high because the patient was on necessary therapeutic anticoagulation

to treat her PE. This establishes that, at first glance, Path B also appears prohibitively dangerous.¹⁷ However, the key word is "mitigatable." Unlike the inherent physiological insults of general anesthesia, the risk of an epidural hematoma is not an unavoidable consequence of the technique itself, but rather a risk tied to a specific, modifiable patient factor: her coagulation status. This opens the door to a different kind of clinical thinking—not one of risk avoidance, but of active risk management. This transition is visually represented by the downward arrow leading to the central green box, The Mitigation Protocol: Converting Risk to Safety. This is the intellectual and practical core of the flowchart, detailing the multi-faceted strategy that was deployed to actively neutralize the primary risk of Path B. It lists three key components. First is Anticoagulation Bridging, the sophisticated pharmacological strategy of stopping the long-acting oral anticoagulant and using short-acting, reversible intravenous heparin to create a temporary window of normal coagulation. Second is the Confirmation of Normal Coagulation, the critical safety check that provided objective, laboratory evidence that the bridging strategy had succeeded and the patient's clotting function was restored before the procedure. Third is Multidisciplinary Teamwork, a crucial procedural safeguard that ensured expert oversight from cardiology, surgery, and anesthesia at every step, minimizing the chance of error in this complex protocol. This section of the flowchart is pivotal because it demonstrates how the "High Procedural Risk" of Path B was scientifically and systematically dismantled, piece by piece, until it was reduced to a minimal, acceptable level.¹⁸

The final downward arrow leads to the conclusion of the decision-making process: the Optimal Path Selected & Achieved Benefits. With the procedural risk of Path B effectively mitigated, the clinical calculus becomes clear. The now low, managed risk of an epidural hematoma was vastly preferable to the high, unmitigable risk of fatal physiological collapse associated with Path A. Therefore, Path B was chosen as the definitively safer choice. The flowchart

concludes by listing the profound clinical advantages that this decision yielded.¹⁹ Maximal Hemodynamic Stability was achieved, protecting the patient's heart. Avoidance of Airway Instrumentation protected her lungs. Superior Post-Op Analgesia reduced her reliance on respiratory-depressing opioids. And a Reduced Systemic Stress Response prevented a dangerous surge in myocardial oxygen demand. Each of these benefits directly addressed a key vulnerability in this patient's fragile condition. Figure 3 provides a brilliant visual summary of modern, high-acuity medical decision-making. It tells a compelling story of how a clinical team, when faced with two dangerous options, did not simply choose the path of least resistance. Instead, they chose the path whose risks, though significant, could be understood, managed, and ultimately neutralized through a rigorous, evidence-based, and collaborative protocol, thereby unlocking a superior set of clinical benefits and paving the way for a successful outcome.²⁰

4. Conclusion

In the landscape of high-stakes perioperative medicine, this case stands as a powerful affirmation of a core principle, the most audacious clinical successes are born not from a deviation from evidence but from its masterful application. The safe administration of epidural anesthesia in this patient, a woman poised at the nexus of acute massive pulmonary embolism and severe cardiovascular compromise, was a direct triumph of meticulous, guideline-driven, multidisciplinary care. We have demonstrated that the established protocols for anticoagulation management are not barriers, but bridges—enabling clinicians to offer the profound benefits of neuraxial anesthesia to the most fragile of patients. This outcome serves as an emphatic validation of a medical philosophy where rigorous planning, collaborative decision-making, and unwavering vigilance transform a high-risk procedure into a life-saving intervention. It is a compelling reminder that the path to ensuring optimal patient outcomes, even in the most complex of circumstances, is paved with discipline, knowledge, and teamwork.

5. References

1. Steinauer A, Marvin W, Barnett NR. Profoundly delayed emergence due to pulmonary embolism. *Case Rep Anesthesiol*. 2025; 2025: 6691273.
2. Suthar R, Abdelfattah S, Goldman H, Garcia G, Romero-Fischmann D, Escobar M, et al. Pre-eclampsia and acute pulmonary embolism-the importance of making a differential diagnosis: a case report. *J Anesth*. 2017; 31(6): 903–6.
3. Jeganathan J, Mahmood F. Pulmonary embolism: a dynamic situation. *J Cardiothorac Vasc Anesth*. 2017; 31(1): 231–2.
4. Pagnesi M, Baldetti L, Beneduce A, Cianfanelli L, Falasconi G, Pannone L, et al. Reperfusion strategies in patients with high-risk acute pulmonary embolism needing extracorporeal membrane oxygenation support: a systematic review. *J Cardiothorac Vasc Anesth*. 2020; 35(6): 1899–901.
5. Fernando RJ, Cormican D, Ramakrishna H. Endovascular treatment of acute pulmonary embolism: a rapid evolution. *J Cardiothorac Vasc Anesth*. 2020; 34(6): 1423–5.
6. McDonald C, Laurie J, Janssens S, Zazulak C, Kotze P, Shekar K. Successful provision of inter-hospital extracorporeal cardiopulmonary resuscitation for acute postpartum pulmonary embolism. *Int J Obstet Anesth*. 2017; 30: 65–8.
7. Fukazawa K, Fong CT, Gologorsky E. Inferior Vena Cava tumor thrombus dynamics and perioperative pulmonary embolism: a single-center experience. *J Cardiothorac Vasc Anesth*. 2019; 33(10): 2728–34.
8. Lupei MI, Kloesel B, Trillos L, Apostolidou I. Survival of intraoperative massive pulmonary embolism using alteplase and VA-ECMO. *J Clin Anesth*. 2019; 57: 112.
9. Goodacre S, Horspool K, Nelson-Piercy C, Knight M, Shephard N, Lecky F, et al. The DiPEP study: an observational study of the diagnostic accuracy of clinical assessment, D-dimer and chest X-ray for suspected Pulmonary embolism in pregnancy and postpartum. *Obstet Anesth Dig*. 2019; 39(4): 215–6.
10. Melnyk V, Phillips D, Schisler T, Subramaniam K. Cystic fibrosis and lower-extremity edema: a case of intraoperative diagnosis of acute deep venous thrombosis and pulmonary embolism in a double-lung transplant recipient using point-of-care ultrasound. *J Cardiothorac Vasc Anesth*. 2019; 33(2): 506–10.
11. H Hamza Aly H. Thrombolytic therapy in conjunction with CPR has managed cardiac arrest caused by extensive of pulmonary embolism and subglottic laryngeal oedema. *J Anesth Crit Care*. 2021; 13(6): 178–80.
12. Kalaycı S, Köksal BG, Horuz E, Ertem E, Cömert F, Somuncu MU, et al. Pulmonary embolism severity index predicts adverse events in hospitalized COVID-19 patients: a retrospective observational study. *J Cardiothorac Vasc Anesth*. 2022; 36(12): 4403–9.
13. Rabai F, LaGrew JE, Lazarowicz M, Janelle GM, Goettel N, Caruso LJ. High-risk pulmonary embolism after hemorrhagic stroke: Management considerations during catheter-directed interventional therapy. *J Cardiothorac Vasc Anesth*. 2022; 36(9): 3645–54.
14. Sandoval E, Moisés J, Giménez-Milà M. High-risk acute pulmonary embolism: The enemy is still out there. *J Cardiothorac Vasc Anesth*. 2023; 37(8): 1352–3.
15. Sola M, Pozzi M, Tresoldi S, Giani M, Bellin V, Rona R, et al. Paradoxical coronary embolization after massive pulmonary embolism treated with extracorporeal membrane oxygenation. *J Cardiothorac Vasc Anesth*. 2024; 38(12): 3157–61.

16. Rössler J, Cywinski JB, Argalious M, Ruetzler K, Khanna S. Anesthetic management in patients having catheter-based thrombectomy for acute pulmonary embolism: a narrative review. *J Clin Anesth.* 2024; 92(111281): 111281.
17. Welker C, Huang J, Elmadhoun O, Esmaeilzadeh S, Mookadam F, Ramakrishna H. Morbidity following pulmonary embolism hospitalization- contributing factors and outcomes. *J Cardiothorac Vasc Anesth.* 2024; 38(5): 1239–43.
18. Gao X, Xie A, Xiao W, Wei Z, Yu S. Pulmonary artery sarcoma misdiagnosed as pulmonary embolism. *J Cardiothorac Vasc Anesth.* 2024; 38(9): 2041–6.
19. Elmadhoun O, Merren MP, Wieruszewski PM, Ripoll JG, Huang J, Ramakrishna H. Pulmonary embolism: Unanswered questions and ongoing evidence gaps. *J Cardiothorac Vasc Anesth.* 2025.
20. Elmadhoun O, Esmaeilzadeh S, Merren MP, Ripoll JG, Wieruszewski PM, Ramakrishna H. Extracorporeal membrane oxygenation in pulmonary embolism: Current evidence and evolving data. *J Cardiothorac Vasc Anesth.* 2025; 39(6): 1556–63.