



Bioscientia Medicina: Journal of Biomedicine & Translational Research

Journal Homepage: www.bioscmed.com

Pancreas-Sparing Mucosectomy for a Complex Gastric Duplication Cyst: A Case Report

Filza Rifqi Aufa Aslam^{1*}, Ismar Ibrahim², Tubagus Odih Rhomdani Wahid², Andrea Valentino³, Salamullah⁴, Indrajaya⁵

¹Department of Surgery, Faculty of Medicine, Universitas Riau, Riau, Indonesia

²Division of Pediatric Surgery, Department of Surgery, Faculty of Medicine, Universitas Riau, Riau, Indonesia

³Division of Neurosurgery, Department of Surgery, Faculty of Medicine, Universitas Riau, Riau, Indonesia

⁴Division of Oncology Surgery, Department of Surgery, Faculty of Medicine, Universitas Riau, Riau, Indonesia

⁵Division of Urology Surgery, Department of Surgery, Faculty of Medicine, Universitas Riau, Riau, Indonesia

ARTICLE INFO

Keywords:

Congenital anomaly
Gastric duplication
Mucosectomy
Pancreas
Pediatric surgery

*Corresponding author:

Filza Rifqi Aufa Aslam

E-mail address:

filzarifqi@gmail.com

All authors have reviewed and approved the final version of the manuscript.

<https://doi.org/10.37275/bsm.v9i9.1371>

ABSTRACT

Background: Gastric duplication (GD) is a rare congenital anomaly, representing 2–9% of all gastrointestinal duplications. These embryologic abnormalities are typically managed by complete surgical resection due to the risk of complications, including malignancy. However, this standard approach becomes perilous when the duplication cyst is intimately adherent to vital organs. We present a case where a large gastric duplication cyst was inseparable from the pancreas, necessitating a deviation from standard management. **Case presentation:** An 8-month-old female infant presented with a four-month history of non-bilious vomiting and progressive abdominal distension. A palpable, cystic, 8x5 cm mass was identified in the left upper abdomen. Abdominal ultrasound revealed a loculated, septated cystic lesion, and a barium study demonstrated a significant filling defect on the greater curvature of the stomach. Initial management was delayed as the family sought alternative medicine. Surgical exploration revealed a large gastric duplication cyst arising from the greater curvature, which was found to be densely adherent to the body and tail of the pancreas. To avoid catastrophic pancreatic injury, a complete resection was abandoned in favor of a pancreas-sparing mucosectomy. The entire mucosal lining of the duplication was excised, and the shared muscular wall was preserved and repaired. Postoperatively, the patient had a transient ileus but recovered well, with complete resolution of symptoms. At an 11-day follow-up, she was thriving, feeding well, and had gained significant weight. Histopathology confirmed a benign gastric duplication cyst. **Conclusion:** This case highlights that for complex gastric duplication cysts where resection would endanger vital structures, complete mucosal excision is a safe, effective, and organ-preserving surgical alternative. This technique successfully mitigates the risks of both the untreated anomaly and iatrogenic surgical complications, underscoring the importance of surgical judgment and adaptability in managing rare congenital anomalies.

1. Introduction

The alimentary tract, a marvel of embryological development, is occasionally host to rare and enigmatic congenital abnormalities known as duplication cysts.¹ First systematically described by Ladd in 1934, these are spherical or tubular

structures that possess a layer of smooth muscle and are lined with gastrointestinal mucosa, existing in intimate contact with a segment of the normal digestive tract. They can manifest anywhere from the esophagus to the rectum, but their occurrence is not uniform. The ileum is the most common site,

accounting for approximately 35% of all cases.²

At the upper end of the tract lies the stomach, where these anomalies are particularly uncommon. Gastric duplications (GDs) are among the rarest of these lesions, constituting a mere 2–9% of all alimentary tract duplications.³ Their overall incidence is estimated to be just 17 cases per million people, making them a clinical curiosity that many surgeons may never encounter. These lesions are most frequently cystic rather than tubular and are typically found along the greater curvature of the stomach. While they can be diagnosed in adulthood, GDs are predominantly a disease of infancy and early childhood, with most cases presenting within the first year of life.⁴ A striking and as-yet-unexplained female predominance has been reported in the literature, with some sources noting a female-to-male ratio as high as 8:1.

The precise embryological misstep that leads to the formation of a gastric duplication remains a subject of debate, with several compelling theories proposed. Bremer's theory suggests a failure of recanalization, where vacuoles that form to canalize the solid epithelial cord of the primitive gut fail to coalesce properly, leaving a sequestered duplication.⁵ The "split notochord" theory posits that an abnormal adhesion between the endoderm and notochord causes a splitting of the developing gut as the notochord separates. Other hypotheses include the persistence of embryonic diverticula, incomplete twinning events, and even intrauterine vascular accidents. These diverse theories reflect the heterogeneous nature of these lesions.⁶

The clinical presentation of gastric duplication is notoriously vague and often overlaps with more common pediatric ailments, making diagnosis a significant challenge. Infants may present with non-specific symptoms such as chronic vomiting, abdominal pain, failure to thrive, or weight loss. A large cyst can act as a space-occupying lesion, leading to a palpable abdominal mass or causing gastric outlet obstruction.⁷ In some cases, the ectopic gastric mucosa within the cyst can secrete acid, leading to

peptic ulceration, bleeding, perforation, or fistula formation into adjacent organs. This diagnostic ambiguity demands a high index of suspicion from the astute clinician.

Diagnosis relies heavily on imaging. Abdominal ultrasonography is often the initial modality of choice, capable of revealing a thick-walled, anechoic or hypoechoic cystic mass. A key, though not always present, sonographic feature is the "double-wall" or "gut signature" sign—an inner hyperechoic layer corresponding to the mucosa/submucosa and an outer hypoechoic layer representing the muscularis propria.⁸ Advanced imaging, such as computed tomography (CT) or magnetic resonance imaging (MRI), can further delineate the cyst's anatomy and its relationship to surrounding structures. A barium contrast study may show a characteristic filling defect caused by extrinsic compression from the non-communicating cyst on the gastric lumen.

The definitive treatment for gastric duplication, once diagnosed, is unequivocal: complete surgical resection. This recommendation stands even for asymptomatic or incidentally discovered lesions. The rationale is twofold. First, it eliminates the risk of developing future complications such as obstruction, bleeding, or perforation. Second, and more critically, it addresses the small but significant risk of malignant transformation within the cyst. A range of malignancies, including adenocarcinoma, neuroendocrine tumors, and gastrointestinal stromal tumors (GIST), have been reported to arise within these duplications, making their complete removal a crucial prophylactic measure.⁹

However, the mandate for complete resection presumes that the duplication is anatomically distinct and can be safely excised without harming adjacent organs. The literature is less clear on the optimal management strategy when a duplication cyst is densely and inseparably fused to a vital structure. This presents a formidable surgical dilemma: does the surgeon risk a potentially devastating iatrogenic injury to resect the benign cyst, or is there a safer, organ-preserving alternative? The novelty of this report does

not lie merely in the documentation of a rare disease, but in its detailed account of a successful pancreas-sparing mucosectomy for a cyst congenitally fused to the pancreas—a clinical scenario that forces a departure from the standard of care.¹⁰ Therefore, the aim of this study is threefold: first, to present a comprehensive narrative of this rare and challenging case, from its initial presentation to its successful resolution; second, to provide a detailed technical description of the mucosectomy as a safe and effective alternative to a high-risk resection; and third, to discuss the underlying embryological and pathophysiological rationale that makes this approach not merely a compromise, but the optimal surgical solution in such circumstances. Through this report, we intend to provide a valuable data point and a well-reasoned surgical strategy for fellow surgeons who may one day face a similar dilemma in the operating room.

2. Case Presentation

An 8-month-old female infant presented as a case study in diagnostic convergence, where a constellation of historical, physical, and investigative findings meticulously painted a portrait of a rare and challenging congenital anomaly. The clinical journey of this patient, from the onset of her symptoms to the definitive preoperative diagnosis, encapsulates a narrative of progressive physiological distress stemming from a silent embryological error. Her story begins four months prior to her admission to a tertiary care center, at the tender age of four months, with the seemingly innocuous onset of non-bilious, post-prandial vomiting. This initial symptom, while concerning, was the first subtle signal of a significant underlying pathology. The vomiting's non-bilious character was a crucial clue, localizing the problem to a point proximal to the ampulla of Vater, suggesting a gastric outlet obstruction rather than a more distal intestinal issue. The infant's initial evaluation at a local hospital revealed a small, "marble-sized" tumor in her upper abdomen via ultrasound. However, confronted with the prospect of surgery, the family

chose to pursue alternative medicine, a decision that unfortunately led to a critical four-month delay in definitive treatment. During this fateful interval, the underlying pathology was not static; it was insidiously progressive. The pathophysiology of a non-communicating gastric duplication cyst, as this lesion was later identified to be, provides a clear explanation for this deterioration. These cysts are lined with gastric-type mucosa that carries out its physiological duty: it secretes fluid. In a closed, non-communicating space, this relentless, drop-by-drop secretion behaves like a slowly inflating balloon, causing the cyst's volume and internal pressure to steadily increase over weeks and months. This process was mirrored in the infant's clinical decline. The vomiting worsened in frequency and force, her nutritional intake became severely compromised, and the abdominal mass, once the size of a marble, grew alarmingly to the size of a "chicken egg" as described by her parents. This tangible growth was the external manifestation of the months-long secretory process occurring within her abdomen, a process that ultimately culminated in the aspiration of 150 cc of clear fluid during surgery.

Upon her eventual admission to the tertiary care pediatric surgical unit, the infant presented as a frail and chronically ill child, bearing the clear and cumulative signs of prolonged undernutrition and systemic stress. Her physical examination was profoundly illustrative of her condition. The abdomen was visibly distended, particularly in the upper quadrants, and close observation revealed the striking sign of visible intestinal peristalsis. This visible, wave-like motion across her abdominal wall was the stomach's futile, hypertrophic attempt to overcome the significant mechanical blockade it was laboring against. Auscultation confirmed this struggle with the presence of hyperactive bowel sounds, another hallmark of a body attempting to force contents past an obstruction. The centerpiece of the physical exam was the palpation of a large, well-defined mass in the epigastric and left umbilical regions, measuring approximately 8 by 5 centimeters. Its consistency was described as cystic and rubbery, and critically, it was

fixed to the underlying structures, a feature suggesting a congenital adherence rather than a freely mobile lesion. This fixed nature was a physical clue to the embryological fusion that would later be confirmed in the operating room, where the cyst was found to be congenitally inseparable from the pancreas. The laboratory findings provided a quantitative look into the systemic toll of this condition. A hemoglobin level of 8.7 g/dL indicated a moderate anemia. This was likely a multifactorial anemia of chronic disease, driven by the persistent inflammatory state and compounded by poor nutritional intake of iron and other hematopoietic precursors due to four months of significant vomiting. A marked thrombocytosis, with a platelet count of $615 \times 10^3/\mu\text{L}$, and leukocytosis, with a white blood cell count of $13.95 \times 10^3/\mu\text{L}$, were not indicative of a primary infection but rather a robust systemic inflammatory response. This chronic inflammation was likely a direct result of the continuous tissue stretching, pressure ischemia on the cyst wall, and the possible microscopic leakage of inflammatory mediators from the tense, fluid-filled structure. This inflammatory state was further confirmed by an elevated C-reactive protein (CRP) of 11.3 mg/L, a sensitive biomarker for inflammation and tissue stress. A mildly elevated Alanine Aminotransferase (AST) of 81 U/L could be attributed to the overall systemic stress or perhaps mild hepatic parenchymal pressure from the large adjacent mass. The serum potassium of 5.4 mEq/L was slightly elevated, a finding that, in the context of significant systemic illness, may reflect a degree of metabolic acidosis and cellular stress causing a shift of intracellular potassium into the bloodstream. Collectively, these blood work abnormalities told a story of a body under siege from a chronic inflammatory process and suffering from the metabolic consequences of a severe, unremitting gastric outlet obstruction.

Imaging studies served to visualize the pathology and define its anatomical characteristics. The abdominal ultrasound, often the initial modality of choice in such cases, was highly informative. It

revealed a large, loculated, and septated cystic lesion, but most importantly, it demonstrated features highly suggestive of the "gut signature" or "double-wall" sign. This specific sonographic finding—an inner hyperechoic layer representing the mucosa and submucosa and an outer hypoechoic layer representing the muscularis propria—is a key diagnostic feature that distinguishes a true enteric duplication cyst from other intra-abdominal cystic lesions. It essentially confirms that the cyst wall has a layered structure identical to that of the normal gastrointestinal tract. To further delineate the anatomy and its functional impact, a barium fluoroscopy study was performed. This dynamic imaging test demonstrated a large extrinsic filling defect along the greater curvature of the stomach. The ingested barium sulfate filled the true stomach, but its contour was significantly indented from the outside by the large, non-communicating mass. This finding unequivocally confirmed both the location of the pathology, arising from the stomach wall, and its nature as a non-communicating cyst that was causing significant mechanical compression and, therefore, obstruction of the gastric lumen. In synthesizing this wealth of information—the classic history of progressive non-bilious vomiting; the physical findings of a frail infant with a large, fixed upper abdominal mass and signs of obstruction; the laboratory evidence of chronic inflammation and metabolic stress; and the definitive imaging findings from both ultrasound and barium fluoroscopy—the clinical team arrived at a confident and conclusive preoperative diagnosis. The evidence pointed overwhelmingly to a large, non-communicating gastric duplication cyst arising from the greater curvature of the stomach, which was causing a significant and symptomatic gastric outlet obstruction, fully accounting for the infant's severe clinical presentation. This comprehensive clinical summary, integrating every facet of the patient's history, examination, and diagnostic workup, is what was meticulously compiled and presented in figure 1.

Comprehensive Clinical Summary on Admission

An integrated dashboard detailing the patient's history, key examination findings, and conclusive diagnostic results.

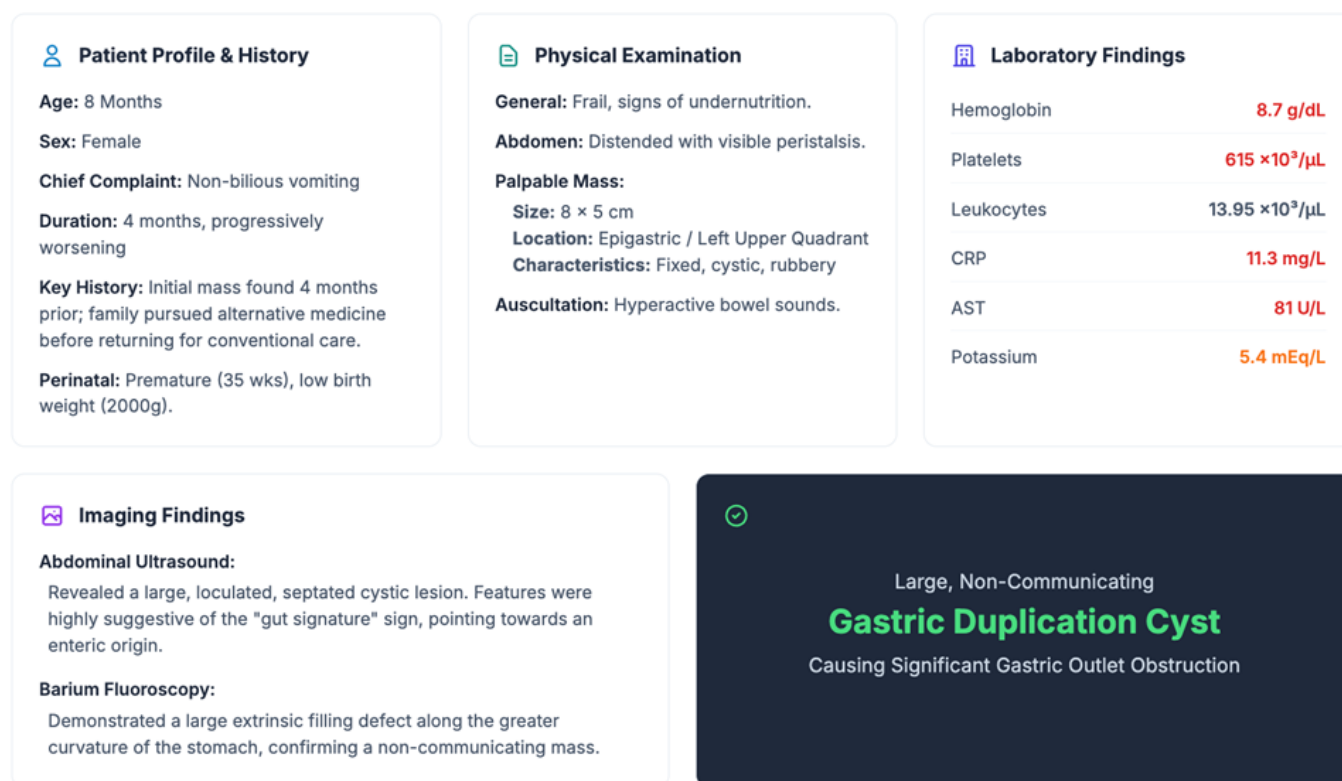


Figure 1. Comprehensive clinical summary on admission.

Figure 2 showed a concise yet deeply informative summary of the patient's preoperative and operative management, outlining the critical steps taken to navigate a rare and anatomically complex surgical challenge. The figure is divided into two key temporal phases: the initial stabilization that prepared the vulnerable infant for a major procedure, and the pivotal surgical intervention itself, where astute intraoperative judgment led to a successful departure from standard surgical doctrine. Each point on this visual timeline, while brief, represents a deliberate clinical decision rooted in a deep understanding of the patient's precarious physiological state and the underlying pathophysiology of her condition. The first phase, "Pre-operative Stabilization," details the essential measures undertaken to fortify the patient before she could safely undergo surgery. This was not

a routine preparation; it was a critical resuscitation for an 8-month-old infant described as frail and bearing the clear signs of chronic illness and undernutrition. The first listed intervention, the administration of intravenous (IV) fluids for rehydration, directly addressed the consequences of her four-month history of non-bilious, progressively worsening vomiting. This chronic fluid loss, coupled with compromised nutritional intake, would have left her significantly volume-depleted, making her susceptible to hemodynamic instability under anesthesia. The second measure, the correction of anemia with a packed red blood cell transfusion, was a direct response to laboratory findings that revealed a hemoglobin level of 8.7 g/dL. This anemia was likely multifactorial, stemming from a combination of poor nutritional intake of essential hematopoietic

precursors like iron and the systemic effects of chronic inflammation, a condition known as anemia of chronic disease. Her blood work supported this inflammatory state with evidence of leukocytosis and thrombocytosis. By transfusing packed red blood cells, the medical team aimed to restore her oxygen-carrying capacity, a vital step to ensure adequate tissue perfusion during the significant physiological stress of a major abdominal operation. The third component of stabilization was the administration of prophylactic antibiotics, specifically Ceftriaxone. This was a crucial preventative measure in a patient who was not only nutritionally compromised but also in a state of chronic systemic inflammation, making her more susceptible to infection. The surgery involved opening the gastrointestinal tract, and prophylactic antibiotics were essential to minimize the risk of a surgical site infection or postoperative sepsis. Together, these three interventions—rehydration, transfusion, and antibiotic prophylaxis—formed a foundational triad of care that transformed the patient from a high-risk, physiologically depleted infant into a candidate who could safely withstand the necessary surgical cure.

The second, and most dramatic, phase detailed in the figure is the "Surgical Intervention," which took place on December 5th, 2022. The narrative begins with an exploratory laparotomy, the standard surgical approach to directly visualize and address an intra-abdominal pathology. The initial goal, aligned with established surgical doctrine for gastrointestinal duplications, was unequivocal: complete surgical resection. This doctrine is built upon the dual imperatives of eliminating the risk of future complications like obstruction or bleeding and, more critically, removing the tissue to prevent the small but significant risk of malignant transformation into cancers like adenocarcinoma. However, the figure highlights that the surgical plan was "critically adapted based on intraoperative findings," a statement that pivots the narrative from routine procedure to a moment of profound surgical dilemma. This dilemma is explicitly defined in the sub-panel

labeled "Critical Intraoperative Finding." Here, the surgeons discovered that the gastric duplication cyst was "densely adherent and inseparable from the body and tail of the pancreas". This was not a simple inflammatory adhesion that could be bluntly or sharply dissected away; it was a congenital fusion, an embryological event where the two structures developed in such close proximity that they became inextricably fused, likely sharing a common seromuscular coat. This intraoperative discovery instantly rendered the standard plan of complete resection perilous. The text of the study eloquently describes the pancreas as a "notoriously unforgiving organ," lacking a tough protective capsule and being rich in potent digestive enzymes. Attempting to "shave" the cyst wall off the fragile pancreatic parenchyma would have carried an unacceptably high risk of catastrophic iatrogenic injury. Potential complications included a pancreatic fistula leaking corrosive enzymes into the abdomen, the formation of a pseudocyst, the induction of acute life-threatening pancreatitis, or uncontrollable hemorrhage from the complex vasculature supplying the organ. Faced with this formidable challenge, the surgical team made the crucial judgment to abandon the standard resection, prioritizing the patient's immediate safety over rigid adherence to dogma.

This decision led to the "paradigm shift" detailed under "Procedure: Pancreas-Sparing Mucosectomy". This elegant solution addressed the fundamental problems posed by the duplication cyst without endangering the pancreas. The first step was the decompression of the cyst, during which 150 cc of clear fluid was aspirated. This action immediately relieved the mass effect that was causing the gastric outlet obstruction and physically confirmed the pathophysiology of a non-communicating cyst relentlessly filling with its own secretions. The core of the innovative procedure was the next step: the meticulous excision of the entire mucosal lining, a technique known as mucosectomy. This masterstroke surgically "deactivated" the duplication cyst. By removing the mucosal lining, the surgeons removed

the secretory engine, guaranteeing that the cyst could never again accumulate fluid and cause obstruction. Simultaneously, and most importantly, they removed the only tissue layer capable of malignant transformation, thus satisfying the oncological imperative that underpins the doctrine of complete resection. The final steps involved preserving the shared muscular wall, leaving it in situ to act as a protective barrier for the underlying pancreas, and repairing the resulting defect in the true stomach to restore its integrity. This pancreas-sparing

mucosectomy was not a compromise but rather the optimal surgical solution for this patient's unique anatomical reality. It was a testament to surgical judgment, demonstrating a philosophy that prioritizes resolving the pathology and preserving patient safety over the mere resection of an anatomical anomaly. In essence, the procedure defused the bomb by removing its fuse (the mucosa) rather than risking a catastrophic explosion by trying to detach it from a vital structure.

Preoperative and Operative Management

A summary of the patient's initial stabilization and the pivotal surgical procedure.

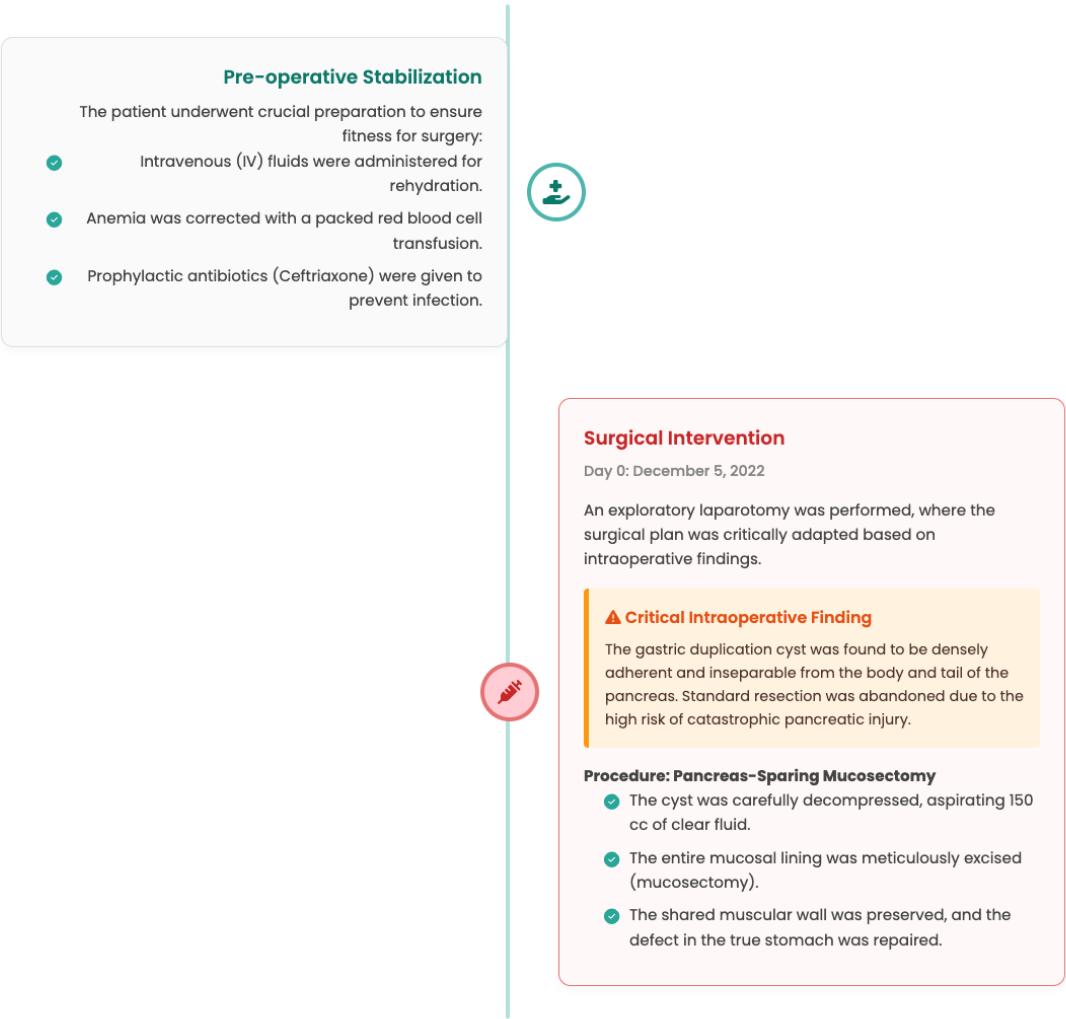


Figure 2. Preoperative and operative management.

Figure 3 showed a detailed chronological timeline of the patient's postoperative course and follow-up, providing a comprehensive narrative of her journey from the immediate, fragile hours after surgery to her thriving status weeks later, and culminating in the definitive histopathological verdict that validated the entire therapeutic strategy. This visual summary encapsulates the essence of surgical success, which is measured not only by the technical execution of a procedure but by the complete restoration of physiological function and the conclusive resolution of the underlying pathology. The timeline is segmented into four crucial stages: the immediate postoperative period, recovery and discharge, short-term follow-up, and the final histopathological diagnosis, each marking a significant milestone in the patient's return to health. The first panel, "Immediate Postoperative Period," focuses on post-operative day 2 and documents a minor and, importantly, expected setback in the infant's recovery. The patient experienced vomiting and exhibited visible peristalsis, symptoms reminiscent of her preoperative condition. However, in the postoperative context, these signs were not indicative of a persistent obstruction but were correctly assessed as a transient postoperative ileus. This condition is a common and anticipated temporary disruption of bowel motility following major abdominal surgery. The extensive handling of the intestines, the effects of anesthesia, and the inflammatory response to the surgical trauma can temporarily paralyze the coordinated contractions of the gastrointestinal tract. The "Action" taken was textbook conservative management: the placement of a nasogastric tube (NGT) for decompression and the maintenance of intravenous (IV) hydration. The NGT serves to remove gastric secretions and swallowed air, preventing the stomach from becoming distended, which in turn alleviates nausea and vomiting and allows the bowel to rest. Continuous IV hydration is critical during this period to maintain fluid and electrolyte balance while the patient is unable to take nutrition orally. This careful and standard management reflects an understanding of the natural

course of recovery after such a procedure, treating the setback not as a complication, but as a temporary phase to be supported until the body's normal functions resume.

The second panel, "Recovery & Discharge," chronicles the turning point from post-operative day 3 to day 7, marking the definitive resolution of the ileus and the beginning of a swift recovery. The first key event noted is on day 3, with the resolution of vomiting and the passage of flatus. The passage of flatus is a cardinal sign that the postoperative ileus is resolving and that coordinated peristaltic activity has returned to the bowels. This positive development allowed for the removal of the NGT and the "cautious initiation of oral feeding" with breast milk, which was reported as being "tolerated well". This is a significant milestone, representing the transition from parenteral support back to normal physiological nutrition. Breast milk is the ideal initial choice, as it is easily digestible and provides optimal nutrition for an infant. The success of this feeding trial confirmed that the surgical repair was intact and that the previous gastric outlet obstruction was truly resolved. By post-operative day 7, the patient's condition had transformed dramatically. She was described as "alert, active, feeding well exclusively with breast milk," with a soft, non-distended abdomen. This clinical picture stands in stark contrast to the frail, chronically ill infant who presented for admission. Having met all the criteria for a safe return home, she was discharged in good condition, marking the successful completion of her in-hospital treatment.

The third panel, "Short-Term Follow-up," documents the patient's status on post-operative day 11 and provides the most powerful and objective proof of the surgery's success. The report states that the patient was "thriving at home with no complaints" and had a normal physical examination. While this subjective report from the family is heartening, the "Key Outcome" highlighted in the figure provides the irrefutable evidence: a "significant weight gain of 300g since discharge". This piece of data is the unambiguous, objective sign that the core problem of

gastric outlet obstruction has been definitively cured. For four months prior to surgery, the infant's life was defined by a cycle of poor feeding and vomiting that led to undernutrition and failure to thrive. The ability to gain 300 grams in just a few days is a physiological impossibility for a child with a significant obstruction. This rapid weight gain powerfully demonstrates that she was now able to consume and, more importantly, absorb nutrients effectively, allowing her to enter a phase of catch-up growth. This outcome stands as a powerful testament to the success of the chosen surgical strategy, validating the decision to perform the pancreas-sparing mucosectomy. It confirmed that the procedure not only removed the problematic lesion but, in doing so, restored normal physiological function and put the child back on a healthy developmental trajectory.

The final panel, "Definitive Histopathology," provides the scientific conclusion to the case, confirming the diagnosis and validating the surgical approach on a cellular level. The excised mucosal lining, the "pathologic engine" of the cyst, was sent for analysis. The pathological examination confirmed the diagnosis of a "Benign Gastric Duplication Cyst," meeting the classic criteria of being an enteric-lined structure with a smooth muscle coat intimately attached to the gastrointestinal tract. This finding confirmed the preoperative diagnostic suspicions. However, the most critical part of the report was the "Result": "No evidence of dysplasia or malignancy was found". This is the ultimate justification for the surgical team's decision to pivot from a high-risk complete resection to the innovative mucosectomy. The primary reason surgical doctrine mandates complete resection of these cysts is to mitigate the small but lethal risk of malignant transformation. The histopathology report confirmed that by meticulously stripping out the entire mucosal lining, the surgeons had successfully removed the only tissue layer capable of undergoing such a transformation, thereby providing the same long-term oncological safety as a complete resection. This final piece of evidence

affirmed that the pancreas-sparing mucosectomy was not a lesser, compromised procedure but was, for this specific and complex anatomical situation, the most logical, safest, and most effective treatment, one that definitively cured the patient's condition while honoring the fundamental surgical principle of "first, do no harm".

3. Discussion

The successful management of this infant, grappling with a rare and anatomically complex gastric duplication, offers a profound insight into the intersection of embryology, pathophysiology, and the art of surgical decision-making. This case was not merely the removal of a congenital lesion; it was a navigation through a diagnostic labyrinth, culminating in an intraoperative ethical and technical crossroads that demanded a departure from established doctrine. To truly appreciate the surgical challenge presented by this infant, one must first travel back in time to the earliest weeks of her embryonic life, to the period when the primitive gut was transforming from a simple tube into a complex organ system. The genesis of a gastric duplication is an error in this intricate developmental choreography. While the exact cause remains elusive, several compelling theories offer windows into the potential missteps.⁹ The most widely cited is Bremer's theory of failed recanalization. In the 5th to 6th week of gestation, the lumen of the primitive foregut is temporarily obliterated by the rapid proliferation of its epithelial lining, transforming it into a solid cord. Subsequently, a process of programmed cell death and vacuolization re-establishes the lumen. Bremer's theory posits that if one or more of these vacuoles fail to coalesce with the main lumen, they can become sequestered, retaining their growth potential and evolving into a duplication cyst, a true "embryological ghost" that remains tethered to the parent organ. This theory elegantly explains the cystic, non-communicating nature of the lesion seen in our patient.¹⁰

Postoperative Course and Follow-up

A timeline of the patient's recovery, successful outcome, and definitive diagnosis.

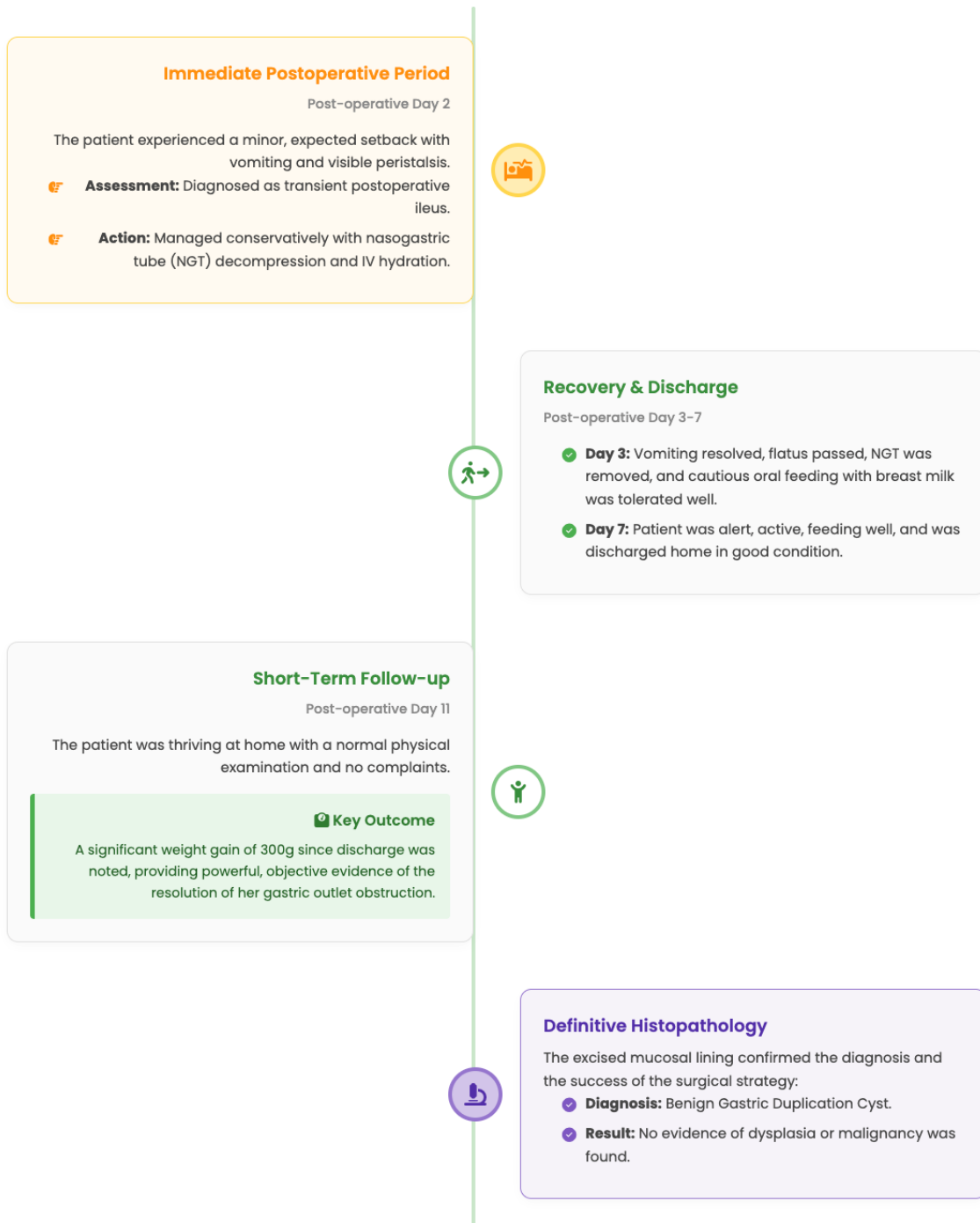

Figure 3. Postoperative course and follow-up.

An alternative, the "split notochord" theory, implicates a failure in the fundamental organization of the embryo's primary axes. During neurulation, the notochord normally separates from the overlying endoderm of the gut tube. If an abnormal adhesion persists between these two layers, the gut tube may be pulled dorsally and split into two, with one portion developing into the normal stomach and the other forming the duplication. This theory is particularly attractive for explaining duplications associated with vertebral anomalies, as the notochord is the precursor to the vertebral bodies.¹¹ While our patient had no such associated anomalies, it remains a plausible, albeit less likely, explanation. The most critical embryological consideration in this specific case, however, involves the intimate relationship between the developing foregut and the pancreas. The pancreas arises from two separate buds—a dorsal and a ventral bud—which originate from the endoderm of the foregut in the 4th week. As the gut tube rotates, the ventral bud migrates to fuse with the dorsal bud, forming the mature pancreas. The body and tail of the pancreas, the parts found adherent to the duplication cyst in our patient, originate from the dorsal bud, which develops in the dorsal mesentery directly behind the stomach.¹¹ It is highly plausible that the embryological event that caused the gastric duplication—be it a recanalization error or a focal developmental anomaly—occurred in such close proximity to the developing dorsal pancreatic bud that the two structures became inextricably fused, sharing a common mesenchymal investment that would later mature into a shared seromuscular coat. This was not an inflammatory adhesion acquired later in life; it was a congenital fusion, a shared origin story written into the very fabric of the infant's anatomy. This understanding transforms the intraoperative finding from a mere complication into a logical consequence of a localized embryological field defect.

The three classic histopathological criteria for diagnosing an alimentary tract duplication are: (1) an intimate connection to some part of the gastrointestinal tract, (2) the presence of a well-

developed smooth muscle coat, and (3) a lining of gastrointestinal mucosa. Our patient's lesion met all three. The smooth muscle layer is the defining feature that distinguishes a true duplication from other cystic lesions. It is this layer that allows the duplication to contract, and it is the shared nature of this layer with the true stomach that created the surgical dilemma. The mucosal lining is the functional "engine" of the pathology.¹² In our patient, this lining was composed of benign gastric-type foveolar epithelium, identical to that of a normal stomach. This mucosa, under hormonal and neural influence, carries out its physiological duty: it secretes fluid. In a communicating duplication, this fluid might drain into the main gastric lumen with minimal consequence. However, in a non-communicating cystic duplication, as was the case here, there is no exit. The relentless, drop-by-drop secretion of mucoid fluid into a closed space creates a perfect storm. The cyst behaves like a slowly inflating balloon, with its volume and internal pressure steadily increasing over weeks and months. The 150 cc of clear fluid aspirated during surgery was the physical evidence of this months-long secretory process. This progressive expansion is what drives the clinical symptoms. Initially, the small, compliant cyst is asymptomatic. As it enlarges, it begins to exert a mass effect.¹² In our patient, it compressed the greater curvature of the true stomach, creating a functional gastric outlet obstruction. This explains her primary symptom: non-bilious, post-prandial vomiting. The stomach, unable to properly empty its contents past the extrinsic compression, rebels. The visible peristalsis observed on her abdomen was the stomach's futile, hypertrophic attempt to overcome this blockade. The palpable mass was, of course, the fluid-filled duplication itself. The chronic inflammation suggested by her blood work (leukocytosis, thrombocytosis, elevated CRP) was likely a response to tissue stretching, pressure ischemia on the cyst wall, and possibly even microscopic leakage of inflammatory mediators. Her failure to thrive was a direct consequence of this cascade: a cycle of poor feeding, vomiting, and chronic

systemic stress.

Figure 4 showed a clear and elegant visualization of the pathophysiological cascade, meticulously tracing the progression from a silent congenital anomaly to a life-altering clinical syndrome. The figure logically segments this journey into four distinct stages, beginning with the embryological origin of the lesion and culminating in the severe symptomatology that brought the infant to medical attention. This cascade is not merely a sequence of events but a chain reaction of cause and effect, where each stage inexorably leads to the next, driven by the fundamental nature of the lesion itself. The first stage, "The Silent Anomaly," establishes the root cause of the entire clinical picture: a non-communicating gastric duplication cyst. The figure correctly identifies this as a "congenital error," an issue originating during the earliest weeks of embryonic life. While the precise embryological misstep remains a subject of debate, leading theories suggest it could be an error in the recanalization of the primitive gut tube, where sequestered vacuoles fail to merge with the main lumen and evolve into a separate cystic structure. The figure emphasizes two critical features of this anomaly. First, it is non-communicating, meaning it is a closed space with no outlet into the normal stomach. This feature is the absolute prerequisite for the entire pathological process that follows. Second, and most importantly, its wall contains a secretory gastric-type mucosal lining, aptly termed the "pathologic engine." This mucosal lining, though ectopic, is functionally active and carries out its physiological duty: it secretes fluid. This leads directly to the second stage, "Relentless Secretion." The figure illustrates how the mucosal lining relentlessly secretes fluid into the closed space of the cyst. Because there is no drainage pathway, this relentless, drop-by-drop accumulation over weeks and months causes the cyst to behave like a "slowly inflating balloon." The cyst's internal pressure and volume steadily increase, a process physically evidenced by the 150 cc of clear fluid that was aspirated from the lesion during surgery. This gradual but inexorable expansion is what transforms

a silent, asymptomatic anomaly into a dynamically growing and problematic lesion. The consequence of this relentless expansion is depicted in the third stage, "Mass Effect & Obstruction." As the fluid-filled cyst enlarges, it begins to exert a significant mass effect on the adjacent stomach. The figure details three key consequences of this mechanical pressure. First is the "extrinsic compression of the stomach wall," a finding that was definitively confirmed on the patient's barium fluoroscopy study, which showed a large filling defect along the greater curvature. Second, this compression leads to the "impeded passage of food and liquids," creating a functional gastric outlet obstruction. The stomach, unable to properly empty its contents past this blockade, rebels. This is manifested by the third consequence listed: "visible gastric peristalsis." This striking physical sign represents the stomach's futile, hypertrophic attempt to forcefully push its contents past the obstruction. The final stage of the cascade, "Clinical Manifestation," connects the underlying mechanical and physiological derangements to the severe clinical symptoms observed in the patient. The figure lists the key symptoms that define this patient's illness, each a direct result of the preceding stages. The "non-bilious, post-prandial vomiting" is the hallmark of a high gastric obstruction, occurring after meals when the stomach cannot empty and proximal to the entry of bile into the duodenum. The "palpable, growing abdominal mass" is the physical manifestation of the fluid-filled duplication cyst itself, which had grown from the size of a marble to that of a "chicken egg" over the four-month period of delayed treatment. The "chronic inflammation," evidenced by laboratory findings of leukocytosis and elevated C-reactive protein (CRP), was likely a systemic response to the constant tissue stretching, pressure ischemia on the cyst wall, and the potential leakage of inflammatory mediators. Finally, the culmination of this entire pathological process is "failure to thrive and undernutrition." This was the direct consequence of the vicious cycle of poor feeding, chronic vomiting, and the systemic stress of inflammation, which collectively robbed the infant of the calories and nutrients

necessary for growth and development, leading to the frail state in which she presented.

The operating room is often described as a place of controlled, predictable action. Yet, it is also a place of profound uncertainty, where the surgeon must be prepared to confront the unexpected.¹⁴ The discovery of the cyst's inseparable fusion to the pancreas was the fulcrum upon which this entire case turned. The established surgical doctrine for a gastric duplication is clear and uncompromising: complete resection.¹⁵ This doctrine is built on the undeniable need to prevent future complications and, most importantly, to eliminate the risk of malignant transformation. Adenocarcinoma arising in a gastric duplication, while rare, is a lethal entity. Following this doctrine would have required us to continue the dissection, to meticulously "shave" the muscular wall of the cyst off the fragile parenchyma of the pancreas. This

maneuver would have been fraught with peril.¹⁶ The pancreas is a notoriously unforgiving organ. It lacks a tough, protective capsule like the liver or spleen. Its tissue is granular and friable. Its blood supply is rich and complex. Most dangerous of all, it is a factory of potent digestive enzymes—trypsin, amylase, lipase—which, if leaked, can auto-digest surrounding tissues with catastrophic consequences. The potential complications were stark: a pancreatic fistula, bathing the abdomen in corrosive enzymes; a walled-off collection of this fluid, forming a pseudocyst; acute, life-threatening pancreatitis; or uncontrollable hemorrhage from the splenic or pancreaticoduodenal vessels. The risk of inflicting one of these devastating iatrogenic injuries upon an 8-month-old infant in the course of removing a benign lesion was, in our collective judgment, unacceptably high.¹⁷

The Pathophysiological Cascade

Tracing the progression from a silent embryological anomaly to symptomatic gastric outlet obstruction.

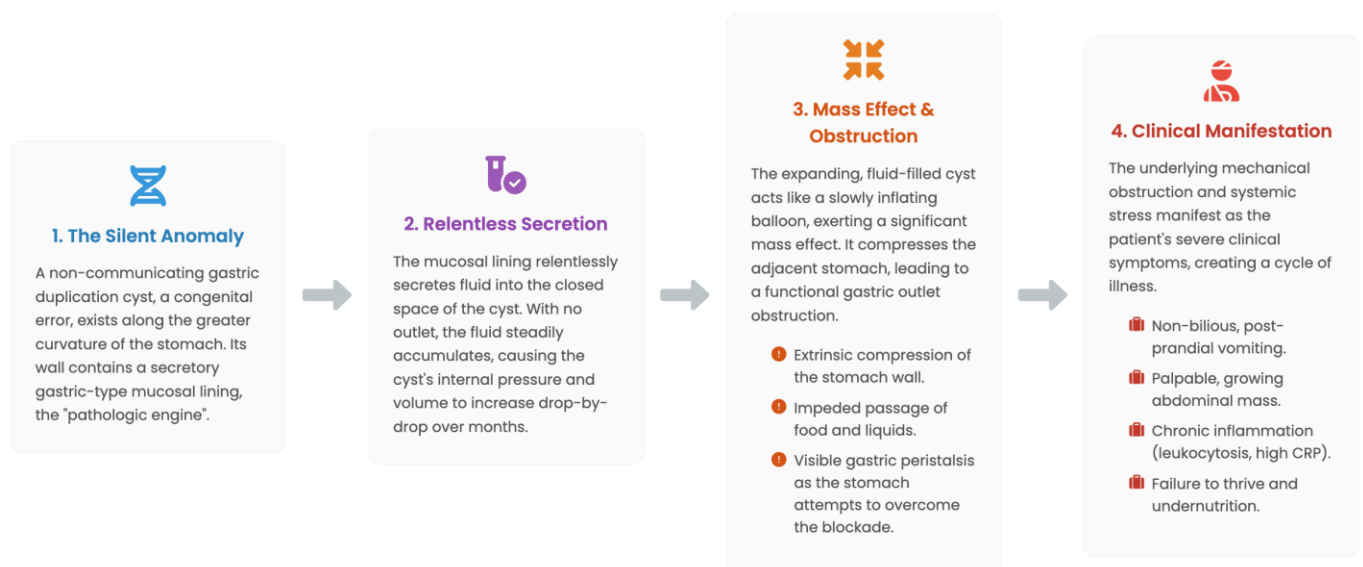

Figure 4. The pathophysiological cascade.

This was the moment of a paradigm shift. The goal changed from resection to resolution. We asked a different question: what is the fundamental problem we need to solve? The problem was not the muscular wall of the duplication; it was the secreting, potentially malignant mucosal lining within it. This led us directly to the choice of a pancreas-sparing mucosectomy. This procedure is the surgical embodiment of a different philosophy: remove the disease, preserve the patient. By incising the cyst and meticulously stripping out every last cell of the mucosal lining, we effectively "deactivated" the duplication.¹⁸ We removed its secretory engine, thus guaranteeing it could never again accumulate fluid and cause an obstruction. We removed the only tissue layer capable of malignant transformation, thus addressing the long-term oncological risk. What remained was the inert, shared muscular wall, which we left in situ to serve as a protective barrier for the pancreas. This approach preserved the integrity of the pancreas, completely avoiding the risks of the alternative strategy.¹⁹ The success of this approach is borne out by the patient's outcome. The rapid resolution of her vomiting and her impressive postoperative weight gain are direct physiological proof that the obstruction was relieved. Mucosectomy, in this context, was not a compromise; it was the most logical, safest, and most effective treatment for this child's unique anatomical reality. It honored the surgical principle of *primum non nocere*—first, do no harm—while still providing a definitive cure for her underlying condition. This case serves as a powerful testament that the true art of surgery lies not in rigidly adhering to a single doctrine but in having the wisdom to know when to adapt and the skill to execute a new plan with precision and care.²⁰

4. Conclusion

This case of a gastric duplication cyst fused to the pancreas was far more than a rare clinical finding; it was a profound lesson in surgical philosophy. It demonstrates with vivid clarity that while the principles of surgery are written in textbooks, their application is perfected only at the operating table,

where unexpected anatomy demands intellectual agility and technical creativity. The decision to pivot from a standard resection to a pancreas-sparing mucosectomy was a conscious choice to prioritize the safety of the patient over the dogma of a procedure. We chose to defuse the pathologic engine of the cyst—its mucosal lining—rather than risk catastrophic collateral damage to a vital organ. The patient's swift and complete recovery, marked by the unambiguous, objective sign of weight gain, stands as a testament to the success of this tailored approach. This case champions a simple, powerful truth: the ultimate goal of surgery is not merely to resect disease, but to restore health. In complex congenital anomalies, this is sometimes best achieved not by radical excision, but by an elegant, organ-preserving solution that cures the pathology while cherishing the patient.

5. References

1. Nandan R, Yadav DK. Gastric duplication cyst mimicking pancreatic pseudocyst in a child with situs inversus totalis. *BMJ Case Rep.* 2024; 17(1): e256871.
2. Herrera Kok JH, Lorenzo MP, Martínez Blanco LC, Álvarez Cañas MC, Martín MH, Matanza Rodríguez MI, et al. Gastric duplication cyst degeneration with peritoneal carcinomatosis. *Eur J Surg Oncol.* 2024; 50(2): 107893.
3. Hu B, Xie Q, Ye Y, Gao Z. A rare case of adult multiple gastric duplications with different shapes and an intestinal-duplication cyst. *Asian J Surg.* 2024; 47(2): 1304–5.
4. Karaseva OV, Nalbandyan RT, Medinskiy PV, Kharitonova AY, Bagaev VG, Gromova AA. Gastric duplication in a teenager: a case report. *J Pediatr Surg Case Rep.* 2024; 102(102779): 102779.
5. Zhao T, Kwan M, Barrera CA, Shroff S, Oliva E. Retroperitoneal foregut duplication cyst containing gastric, respiratory, and pancreatic tissue misinterpreted as an adrenal mass on imaging: a case report and

- review of the literature. *Int J Surg Pathol*. 2024; 32(4): 780–6.
6. Namikawa T, Aida M, Utsunomiya M, Yokota K, Munekage M, Maeda H, et al. Laparoscopic resection of a gastric duplication cyst located near the esophagogastric junction. *Clin J Gastroenterol*. 2024; 17(2): 222–7.
7. Miyamoto S, Ishii Y, Serikawa M, Tatsukawa Y, Nakamura S, Ikemoto J, et al. A case of young male with recurrent acute pancreatitis caused by an intrapancreatic gastric duplication cyst. *Clin J Gastroenterol*. 2024; 17(4): 742–7.
8. Zülfikaroğlu B, Akgül Ö, Mahir Özmen M. A rare case of multiple gastric duplication cysts in an adult. *Turk J Surg*. 2024; 40(3): 264–6.
9. Castellani R, Prefumo F, Bondioni MP. Prenatal diagnosis of multiple gastric duplication cysts. *Arch Gynecol Obstet*. 2024; 310(3): 1723–5.
10. Liu C, Xu C, Xu X, Zhang Y, Geng L, Mei Y, et al. Anal canal duplication with heterotopic gastric mucosa and anal stenosis: first case report and literature review. *Front Pediatr*. 2024; 12: 1452116.
11. Goto Y, Shinkai T, Sakai H, Matsuoka K, Masumoto K. Prenatally diagnosed intralobar pulmonary sequestration with a gastric foregut duplication cyst. *Pediatr Pulmonol*. 2025; 60(1): e27454.
12. Katiyar S, Piplani R, Syal S, Suman BK, Kothari P, Saini R. Hydatid cyst liver masquerading as a gastric duplication cyst: a diagnostic dilemma. *J Indian Assoc Pediatr Surg*. 2025; 30(1): 116.
13. Liu F-G, Sun X-G, Wang W-H, Shan T-D. Gastric duplication cysts with mixed hemangioma treated by endoscopic submucosal dissection: a case report and literature review. *Pathol Res Pract*. 2025; 266(155819): 155819.
14. Wang M, Wang L, Chen Y, Qian Y, Chen Q. Clinical characteristics and treatment of gastric duplications in children. *J Pediatr Surg*. 2025; 60(3): 162115.
15. Kim SK, Lee TY. Splenic duplication, a rare cause of gastric varices: a case report. *J Korean Soc Radiol*. 2025; 86(2): 298–303.
16. Hroub O, Ibraheem K, Hroub M, Manasrah N, Herbawi AN, Eltamimi B. A case of gastric duplication cyst in an 18-year-old female. *Int J Surg Case Rep*. 2025; 128(111099): 111099.
17. Zouirech Y, Manni A, Al Jabary B, Bouljrouf J, Kisra M. A rare case of bilobed gastric duplication cyst in a four-month-old infant. *Cureus*. 2025; 17(3): e81435.
18. Chen J, Shi C, Chen A. Esophageal and gastric duplication malformation: a case report. *Asian J Surg*. 2025.
19. Nwakor S, Reinshagen K, Suß J, Jürgens J, Wenke K, Tomuschat C. Congenital gastric duplication cyst: a case report of a 36 day-old girl. *Z Geburtshilfe Neonatol*. 2025.
20. Hernández-Alvarado S, Peña-Gio CG, Villarreal-Zavala R, Gutiérrez-Pérez M, Pérez-Valdez D, Alcántara-Dzib JR, et al. Gastric duplication cyst in an adult woman: a case report. *J Surg Case Rep*. 2025; 2025(6): rjaf324.