



Bioscientia Medicina: Journal of Biomedicine & Translational Research

Journal Homepage: www.bioscmed.com

Unmasking the Culprit: Successful Restoration of Menstrual Function in a Case of Secondary Amenorrhea Due to Tuberculous Endometritis Mimicking Polycystic Ovary Syndrome

Riyan Hari Kurniawan^{1*}, Muhammad Syauqi Mirza¹, Ilham Utama Surya¹, Muhammad Dwi Priangga¹, Cepi Teguh Pramayadi¹, Herbert Situmorang¹, Eka Rusdianto Gunardi¹

¹Department of Obstetrics and Gynecology, Faculty of Medicine, Universitas Indonesia/Dr. Cipto Mangunkusumo National General Hospital, Jakarta, Indonesia

ARTICLE INFO

Keywords:

Diagnostic overshadowing
Genital tuberculosis
Polycystic ovary syndrome
Secondary amenorrhea
Tuberculous endometritis

*Corresponding author:

Riyan Hari Kurniawan

E-mail address:

riyanharikurniawan@yahoo.com

All authors have reviewed and approved the final version of the manuscript.

<https://doi.org/10.37275/bsm.v9i9.1390>

ABSTRACT

Background: Secondary amenorrhea presents a significant diagnostic challenge in gynecology. While Polycystic Ovary Syndrome (PCOS) is a common cause, rare etiologies like tuberculous endometritis can be overlooked, especially in patients with features suggestive of PCOS. This phenomenon, known as diagnostic overshadowing, can lead to delayed diagnosis and irreversible reproductive consequences. **Case presentation:** A 35-year-old nulligravid woman with a diagnosis of Class I Obesity presented with a five-year history of secondary amenorrhea and a desire for fertility. Her clinical and initial ultrasonographic findings were suggestive of PCOS. However, persistent amenorrhea despite hormonal therapy prompted further investigation. Hysteroscopy revealed a fibrotic uterine cavity with micropolyps, and subsequent endometrial biopsy with histopathology, polymerase chain reaction (PCR), and culture confirmed a diagnosis of tuberculous endometritis. The patient was successfully treated with a six-month anti-tuberculosis regimen, cyclical progestin therapy, and a structured lifestyle modification program. Following treatment, she experienced a significant weight loss, resumption of regular menstrual cycles, and marked improvement in endometrial and ovarian ultrasound parameters. **Conclusion:** This case underscores the critical importance of a comprehensive diagnostic evaluation for secondary amenorrhea, including endometrial sampling, even when a common diagnosis like PCOS is suspected. It highlights the potential for tuberculous endometritis to mimic PCOS and demonstrates the efficacy of a multidisciplinary approach in restoring menstrual and potentially reproductive function. Clinicians in tuberculosis-endemic regions must maintain a high index of suspicion for this insidious pathology to prevent long-term morbidity.

1. Introduction

Secondary amenorrhea, the cessation of menstruation for three or more months in a woman with previously regular cycles, or six or more months in a woman with previously irregular cycles, affects a significant portion of women of reproductive age.¹ It is a symptom of a wide spectrum of underlying disorders, ranging from physiological states like

pregnancy and lactation to complex endocrine and anatomical abnormalities. Among the most prevalent causes is polycystic ovary syndrome (PCOS), a heterogeneous endocrine disorder affecting a large percentage of reproductive-age women worldwide.² Diagnosed based on the 2003 Rotterdam criteria—requiring two of the three features of oligo- or anovulation, clinical or biochemical

hyperandrogenism, and polycystic ovarian morphology on ultrasound—PCOS is frequently associated with amenorrhea and infertility.³

However, the high prevalence of PCOS can lead to a phenomenon known as "diagnostic overshadowing," where a confirmed or suspected diagnosis of PCOS may prematurely curtail further investigation into other, rarer causes of menstrual dysfunction.⁴ This is particularly perilous when the underlying pathology is an insidious and destructive condition like female genital tuberculosis (FGTB). Tuberculous endometritis, caused by the hematogenous spread of *Mycobacterium tuberculosis* to the endometrium, is a significant, albeit uncommon, cause of amenorrhea and infertility, especially in regions where tuberculosis is endemic, including Southeast Asia, Africa, and Latin America.⁵ The clinical presentation of tuberculous endometritis is often vague and non-specific, with menstrual irregularities being the most common symptom, ranging from oligomenorrhea to amenorrhea.⁶

The coexistence of PCOS and tuberculous endometritis presents a formidable diagnostic and therapeutic challenge.⁷ The amenorrhea can be easily misattributed solely to the anovulatory nature of PCOS, leading to a critical delay in the diagnosis and treatment of the tuberculous infection.⁸ Such a delay can result in irreversible damage to the endometrium, leading to the formation of intrauterine adhesions (Asherman's syndrome), tubal blockage, and permanent infertility.

Furthermore, emerging evidence suggests a potential pathophysiological interplay between PCOS and tuberculosis. PCOS is characterized by a state of chronic low-grade inflammation, insulin resistance, and immune dysregulation. These factors may theoretically create a host environment that is more susceptible to the reactivation of latent tuberculosis or the establishment of a new infection.⁹ Conversely, the profound inflammatory cascade initiated by *Mycobacterium tuberculosis* within the reproductive tract could exacerbate the existing metabolic and hormonal derangements of PCOS, further disrupting

the hypothalamic-pituitary-ovarian (HPO) axis and worsening ovulatory dysfunction.

To date, the literature on the concurrent diagnosis and management of PCOS and tuberculous endometritis is exceptionally sparse. This case report aims to fill this gap by presenting a detailed account of a patient with long-standing secondary amenorrhea, where a diagnosis of tuberculous endometritis was unmasked behind the clinical features of PCOS.¹⁰ The primary objectives of this report are to emphasize the importance of endometrial sampling in secondary amenorrhea, even in patients with a presumptive diagnosis of PCOS, and to demonstrate the efficacy of a multi-pronged therapeutic approach in restoring reproductive function. This case serves as a crucial reminder for clinicians to maintain a high index of suspicion and to pursue a thorough diagnostic workup to prevent devastating reproductive consequences.

2. Case Presentation

Written informed consent was obtained from the patient for the publication of this case report and any accompanying images. All patient data have been anonymized to protect her privacy.

A 35-year-old G0P0A0 woman presented to our gynecology clinic with a chief complaint of absent menstrual periods for the past five years. She had been married for seven years and was actively seeking to conceive. Her menarche occurred at the age of 14, followed by regular menstrual cycles of 28-30 days, lasting for 5-6 days with normal flow and no dysmenorrhea. The patient's menstrual history began to change in 2016, when she noted a reduction in the duration and volume of her periods, although they remained regular. By 2017, her menses became progressively lighter and shorter, lasting only 1-2 days. In 2018, her cycles became irregular, with only occasional spotting, and by early 2019, she had a complete cessation of menses, which persisted until her presentation in 2024. She reported no history of unintentional weight loss, chronic cough, fever, or night sweats. She also denied any symptoms of

hyperandrogenism, including hirsutism, severe acne, or androgenic alopecia. There was no history of pelvic inflammatory disease, sexually transmitted infections, or previous uterine surgery (Table 1).

On physical examination, the patient appeared in good general health. Her vital signs were stable. Her height was 170 cm and her weight was 92 kg, yielding a Body Mass Index (BMI) of 31.8 kg/m², classifying her

as Obese Class I. A general physical examination was unremarkable. Gynecological examination revealed a normal vulva and vagina. The cervix appeared smooth, and the external os was closed. Bimanual examination was challenging due to the patient's body habitus but did not reveal any uterine enlargement or adnexal masses. There was, however, mild cervical motion tenderness noted.

Table 1. Summary of clinical findings on admission.

PARAMETER	FINDING ON ADMISSION	CLINICAL SIGNIFICANCE / INTERPRETATION
 Patient Demographics & Chief Complaint		
Age	35 years	Reproductive age group, where secondary amenorrhea is a significant concern.
Gravidity & Parity	G0P0A0 (Nulligravida)	Indicates no prior pregnancies, highlighting primary infertility concern.
Chief Complaint	5-year history of secondary amenorrhea; desire for fertility.	Long duration points towards a chronic, unresolved underlying pathology.
 Anthropometry & Physical Examination		
Body Mass Index (BMI)	31.8 kg/m ²	Obese Class I. A significant risk factor for PCOS and anovulation.
Constitutional Symptoms	No fever, night sweats, or chronic cough reported.	Absence of classic TB symptoms, highlighting the often insidious nature of genital tuberculosis.
Gynecological Exam	Normal external genitalia; mild cervical motion tenderness.	Tenderness can be a subtle sign of pelvic inflammation (endometritis, salpingitis).
 Imaging & Diagnostic Workup		
Progestin Challenge Test	Negative. No withdrawal bleeding.	Crucial finding suggesting severe endometrial compromise or outflow tract obstruction, ruling out simple anovulation.
Transvaginal Ultrasound (Endometrium)	Thin (5.1 mm), irregular, with hyperechoic foci.	Atypical for PCOS. Suggests chronic inflammation, fibrosis, or calcification.
Transvaginal Ultrasound (Ovaries)	Enlarged volumes (R: 12.4 cm ³ , L: 13.1 cm ³); >20 antral follicles per ovary.	Classic Polycystic Ovarian Morphology (PCOM), fulfilling one of the Rotterdam criteria for PCOS.
Hysteroscopy	Pale, atrophic cavity; multiple mucopolyps; calcified nodules; filmy adhesions.	Direct visualization of a severely damaged endometrium, highly suggestive of chronic granulomatous disease like TB.
Histopathology & PCR	Positive. Epithelioid granulomas with caseous necrosis; M. tuberculosis DNA detected by PCR.	Definitive, gold-standard diagnosis of Tuberculous Endometritis.
 Final Diagnosis on Admission		
Secondary Amenorrhea due to a Dual Pathology: <ul style="list-style-type: none">• Tuberculous Endometritis (Confirmed)• Polycystic Ovary Syndrome (fulfilling 2/3 Rotterdam Criteria: Anovulation & PCOM)		A complex case where the common diagnosis (PCOS) masked a more destructive underlying pathology (TB), leading to diagnostic delay.

On initial investigations, a urine pregnancy test was negative. Initial hormonal evaluation revealed a normal thyroid-stimulating hormone (TSH) level of 2.1 $\mu\text{IU/mL}$ (reference range: 0.4–4.0 $\mu\text{IU/mL}$) and a prolactin level of 15 ng/mL (reference range: 4–23 ng/mL). The initial transvaginal ultrasound demonstrated an anteverted uterus of normal size (7.5 x 4.5 x 4.0 cm). The endometrial lining was notably thin and irregular, measuring 5.1 mm at its thickest point. Within the endometrium, multiple small, non-shadowing hyperechoic spots were observed, suggestive of micro-calcifications or fibrosis. Both ovaries were enlarged. The right ovary measured 12.4 cm^3 and the left ovary measured 13.1 cm^3 . Each ovary contained more than 20 small antral follicles (2–9 mm in diameter) arranged peripherally around a dense stroma, consistent with polycystic ovarian morphology (PCOM).

Given the combination of secondary amenorrhea (anovulation) and PCOM on ultrasound, a presumptive diagnosis of PCOS was made. The patient was counseled on lifestyle modifications and started on a trial of hormonal therapy with medroxyprogesterone acetate (10 mg daily for 10 days each month) to induce withdrawal bleeding and protect the endometrium. However, she failed to have any withdrawal bleeding after three consecutive cycles of progestin challenge.

The failure to respond to the progestin challenge, coupled with the abnormal endometrial appearance on ultrasound, raised suspicion for an intrauterine pathology. A comprehensive workup was initiated. An office hysteroscopy was performed. The uterine cavity was found to be open but had an abnormal appearance. The endometrium was pale and atrophic, and the cavity was distorted by the presence of multiple, sessile micropolyps, ranging from 2 to 5 mm in size. Some of these polyps had a whitish, calcified appearance, while others were erythematous and inflamed. There were also some filmy adhesions noted in the fundal region.

During hysteroscopy, targeted biopsies were taken from the abnormal-looking areas of the endometrium,

and an endometrial curettage was performed. The histopathological examination of the tissue was the key to the diagnosis. It revealed multiple well-formed epithelioid granulomas with central caseous necrosis and Langhans giant cells, findings that are pathognomonic for tuberculous endometritis.





To confirm the diagnosis and rule out drug resistance, further tests were performed on the endometrial tissue. An acid-fast bacilli (AFB) stain was negative. However, a real-time polymerase chain reaction (PCR) test for *Mycobacterium tuberculosis* complex DNA was positive. Endometrial tissue culture on Löwenstein–Jensen medium subsequently grew *Mycobacterium tuberculosis* after six weeks of incubation, which was sensitive to all first-line anti-tuberculosis drugs. To rule out active pulmonary or systemic tuberculosis, a chest X-ray was performed and was found to be clear. An Interferon-Gamma Release Assay (IGRA) was also positive, indicating exposure to tuberculosis, but not necessarily active disease. Based on these comprehensive findings, a definitive diagnosis of secondary amenorrhea due to tuberculous endometritis, coexisting with Polycystic Ovary Syndrome, was established.

A multidisciplinary management plan was formulated, addressing both the infectious and endocrine aspects of her condition. The patient was started on a standard six-month, directly observed treatment, short-course (DOTS) regimen for genital tuberculosis, as per World Health Organization (WHO) guidelines. This consisted of a two-month intensive phase with four drugs (Rifampicin 450 mg, Isoniazid 300 mg, Pyrazinamide 1500 mg, and Ethambutol 800 mg daily), followed by a four-month continuation phase with two drugs (Rifampicin 450 mg and Isoniazid 300 mg daily). Concurrently, she was continued on cyclical progestin therapy with medroxyprogesterone acetate (10 mg/day for 12 days every month) to regulate her cycles once menstruation resumed and to ensure adequate endometrial shedding. The patient was enrolled in a structured lifestyle modification program supervised by a nutritionist and a physical therapist. The program

focused on a calorie-restricted diet (1500 kcal/day) with low glycemic index foods and a moderate-intensity exercise regimen (150 minutes of brisk walking per week). The patient tolerated the treatment well with no significant adverse effects. After four

months of ATT, she experienced her first spontaneous menstrual period in over five years. Her cycles subsequently became regular, occurring every 30-35 days (Table 2).

Table 2. Therapeutic intervention and follow-up.

INTERVENTION / FOLLOW-UP PARAMETER	DETAILS / OUTCOME	RATIONALE / CLINICAL SIGNIFICANCE
 Therapeutic Interventions		
1. Anti-Tuberculosis Therapy (ATT)	Standard 6-month DOTS regimen (2 months RIPE + 4 months RI).	Cornerstone of treatment. Eradicates the M. tuberculosis infection, halts endometrial destruction, and allows for healing.
2. Hormonal Therapy	Cyclical Medroxyprogesterone Acetate (10 mg/day for 12 days/month).	Ensures regular, organized shedding of the healing endometrium and prevents endometrial hyperplasia from unopposed estrogen.
3. Lifestyle Modification	Structured program: 1500 kcal/day low-GI diet & 150 mins/week moderate exercise.	Targets the metabolic dysfunction of PCOS. Crucial for improving insulin sensitivity and restoring HPO axis function.
 Clinical & Anthropometric Outcomes (at 6-Month Follow-up)		
Menstrual Cycle	Resumption of regular cycles (30-35 day intervals) after 4 months of ATT.	Primary indicator of successful treatment and restoration of the hypothalamic-pituitary-ovarian (HPO) axis.
Weight & BMI	Weight decreased from 92 kg to 77 kg (-15 kg) . BMI reduced from 31.8 to 26.6 kg/m ² .	Significant weight loss, a major contributor to improved metabolic health and spontaneous ovulation in PCOS.
 Sonographic Outcomes (at 6-Month Follow-up)		
Endometrium	Regular, trilaminar appearance; thickness of 6.3 mm. Hyperechoic foci resolved.	Objective evidence of endometrial healing and resolution of the chronic inflammatory changes.
Ovaries	Reduced volume (R: 9.8 cm ³ , L: 10.2 cm ³). Decreased antral follicle count.	Shows improvement in the PCOM phenotype, likely due to improved hormonal milieu following weight loss and treatment.
Evidence of Ovulation	Dominant follicle (16 mm) noted on day 14 of the cycle.	Strong suggestive sign of the return of ovulatory function, a key goal for achieving fertility.
 Overall Status at Follow-up		
Successful clinical and sonographic resolution of tuberculous endometritis with significant improvement in PCOS-related parameters.		The multi-pronged approach successfully addressed both the infectious and metabolic pathologies, leading to restoration of menstrual function.

After completing the full six-month course of ATT, a follow-up evaluation was performed. The patient had achieved a significant weight loss of 15 kg, with her weight now at 77 kg and her BMI reduced to 26.6 kg/m². A repeat transvaginal ultrasound showed remarkable improvement. The endometrium appeared

regular, trilaminar, and had a thickness of 6.3 mm in the proliferative phase. The previously noted hyperechoic spots were no longer visible. Both ovaries showed a reduction in volume (Right: 9.8 cm³, Left: 10.2 cm³) and a decrease in the number of visible antral follicles. A dominant follicle measuring 16 mm

was noted in the right ovary on day 14 of her cycle, suggesting a potential restoration of ovulatory function, though this was not confirmed with serum

progesterone levels. The patient's clinical and sonographic improvements are summarized in Table 3.

Table 3. Comparison of parameters before and after treatment.

PARAMETER	BEFORE TREATMENT (BASELINE)	AFTER 6 MONTHS OF TREATMENT	CHANGE / IMPROVEMENT
Clinical Parameters			
Menstrual Cycle	Secondary Amenorrhea	Regular Cycles (30-35 days)	✔ Restored
Body Mass Index (BMI)	31.8 kg/m ²	26.6 kg/m ²	↓ 5.2 points
Endometrial Parameters			
Thickness	5.1 mm	6.3 mm	↑ 1.2 mm
Appearance	Irregular, Hyperechoic Foci	Regular, Trilaminar	✔ Resolved
Ovarian Parameters			
Right Ovary Volume	12.4 cm ³	9.8 cm ³	↓ 2.6 cm ³
Left Ovary Volume	13.1 cm ³	10.2 cm ³	↓ 2.9 cm ³
Antral Follicle Count	>20 per ovary	~15 per ovary	✔ Reduced
Dominant Follicle	Absent	Present (16 mm)	✔ Restored

3. Discussion

This case report details the successful management of a complex presentation of secondary amenorrhea, where tuberculous endometritis was concealed by the clinical and sonographic features of PCOS. It serves as a powerful illustration of the principle of "diagnostic overshadowing" and provides profound insights into the pathophysiology, diagnosis, and management of such rare dual pathologies.¹¹

The coexistence of PCOS and tuberculous endometritis in our patient raises compelling questions about the potential for a bidirectional pathophysiological relationship between these two conditions. While the literature on this specific comorbidity is scarce, we can extrapolate from our

understanding of the immunopathology of both diseases to formulate a plausible hypothesis. PCOS is now widely recognized as a state of chronic low-grade inflammation.¹² Women with PCOS exhibit elevated levels of pro-inflammatory cytokines, including tumor necrosis factor-alpha (TNF-α), interleukin-6 (IL-6), and C-reactive protein (CRP), independent of obesity. This systemic inflammation is intrinsically linked to insulin resistance, a core feature of the syndrome. Insulin resistance and the resultant hyperinsulinemia can further promote inflammation and oxidative stress.¹³ Furthermore, women with PCOS often have altered immune cell function, including dysfunctional T-lymphocytes and natural killer (NK) cells (Figure 1).

The Pathophysiological Conundrum

A Bidirectional Vicious Cycle Between PCOS and Tuberculosis

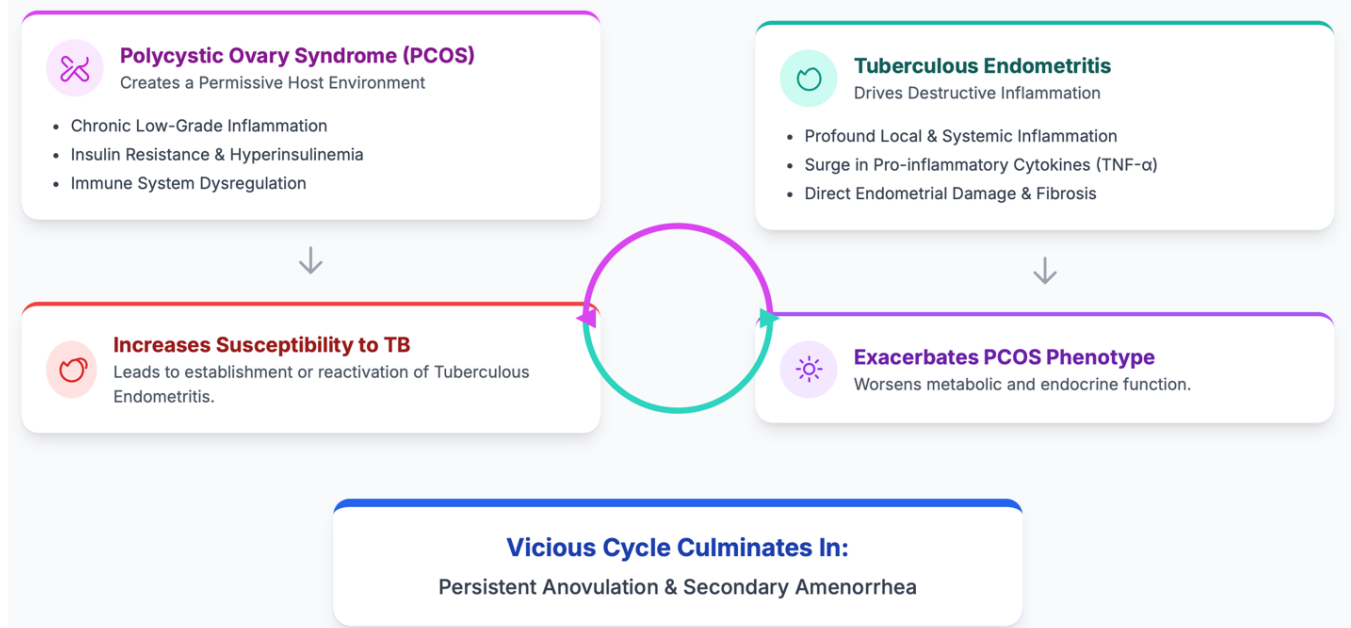


Figure 1. A bidirectional vicious cycle between PCOS and tuberculosis.

This pro-inflammatory and immunologically compromised state could theoretically render a patient with PCOS more susceptible to the reactivation of latent *Mycobacterium tuberculosis* infection or facilitate the establishment of a primary infection in the endometrium.¹⁴ The endometrium of a woman with PCOS is already in a state of "unreceptive inflammation". The addition of a tuberculous infection could be the "second hit" that pushes the endometrium into a state of destructive inflammation, leading to granuloma formation, caseous necrosis, and ultimately, fibrosis and amenorrhea. The hyperandrogenic environment in PCOS might also play a role, as androgens have been shown to modulate immune responses, though their specific impact on mycobacterial immunity is not well understood.¹⁵

Conversely, the profound inflammatory response triggered by tuberculous endometritis could significantly worsen the existing metabolic and endocrine dysfunction of PCOS. The granulomatous

inflammation within the endometrium and potentially the entire pelvis creates a local and systemic surge in pro-inflammatory cytokines, particularly TNF- α . TNF- α is a potent antagonist of insulin signaling and is known to induce insulin resistance by interfering with the insulin receptor substrate-1 (IRS-1) pathway.¹⁶ Therefore, the tuberculous infection could have dramatically exacerbated our patient's underlying insulin resistance, a key driver of her anovulation and hyperandrogenism (although clinical hyperandrogenism was not reported in this case).

This vicious cycle of inflammation is a critical concept. The chronic inflammation of PCOS may have predisposed the patient to tuberculous endometritis, and the tuberculous infection, in turn, likely amplified the inflammatory and metabolic disturbances of PCOS, locking her into a state of persistent anovulation and amenorrhea.¹⁷ This synergistic pathology explains why she was refractory to progestin challenge, as the endometrium was not only anovulatory but also physically destroyed by the

infection.

This case powerfully illustrates the dangers of premature diagnostic closure. The patient's clinical profile—obesity, secondary amenorrhea, and polycystic ovaries on ultrasound—made PCOS the most likely diagnosis. However, several red flags should prompt the astute clinician to look deeper. The failure to induce withdrawal bleeding after an adequate progestin challenge is a critical diagnostic sign. A positive response indicates adequate estrogenization of the endometrium and a patent outflow tract, pointing towards anovulation as the cause of amenorrhea (typical for PCOS).¹⁸ A negative response, as seen in our patient, strongly suggests either an outflow tract obstruction, including Asherman's syndrome, or severe endometrial compromise, where the endometrium is incapable of proliferating in response to hormonal stimulation. This was the pivotal finding that mandated further investigation of the uterine cavity.

While the polycystic ovarian morphology was consistent with PCOS, the endometrial findings were not. A thin, irregular endometrium with hyperechoic foci is not a typical finding in an anovulatory, estrogen-replete PCOS patient. In such patients, one would typically expect a thickened, lush, and potentially hyperplastic endometrium due to unopposed estrogen stimulation. The atrophic and calcified appearance seen in our patient was a clear sign of chronic endometrial pathology.¹⁹

Hysteroscopy with directed biopsy is the gold standard for evaluating intrauterine pathology. In this case, it was indispensable. Hysteroscopy provided a direct visual assessment of the ravaged endometrial cavity, revealing features highly suggestive of chronic granulomatous disease (micropolyps, calcifications, adhesions).¹⁹ The subsequent histopathological confirmation of caseating granulomas closed the diagnostic loop. The use of modern adjunctive tests like PCR and culture for *M. tuberculosis* on the endometrial tissue is crucial for definitive etiological confirmation and for obtaining drug sensitivity information, which is vital in an era of rising drug

resistance. This diagnostic journey emphasizes a fundamental principle in gynecology: amenorrhea is a symptom, not a final diagnosis. A comprehensive and systematic approach is required, moving from non-invasive to invasive tests based on the clinical picture and the response to initial therapies.²⁰

The successful outcome in this patient can be attributed to the comprehensive, multi-pronged therapeutic strategy that simultaneously addressed all facets of her complex pathology (Figure 2). The cornerstone of the treatment was the standard six-month anti-tuberculosis regimen. This eradicated the *Mycobacterium tuberculosis* infection, halted the destructive inflammatory process in the endometrium, and allowed for the potential healing and regeneration of the endometrial basal layer. Without treating the underlying infection, any hormonal therapy would have been futile.

The significant weight loss achieved by the patient cannot be overstated. A weight loss of just 5-10% in obese women with PCOS is known to dramatically improve insulin sensitivity, reduce hyperinsulinemia, decrease androgen levels, and restore spontaneous ovulation and menstruation in up to 75% of cases. In our patient, the 14% reduction in her initial body weight (from 92 kg to 77 kg) was undoubtedly a major contributor to the restoration of her HPO axis function. It likely worked synergistically with the ATT. As the TB-induced inflammation subsided, the improved metabolic milieu from weight loss allowed her own endocrine system to recalibrate and resume ovulatory cycles. The structured dietary and exercise program was key to this success and serves as a model for the management of obese PCOS patients. The use of cyclical progestin therapy served a dual purpose. Initially, its failure as a challenge test was diagnostic. Later, during and after ATT, it provided a regular progestational stimulus to the healing endometrium, ensuring organized shedding and preventing the development of endometrial hyperplasia, which can be a risk in anovulatory women. It is challenging to dissect the precise contribution of each of these three interventions. It is most likely that they had a

synergistic effect. The ATT healed the endometrium, the weight loss restored the HPO axis function, and the hormonal therapy provided regulatory support.

This holistic approach is the key takeaway for managing such complex cases.

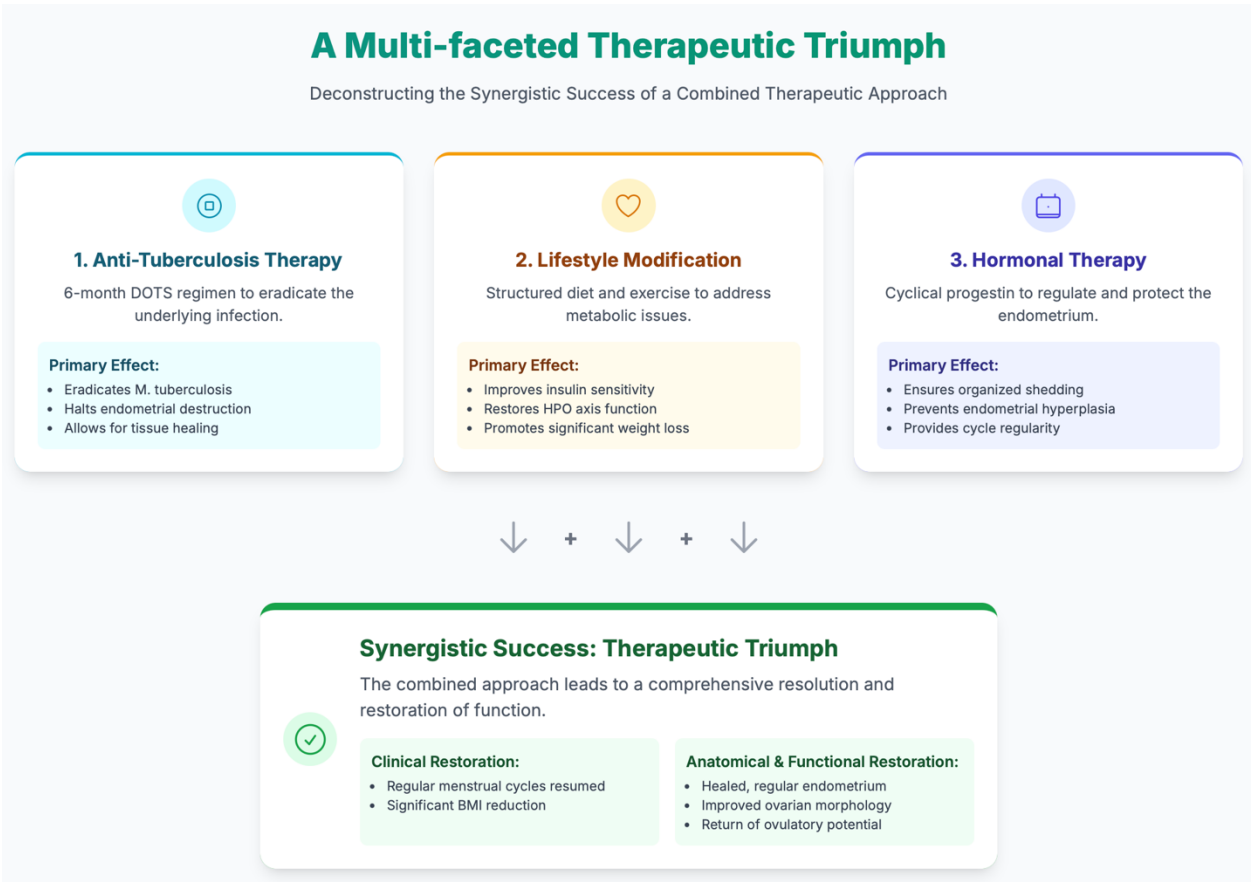


Figure 2. A multi-faceted therapeutic triumph.

The restoration of regular menstrual cycles and the appearance of a dominant follicle on ultrasound are very encouraging signs for this patient's future fertility. However, the journey is not over. Genital tuberculosis is notorious for causing significant tubal damage and pelvic adhesions, which are not assessed by ultrasound. The next step in her fertility management would be a comprehensive evaluation of her tubal patency, for which a hysterosalpingogram (HSG) or a laparoscopy with chromopertubation would be indicated. If the tubes are found to be blocked or damaged, which is unfortunately common after FG TB, then In Vitro Fertilization (IVF) would be the most appropriate treatment option. The successful healing of her endometrium is a crucial prerequisite for

successful embryo implantation, making her a good candidate for IVF should it be necessary. This case also underscores the need for long-term follow-up. While the TB has been treated, the PCOS is a lifelong condition that requires ongoing management to mitigate the long-term risks of type 2 diabetes, cardiovascular disease, and endometrial cancer.

4. Conclusion

This case of secondary amenorrhea due to the dual pathology of tuberculous endometritis and PCOS provides several critical learning points for clinicians. It demonstrates that in regions endemic for tuberculosis, a high index of suspicion for genital tuberculosis must be maintained in all cases of

infertility and menstrual irregularity, including secondary amenorrhea. The presence of a common diagnosis like PCOS should not preclude a thorough investigation for other, more sinister, underlying causes, especially when there are atypical features or a lack of response to standard therapy. The diagnostic paradigm in such cases must include a low threshold for invasive procedures like hysteroscopy and endometrial biopsy. Finally, successful management requires a comprehensive, multidisciplinary approach that targets all underlying pathologies, combining anti-infective therapy, aggressive lifestyle modification, and appropriate hormonal regulation. By unmasking and treating the hidden culprit, we can offer patients like this one the best possible chance of restoring their menstrual health and achieving their reproductive goals.

5. References

1. Sharma N, Singh AS, Khonglah Y, Mishra J. Primary tuberculosis of cervix: a coincidental finding. *J Reprod Infertil*. 2016; 17(4): 247–9.
2. Naik SN, Chandanwale A, Kadam D, Sambarey PW, Dhumal G, DeLuca A, et al. Detection of genital tuberculosis among women with infertility using best clinical practices in India: an implementation study. *Indian J Tuberc*. 2021; 68(1): 85–91.
3. Munne KR, Tandon D, Chauhan SL, Patil AD. Female genital tuberculosis in light of newer laboratory tests: a narrative review. *Indian J Tuberc*. 2020; 67(1): 112–20.
4. Ara SJF, Ahmed S, Saleh AA, Molla MMA, Chowdhury S, Anwar S. Endometrial cytokine expression from clinically suspected genital tuberculosis patients at tertiary care hospitals in Dhaka. *J Clin Tuberc Other Mycobact Dis*. 2022; 27(100301): 100301.
5. Saha A, Singh N, Kashyap D, Kulshrestha A, Sarkar A, Sharma JB, et al. “TB - Mindedness”-the only way to beat “the great mimicker”: a case series with atypical presentation of female genital tuberculosis. *Indian J Tuberc*. 2024; 71(2): 179–84.
6. Perdhana R, Sutrisno S, Sugiri YJ, Baktiyani SCW, Wiyasa A. Patients with secondary amenorrhea due to tuberculosis endometritis towards the induced anti-tuberculosis drug category 1. *Pan Afr Med J*. 2016; 24: 121.
7. Chawla L, Prateek S, Bahadur A, Durgapal P. Intrauterine adhesions with secondary amenorrhea: a notable indicator of endometrial tuberculosis. *Indian J Tuberc*. 2020; 67(4): 575–7.
8. Vasconcelos JP de, Santos IC, Marangoni IP, Ribeiro ES, Fernandes Filho S, Rezende EHM. Hormonal investigation of secondary amenorrhea in young women. *Revista Ibero-Americana de Humanidades, Ciências e Educação*. 2024; 10(7): 1982–92.
9. Hassan S, Lalande BM, Nerenz RD. Secondary amenorrhea and clinical hyperandrogenism in a 34-year-old female: Polycystic ovary syndrome or not? *Clin Chem*. 2025; 71(5): 542–5.
10. Bai F, Nambiar R, Padhiar C, Aruni W, Veeramani C, Alsaif MA, et al. Identification of genetic variants in patients with primary and secondary amenorrhea. *Saudi Med J*. 2025; 46(6): 659–69.
11. Hopkins L, Spero S, Hofmann G. Evaluation of secondary amenorrhea in primary care. *Nurse Pract*. 2025; 50(6): 15–21.
12. Cooper OO, Quint EH, Smith YR, Dendrinis ML. FSH receptor variant: an unusual cause of secondary amenorrhea. *J Pediatr Adolesc Gynecol*. 2025.
13. Shah H, Bhavsar N, Mehta R, Bhandari A, Desai A. Pituitary microadenoma with hyperprolactinemia in an adolescent female with type 1 diabetes mellitus and secondary amenorrhea: a rare case report. *IP Int J Med Paediatr Oncol*. 2025; 11(2): 52–4.

14. Shaikh S, Lewis A. Secondary amenorrhea: hypothalamic amenorrhea an important cause to consider. *Endocr Abstr.* 2022.
15. Than WW, Hossain Parash MT, Abdul Majeed N, Nyein Yin K, Pg Baharuddin DMB, Fahmy EHAM, et al. A case-control study on factors associated with secondary amenorrhea among the medical students of Universiti Malaysia Sabah. *Cureus.* 2023; 15(10): e47625.
16. Novina N, Ritonga MA, Yusuf AS. Gonadotropin levels and underlying diseases in adolescent with secondary amenorrhea. *Int J Womens Health.* 2023; 15: 1397–404.
17. Hussain A, Shah A, Akoto A, Peters AJ, Nelson SM. Pituitary stalk interruption syndrome: a rare cause of amenorrhea in a patient with normal stature and secondary sexual characteristics. *Radiol Case Rep.* 2024; 19(1): 277–80.
18. Tegg NL, Myburgh C, Kennedy M, Norris CM. Impact of secondary amenorrhea on cardiovascular disease risk in physically active women: a systematic review protocol. *JB I Evid Synth.* 2024; 22(2): 343–50.
19. Ahmed TB, Jahan JA, Dey BP, Habib S. Chromosomal abnormalities in primary and secondary amenorrhea. *Bangabandhu Sheikh Mujib Med Univ J.* 2024; 17(2): e71546.
20. Behera A, Panda S, Choudhary AK, Sahu M. Evaluation and management of secondary amenorrhea: a case series in a tertiary care centre. *Int J Med Biomed Stud.* 2024; 8(3): 125–31.