



## Bioscientia Medicina: Journal of Biomedicine & Translational Research

Journal Homepage: [www.bioscmed.com](http://www.bioscmed.com)

# Laparoscopic Primary Crural Repair for Acute-on-Chronic Organoaxial Gastric Volvulus Secondary to a Type II Paraesophageal Hernia: A Case Report and Review of Surgical Strategy

Danu Adi Prakosa Darmawan<sup>1\*</sup>, Agung Aji Prasetyo<sup>2</sup>, Ahmad Fathi Fuadi<sup>3</sup>, Dimas Erlangga Nugrahadi<sup>3</sup>

<sup>1</sup>Student of Surgery Department, Faculty of Medicine and Health Science, Universitas Diponegoro, Semarang, Indonesia

<sup>2</sup>Lecturer, Department of Pediatric Surgery, Faculty of Medicine and Health Science, Universitas Diponegoro, Semarang, Indonesia

<sup>3</sup>Lecturer, Department of Digestive Surgery, Faculty of Medicine and Health Science, Universitas Diponegoro, Semarang, Indonesia

### ARTICLE INFO

#### Keywords:

Crural repair  
Diaphragmatic hernia  
Gastric volvulus  
Laparoscopy  
Paraesophageal hernia

#### \*Corresponding author:

Danu Adi Prakosa Darmawan

#### E-mail address:

[danuadiprakosa@gmail.com](mailto:danuadiprakosa@gmail.com)

All authors have reviewed and approved the final version of the manuscript.

<https://doi.org/10.37275/bsm.v9i9.1393>

### ABSTRACT

**Background:** Gastric volvulus, an abnormal rotation of the stomach, is a rare surgical emergency that can lead to life-threatening gastric ischemia and perforation, particularly when associated with a large paraesophageal hernia (PEH). While paraesophageal hernias are the most common predisposing factor in adults, the optimal surgical management, especially regarding the use of fundoplication and gastropexy, remains a subject of debate. **Case presentation:** We present the case of a 46-year-old male with a six-month history of intermittent epigastric pain and early satiety, who presented with a three-week history of acute-on-chronic gastric outlet obstruction. His symptoms included intractable postprandial vomiting. Laboratory findings were significant for hemoconcentration and a hypochloremic, hypokalemic metabolic state, indicative of severe dehydration. A contrast-enhanced computed tomography scan confirmed a Type II PEH with an organoaxial gastric volvulus, causing complete obstruction. Following aggressive resuscitation, the patient underwent successful laparoscopic surgery. The procedure involved reduction of the herniated and volvulized stomach, complete excision of the hernia sac, and a primary posterior crural repair with pledgeted, non-absorbable sutures. A fundoplication or gastropexy was not performed. Intraoperative endoscopy confirmed successful de-rotation, a patent pylorus, and viable gastric mucosa. The patient had an uneventful recovery and remained asymptomatic with no evidence of reflux at a six-month follow-up. **Conclusion:** This case highlights the classic "acute-on-chronic" presentation of gastric volvulus secondary to a PEH. It underscores the efficacy and safety of a laparoscopic approach, which facilitates rapid recovery. Furthermore, it suggests that in carefully selected cases with a moderate-sized hiatal defect and preserved anatomy post-reduction, a meticulous primary crural repair without routine fundoplication or gastropexy can be a sufficient and durable treatment, avoiding the potential morbidity of these additional procedures.

### 1. Introduction

Gastric volvulus is defined as an abnormal rotation of the stomach of more than 180° around one of its axes. This condition can precipitate a surgical emergency with significant morbidity and mortality.<sup>1</sup> The rotation can occur along the stomach's longitudinal axis (organoaxial), which is the most

common type, or its transverse axis (mesenteroaxial).<sup>2</sup>

While primary volvulus can occur due to congenital laxity of the gastric ligaments, up to 70% of cases in adults are secondary to underlying anatomical abnormalities. The most prevalent of these is a paraesophageal hernia (PEH), which is present in over 50% of adult cases of gastric volvulus.<sup>3</sup>

A PEH involves the herniation of the gastric fundus, and potentially other abdominal organs, into the mediastinum through a widened esophageal hiatus, while the gastroesophageal junction (GEJ) remains in its normal intra-abdominal position (Type II PEH) or is displaced into the chest alongside the fundus (Type III PEH).<sup>4</sup> The presence of a significant portion of the stomach within the chest cavity, untethered by its normal ligamentous attachments, creates a permissive environment for pathological rotation, leading to volvulus.<sup>5</sup>

The clinical presentation of gastric volvulus can be acute or chronic. The acute form may present with the classic Borchardt's triad: severe epigastric pain, intractable retching without vomiting, and the inability to pass a nasogastric tube.<sup>6</sup> This presentation signifies a closed-loop obstruction and is a surgical emergency, as delayed intervention carries a mortality rate as high as 56% due to the risk of strangulation, ischemia, necrosis, and perforation.<sup>7</sup> More commonly, patients experience a chronic or "acute-on-chronic" course, with intermittent, vague symptoms such as postprandial pain, bloating, dysphagia, or early satiety, which may suddenly progress to acute obstruction.

The evolution of minimally invasive surgery has transformed the management of PEH and associated volvulus.<sup>8</sup> A laparoscopic approach offers the benefits of reduced postoperative pain, shorter hospital stays, and faster functional recovery compared to traditional open surgery. However, the technical aspects of the repair remain a subject of ongoing surgical debate. Key controversies include the necessity of mesh reinforcement for the crural repair, the routine addition of an anti-reflux procedure (fundoplication), and the role of gastropexy to prevent re-rotation. The optimal strategy must balance the goals of achieving a durable anatomical repair against the potential morbidity of each additional surgical step.<sup>9</sup>

The novelty of this case report lies in its detailed description of a successful laparoscopic primary suture repair for an acute-on-chronic gastric volvulus

without the routine addition of a fundoplication or gastropexy.<sup>10</sup> We aim to present a comprehensive analysis of the diagnostic reasoning, the step-by-step surgical technique, and the clinical decision-making that informed our management strategy. By situating this case within the context of current surgical controversies, we seek to provide valuable insights into a tailored and minimalist yet effective approach to this complex surgical problem.

## 2. Case Presentation

A 46-year-old male presented to our emergency department in July 2024 with a chief complaint of intractable vomiting for three weeks. The patient reported that for the preceding six months, he had experienced intermittent, vague upper abdominal discomfort, early satiety, and bloating, particularly after large meals. These chronic symptoms had acutely worsened over the past three weeks, progressing to the point where he was unable to tolerate any oral intake, vomiting within an hour of eating or drinking. He denied fever, hematemesis, or significant weight loss but noted increasing discomfort in the epigastric area radiating to his lower left chest. His past surgical history was significant only for a laparoscopic appendectomy in February 2024 (Table 1).

On physical examination, the patient appeared moderately ill and showed signs of dehydration, with dry mucous membranes and reduced skin turgor. His vital signs were: blood pressure 120/80 mmHg, pulse 100 beats/minute, respiratory rate 20 breaths/minute, and temperature 36.8°C. His height was 165 cm and weight was 59 kg, with a BMI of 21.7 kg/m<sup>2</sup>, indicating a normal nutritional status despite recent events. Examination of the heart and lungs was unremarkable. The abdomen was convex and soft, but there was a notable absence of bowel sounds on auscultation, raising suspicion of an obstructive process. There was mild tenderness to palpation in the epigastrium. A rectal examination revealed a lax sphincter and a collapsed ampulla.

Table 1. Patient information and clinical findings.

PARAMETER	FINDING	SIGNIFICANCE / NOTES
<div><div></div><div>Patient Demographics</div></div>		
Age	46 years	Fifth decade of life, consistent with peak incidence for secondary gastric volvulus.
Sex	Male	No significant gender predilection reported for gastric volvulus.
Body Mass Index (BMI)	21.7 kg/m <sup>2</sup>	Normal nutritional status, indicating symptoms were not prolonged enough to cause severe weight loss.
<div><div></div><div>History of Present Illness</div></div>		
Chief Complaint	Intractable postprandial vomiting	Suggests high-grade upper gastrointestinal obstruction.
Symptom Duration	Acute worsening over 3 weeks; chronic symptoms for 6 months.	Classic "acute-on-chronic" presentation, typical for intermittent volvulus becoming fixed.
Past Surgical History	Laparoscopic Appendectomy (Feb 2024)	Unlikely to be related but important for surgical planning (potential for adhesions).
<div><div></div><div>Physical Examination</div></div>		
General Appearance	Moderately ill, signs of dehydration	Indicates significant fluid loss and physiological stress.
Vital Signs	BP: 120/80 mmHg, Pulse: 100 bpm, Temp: 36.8°C	Tachycardia is a compensatory response to dehydration.
Abdominal Exam	Soft, convex, absent bowel sounds	"Silent abdomen" is a red flag for complete mechanical obstruction.
<div><div></div><div>Laboratory Findings</div></div>		
Complete Blood Count	Hgb: 18.2 g/dL, Hct: 59.6%, WBC: 8,500/mm <sup>3</sup>	Marked hemoconcentration due to severe dehydration.
Metabolic Panel	Na: 142, K: 3.2, Cl: 87, Urea: 45, Cr: 1.2	Classic hypochloremic, hypokalemic metabolic alkalosis from loss of gastric acid; pre-renal azotemia.
<div><div></div><div>Radiological Findings</div></div>		
Chest X-Ray	Retrocardiac air-fluid level; elevated left hemidiaphragm.	Highly suggestive of intrathoracic herniation of the stomach.
Abdominal MSCT	Type II PEH with 180° organoaxial volvulus; complete gastric outlet obstruction.	Definitive diagnosis, confirming anatomy and pathology for surgical planning.

Initial laboratory investigations were highly significant and guided immediate management. The results were as follows: hemoglobin 18.2 g/dL, hematocrit 59.6%, leukocytes 8,500/mm<sup>3</sup>, and platelets 219,000/mm<sup>3</sup>. The elevated hemoglobin and hematocrit were clear indicators of hemoconcentration secondary to severe dehydration from persistent vomiting. The electrolyte panel revealed a state of hypochloremic, hypokalemic metabolic alkalosis (sodium 142 mmol/L, potassium 3.2 mmol/L, chloride 87 mmol/L), a classic metabolic signature of gastric outlet obstruction. Renal function was mildly

impaired (urea 45 mg/dL, creatinine 1.2 mg/dL).

Given these findings, the patient was immediately started on aggressive intravenous fluid resuscitation with potassium and chloride repletion to correct his dehydration and metabolic derangements before any further diagnostic or therapeutic interventions. A plain chest X-ray was performed, which showed a large retrocardiac air-filled structure with an air-fluid level, and an abnormally elevated left hemidiaphragm (Figure 1). These findings were highly suggestive of a large hiatal hernia with an intrathoracic stomach.

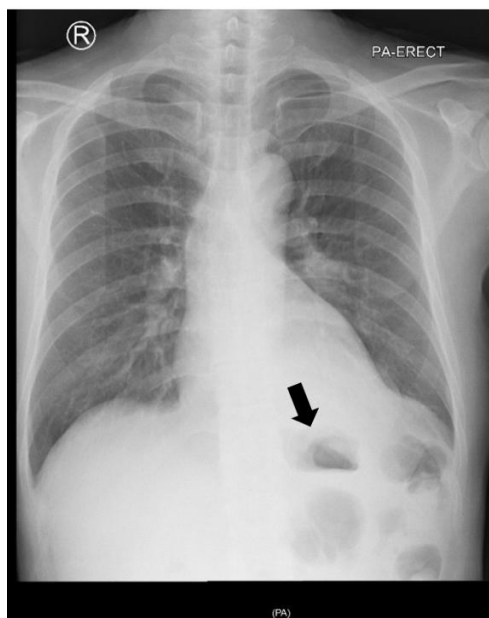


Figure 1. Chest X-ray shows left diaphragmatic hernia (black arrow).

To confirm the diagnosis and delineate the anatomy for surgical planning, a contrast-enhanced multidetector computed tomography (MSCT) scan of the abdomen and chest was performed. The MSCT revealed that the majority of the stomach had herniated into the thoracic cavity through a widened esophageal hiatus. The gastroesophageal junction was confirmed to be in a relatively normal intra-abdominal position, classifying the hernia as a Type II PEH. Critically, the scan demonstrated a 180° organoaxial rotation of the intrathoracic portion of the stomach.

The greater curvature was positioned superiorly, and there was a distinct "whirl sign" of the twisted mesentery. This volvulus resulted in severe distention of the proximal stomach and complete collapse of the distal gastric segment, causing the patient's gastric outlet obstruction. The hiatal defect was estimated to be approximately 5 cm in its largest dimension.

After 12 hours of aggressive fluid and electrolyte resuscitation, the patient's clinical condition and metabolic parameters improved significantly (Table 2). He was taken to the operating room for definitive

surgical management. A laparoscopic approach was chosen, given the patient's hemodynamic stability and the detailed anatomical roadmap provided by the CT scan. The patient was placed in a modified lithotomy (split-leg) position. Pneumoperitoneum was established, and five laparoscopic ports were placed. A Nathanson liver retractor was used to expose the hiatus. The herniated stomach, which occupied a significant portion of the left posterior mediastinum, was gently grasped and reduced back into the abdominal cavity. This maneuver simultaneously effected the de-rotation (reduction) of the organoaxial volvulus. Minimal adhesiolysis was required to free the stomach from chronic attachments within the hernia sac. The hernia sac was meticulously dissected from the mediastinal structures and the hiatal margins. It was then completely excised to prevent seroma formation and to clearly define the muscular crura of the diaphragm. The phrenoesophageal ligament was divided, and the hiatus was circumferentially dissected, clearly identifying the right and left crura. The distal esophagus was mobilized, ensuring at least 3-4 cm of intra-abdominal esophageal length without tension, which confirmed that a lengthening procedure (Collis gastroplasty) was not necessary. The hiatal defect, measuring approximately 5 cm, was repaired. A posterior cruroplasty was performed, approximating the right and left crura with three interrupted, pledgeted non-absorbable polypropylene sutures (Prolene 2-0). The use of pledgets helps to distribute tension and prevent the sutures from tearing through the muscle. The repair was calibrated over a 52-French bougie to prevent stenosis. Given the moderate defect size and the healthy appearance of the crural muscle, a mesh reinforcement was not deemed necessary. After the hiatal repair, the stomach lay in its normal anatomical position without tension. A decision was made to omit a fundoplication, as the patient had no pre-operative symptoms of GERD and a sufficient length of intra-abdominal esophagus was achieved, restoring a functional angle of His. A gastropexy was also considered unnecessary, as the secure crural repair

and the restoration of normal anatomy were deemed sufficient to prevent re-herniation and subsequent volvulus. Following the repair, intraoperative endoscopy was performed. It confirmed the successful de-rotation of the stomach, with visualization of normal-appearing gastric rugae. The endoscope passed easily through the pylorus into the duodenum, confirming the resolution of the obstruction. Most importantly, the gastric mucosa appeared pink and viable throughout, ruling out any significant ischemic injury.

The patient had an uneventful postoperative recovery. He was started on a clear liquid diet on postoperative day 1 and advanced to a soft diet on day 2. He was discharged home on postoperative day 3. At his one-month follow-up, he reported complete resolution of his previous symptoms and was tolerating a regular diet. At the six-month follow-up, he remained asymptomatic. He completed a GERD-Health-Related Quality of Life (GERD-HRQL) questionnaire and scored a 0, indicating no reflux symptoms. A follow-up barium swallow study was performed, which showed the stomach to be in a normal intra-abdominal position with no evidence of obstruction or hernia recurrence. The patient expressed great satisfaction with the outcome, stating he had "gotten his life back." The timeline of the patient event is presented in Figure 2.

### 3. Discussion

This case report details the successful laparoscopic management of an acute-on-chronic organoaxial gastric volvulus secondary to a Type II PEH.<sup>11</sup> It highlights several critical aspects of the diagnostic and therapeutic pathway, particularly the nuances of surgical decision-making in the context of modern minimally invasive surgery. The progression from a stable intra-abdominal stomach to a life-threatening gastric volvulus is a fascinating and dangerous cascade of anatomical failures, pressure dynamics, and mechanical torsion.<sup>12</sup> The process begins with the insidious weakening of the diaphragmatic hiatus, the muscular gateway between the thoracic and

abdominal cavities (Figure 3). In a healthy state, the integrity of this gateway is maintained by the phrenoesophageal ligament, a crucial fibroelastic membrane. This ligament is not a simple band but a

complex, circumferential collar that arises from both the endothoracic and transversalis fascia, effectively forming a hermetic seal or "gasket" around the distal esophagus.<sup>13</sup>

Table 2. Therapeutic intervention and follow-up.

PHASE / STEP	DETAILS	RATIONALE / OUTCOME
<b>Pre-Operative Management</b>		
Resuscitation	12 hours of aggressive intravenous fluid resuscitation with normal saline, supplemented with potassium and chloride.	<i>To correct severe dehydration, hemoconcentration, and hypochloremic, hypokalemic metabolic alkalosis, ensuring patient safety for general anesthesia.</i>
<b>Surgical Intervention: Laparoscopic Repair</b>		
1. Reduction	Gentle traction and reduction of the herniated stomach from the mediastinum into the abdominal cavity, which simultaneously de-rotated the volvulus.	<i>To restore normal anatomical position and relieve the closed-loop obstruction.</i>
2. Hernia Sac Excision	Complete dissection and excision of the large hernia sac from mediastinal structures and hiatal margins.	<i>To clearly define the muscular crura for repair and prevent post-operative seroma formation.</i>
3. Esophageal Mobilization	Circumferential dissection of the distal esophagus, achieving >3 cm of tension-free intra-abdominal length.	<i>To ensure adequate length for a tension-free repair and restore the anti-reflux barrier, confirming a Collis gastroplasty was not needed.</i>
4. Crural Repair	Posterior cruroplasty of the ~5 cm defect using three interrupted, pledgeted 2-0 polypropylene sutures. Calibrated over a 52-French bougie.	<i>To provide a durable, tension-distributed repair of the primary anatomical defect while preventing stenosis.</i>
5. Omission of Mesh	A conscious decision was made not to use mesh reinforcement.	<i>Rationale: Defect size was moderate (~5 cm) and crural tissue was robust, avoiding potential long-term mesh-related complications like erosion.</i>
6. Omission of Fundoplication	No anti-reflux procedure was performed.	<i>Rationale: Patient had no pre-operative GERD symptoms and adequate intra-abdominal esophagus was restored, avoiding risks of dysphagia or gas-bloat.</i>
7. Intraoperative Endoscopy	Endoscope passed easily into the duodenum. Gastric mucosa appeared pink and viable throughout.	<i>Crucial for confirming successful de-rotation, resolution of obstruction, and viability of the stomach, avoiding the need for gastric resection.</i>
<b>Post-Operative Course</b>		
Diet Advancement	Clear liquids on POD 1, advanced to soft diet on POD 2.	<i>Rapid advancement indicates good functional recovery and absence of obstruction.</i>
Hospital Discharge	Discharged on Post-Operative Day 3.	<i>Uneventful recovery, demonstrating the benefits of a minimally invasive approach.</i>
<b>Long-Term Follow-up</b>		
1-Month & 6-Month Follow-up	<b>Completely asymptomatic</b> , tolerating a regular diet. Expressed high satisfaction.	<i>Excellent short and medium-term clinical outcome.</i>
Objective Assessment (6 Months)	GERD-HRQL Score: <b>0</b> Barium Swallow: <b>No hernia recurrence or obstruction.</b>	<i>Objective evidence confirms the durability of the repair and validates the decision to omit a fundoplication.</i>

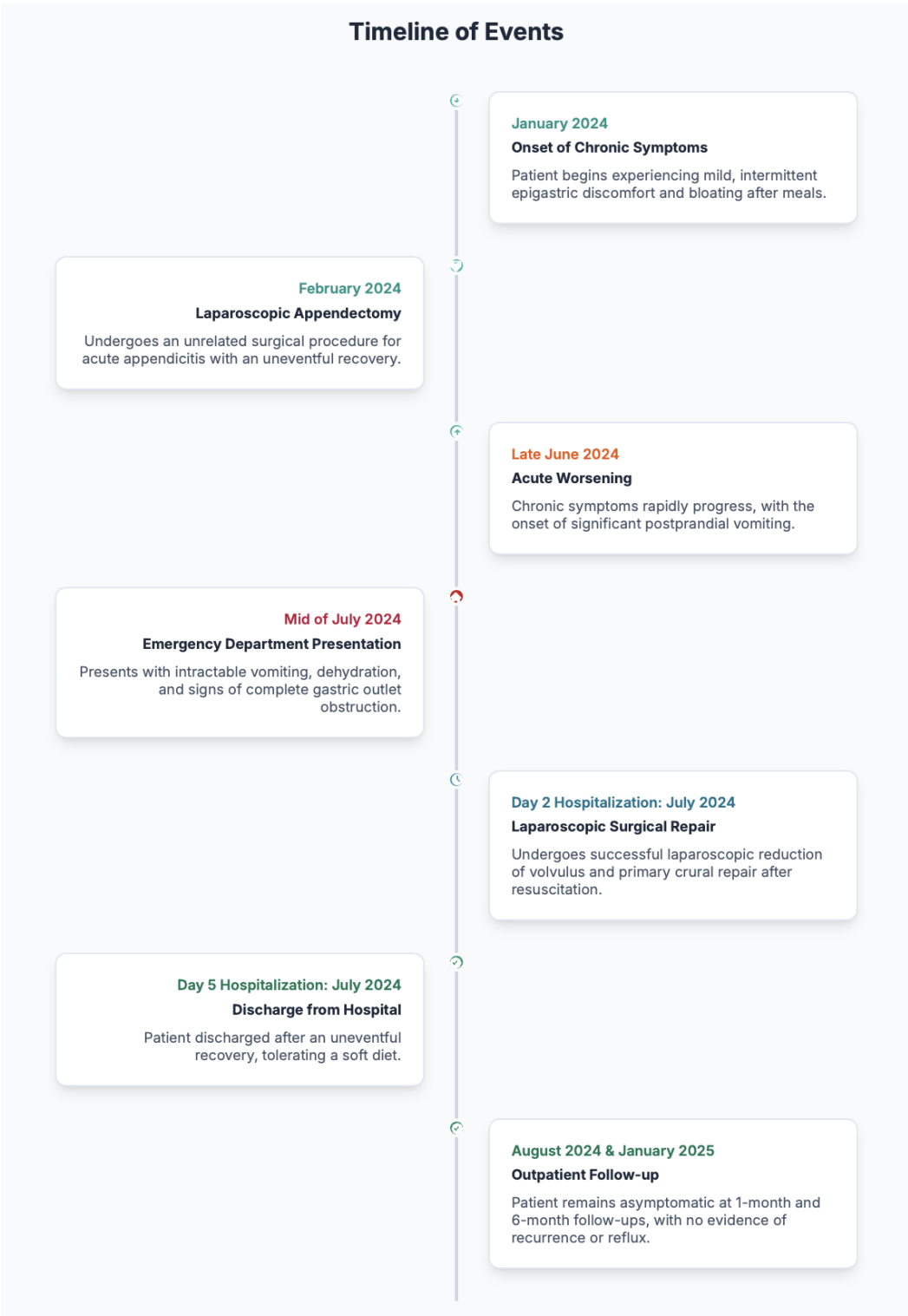

Figure 2. Timeline of events.

This structure, in concert with the muscular pinch of the diaphragmatic crura, anchors the gastroesophageal junction (GEJ) securely within the positive-pressure environment of the abdomen,

resisting the constant suction-like pull from the negative-pressure thorax.<sup>14</sup> However, with advancing age, the elastin fibers within this ligament undergo degradation, leading to a loss of tensile strength and

elasticity. This age-related attenuation is often exacerbated by conditions that chronically elevate intra-abdominal pressure, such as obesity, chronic obstructive pulmonary disease with its associated coughing, or chronic constipation.<sup>15</sup> As the phrenoesophageal ligament becomes lax and the hiatal orifice widens, the stage is set for herniation. The initial failure gives rise to a Type II paraesophageal hernia, a "true" paraesophageal hernia where the GEJ remains anchored in its correct anatomical position, but a portion of the highly mobile gastric fundus

begins to protrude through the weakened hiatus, alongside the esophagus.<sup>16</sup> This creates a precarious situation where the stomach exists simultaneously in two different pressure zones. The intrathoracic portion of the stomach is now liberated from the stabilizing influence of adjacent abdominal organs and is subject to the negative pressures of the chest, which encourages further herniation over time. This herniated fundus becomes a mobile, unstable lead point.<sup>17</sup>

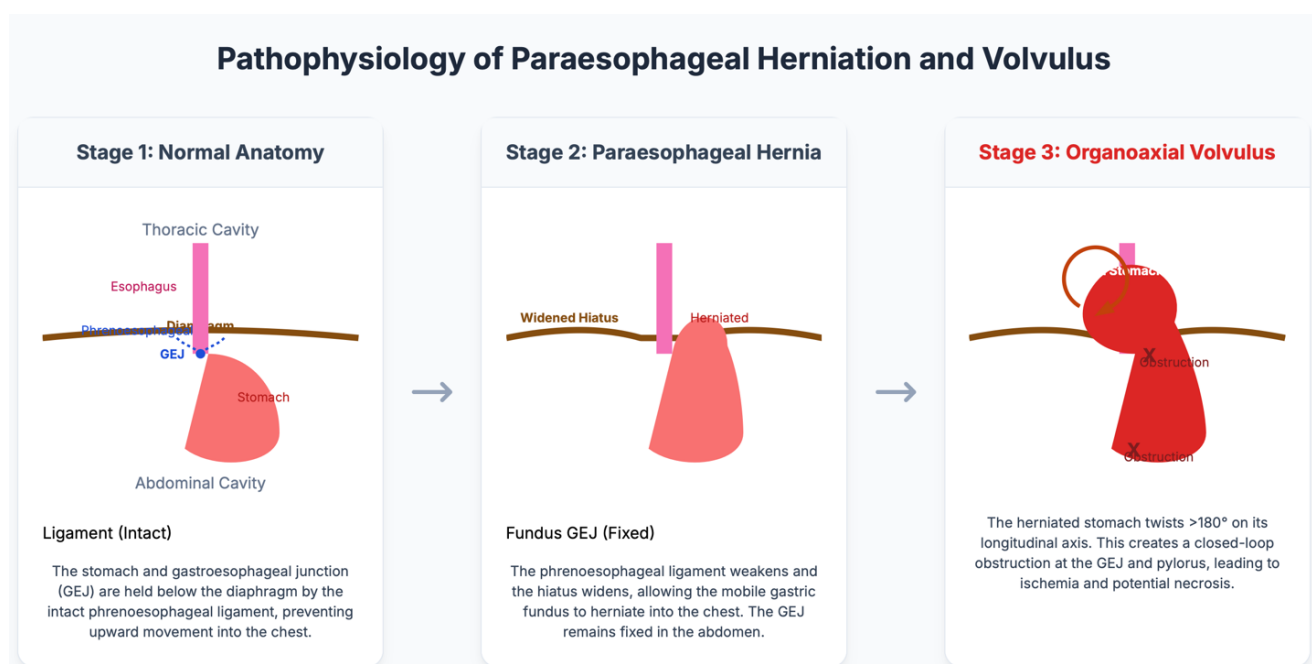


Figure 3. Pathophysiology of PEH and volvulus.

Once a substantial portion of the stomach resides within the mediastinum, it is no longer a contained, J-shaped organ but a partially untethered sac, suspended primarily by its ligamentous attachments—the gastrohepatic, gastrophrenic, gastrosplenic, and gastrocolic ligaments. This newfound mobility creates the potential for volvulus. The organoaxial volvulus, the most common type in this setting, occurs when the stomach performs a dramatic "somersault" around its longitudinal axis, an imaginary line connecting the relatively fixed GEJ and

the more mobile pylorus. The laxity of the gastrosplenic and gastrocolic ligaments allows the greater curvature of the stomach, normally positioned inferiorly, to flip upwards and forwards.<sup>17</sup> Concurrently, the lesser curvature moves downwards and backwards, completing a twist of 180 degrees or more. This torsion has immediate and catastrophic consequences. It creates a closed-loop obstruction, effectively sealing the stomach at two points: the GEJ (preventing inflow and reflux) and the pylorus (preventing outflow). Gas, fluid, and ingested food



become trapped within the rotated stomach, leading to massive distention.<sup>18</sup> This distention dramatically increases the pressure within the gastric wall, which itself can compress the small intramural blood vessels, initiating ischemia. More critically, the physical twisting of the stomach's mesentery directly strangulates the major blood vessels that travel within it—the left and right gastric arteries and the gastroepiploic arcade. The initial effect is often occlusion of the low-pressure veins, leading to severe vascular congestion, edema, and weeping of fluid.<sup>19</sup> This engorgement further compromises the high-pressure arterial inflow, accelerating the progression from ischemia to full-thickness necrosis. Without emergent surgical intervention to de-rotate the stomach, reduce the hernia, and repair the underlying hiatal defect, this vicious cycle inevitably leads to gastric gangrene, perforation, mediastinitis, and sepsis, a cascade with a grimly high mortality rate.<sup>20</sup>

Our patient's presentation is a classic example of an "acute-on-chronic" volvulus. His six-month history of vague epigastric pain and early satiety likely represented periods of intermittent, partial volvulus that spontaneously reduced (Figure 4). This chronic phase often goes undiagnosed or is misattributed to more common conditions like gastritis or peptic ulcer

disease. The final three-week course of intractable vomiting represented the "acute" component, where the volvulus became fixed and caused a complete, non-reducible obstruction. This dual presentation contrasts with Borchardt's triad, which is more characteristic of a hyperacute event without a chronic prodrome. The presence of the triad is reported in only about 70% of acute cases, and its absence should not lower suspicion. In a patient with a known hiatal hernia presenting with obstructive symptoms, CT imaging is the gold standard and should be pursued urgently. As demonstrated in our case, CT is invaluable not only for confirming the diagnosis but for delineating the type of volvulus (organoaxial), classifying the hernia type (Type II PEH), and, crucially, ruling out signs of gastric necrosis (such as pneumatosis or lack of wall enhancement), which would necessitate a more aggressive surgical approach, potentially an open laparotomy and gastrectomy. The diagnostic reasoning was further solidified by the laboratory findings of severe dehydration and metabolic derangement, which directly reflected the physiological consequences of the high-grade obstruction and mandated aggressive pre-operative optimization to ensure patient safety under anesthesia.

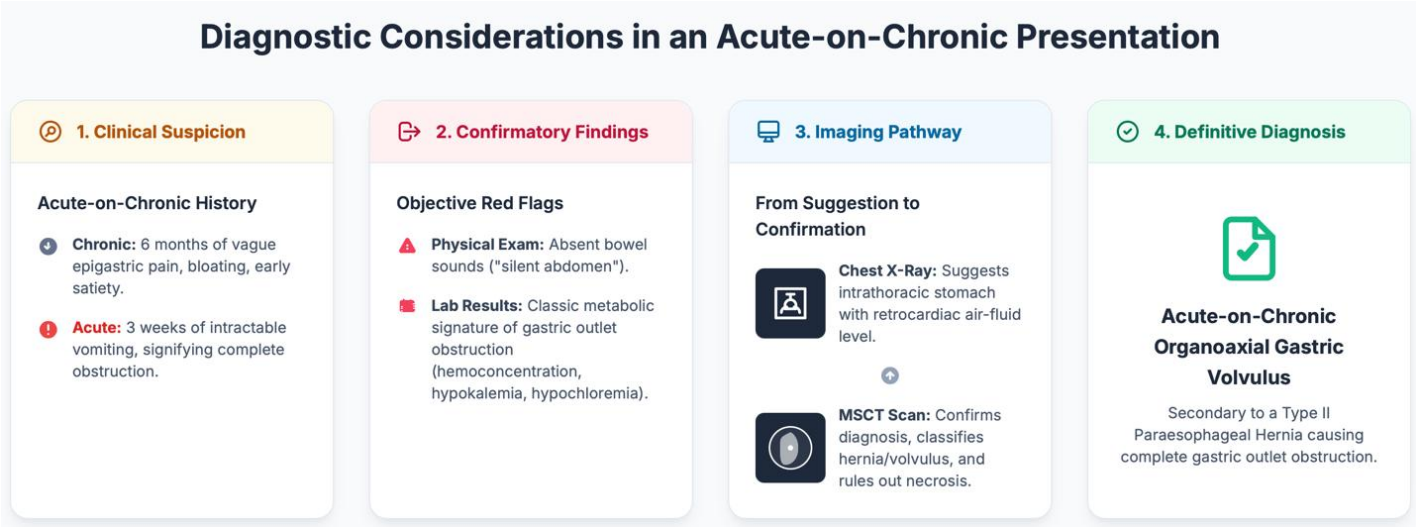


Figure 4. Diagnostic considerations in an acute-on-chronic presentation.

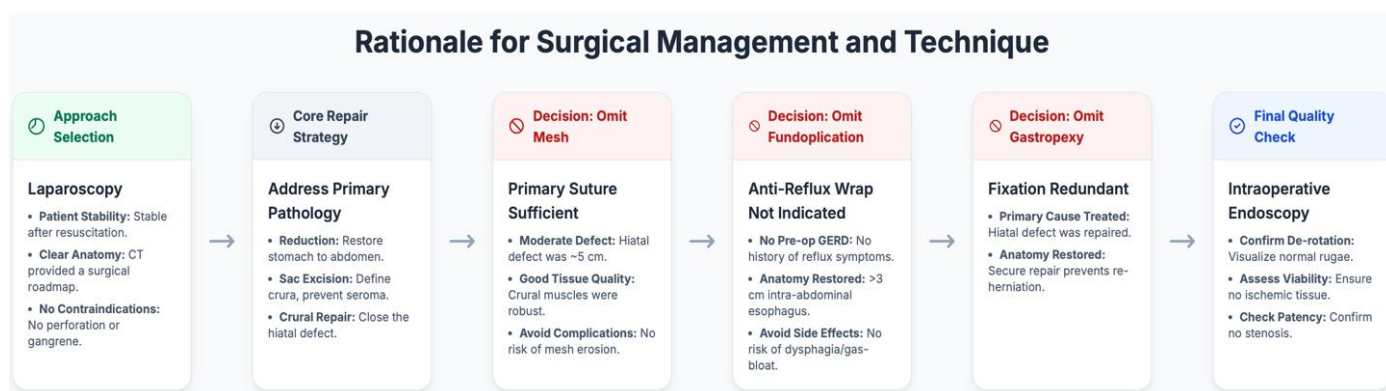


Figure 5. Rationale for surgical management and technique.

The definitive treatment for gastric volvulus is surgical. The goals are to: (1) decompress and de-rotate the stomach, (2) assess for and manage any ischemic tissue, (3) reduce the hernia, and (4) repair the anatomical defect to prevent recurrence. Our choice of a laparoscopic approach was based on the patient's hemodynamic stability and the absence of perforation or gangrene on CT imaging. The cornerstone of preventing recurrence is a tension-free, durable repair of the enlarged hiatus. Recurrence rates after PEH repair can be as high as 42%, although symptomatic recurrence is much lower. The debate between primary suture repair and mesh reinforcement is ongoing (Figure 5). While several studies suggest that mesh reinforcement lowers anatomical recurrence rates, particularly for defects >5 cm, this benefit is tempered by the risk of severe, life-altering mesh-related complications, such as esophageal erosion, stenosis, and chronic pain. For our patient, the hiatal defect was moderate (~5 cm) and the crural tissue was robust. We therefore opted for a primary posterior cruroplasty with pledgeted sutures, believing it provided a sufficiently strong repair while completely avoiding the long-term risks associated with mesh. This selective approach, reserving mesh for very large defects or attenuated tissue, is supported by a growing body of literature advocating for a tailored strategy.

The routine addition of an anti-reflux procedure (typically a Nissen or Toupet fundoplication) during PEH repair is another area of intense debate. Proponents argue that the extensive hiatal dissection required for the repair can destroy the natural anti-reflux barrier, leading to severe de novo GERD in up to 20% of patients. However, opponents argue that a meticulous hiatal repair that restores a sufficient length of intra-abdominal esophagus and recreates the angle of His may be sufficient to preserve continence. Furthermore, fundoplication carries its own risks of "gas-bloat" syndrome and dysphagia. Our patient had no pre-operative symptoms suggestive of GERD. By achieving over 3 cm of intra-abdominal esophagus and performing a sound cruroplasty, we restored the key elements of the anti-reflux mechanism. The decision to omit a fundoplication was therefore made to avoid its potential side effects. The patient's excellent six-month outcome with a GERD-HRQL score of 0 supports the validity of this selective approach.

Gastropexy, the fixation of the stomach to the anterior abdominal wall, is sometimes performed to prevent re-rotation. However, its routine use is questionable. When the volvulus is secondary to a PEH, the primary pathology is the hiatal defect itself, not inherent gastric ligament laxity. A proper reduction of the stomach into the abdominal cavity combined with a secure crural repair that prevents re-

herniation effectively eliminates the permissive space for volvulus to occur. Therefore, we believe gastropexy is an unnecessary additional step in most cases of PEH-associated volvulus and was appropriately omitted here.

Our case also highlights the indispensable role of intraoperative endoscopy. It served multiple critical functions: it allowed for decompression of the distended stomach, provided unequivocal confirmation of successful de-rotation by visualizing normal rugal folds, ensured patency of the gastric outlet, and, most importantly, allowed for direct visualization of the mucosa to confidently rule out ischemia, thereby avoiding a more extensive resection.

#### 4. Conclusion

This case of acute-on-chronic gastric volvulus secondary to a Type II paraesophageal hernia illustrates the critical importance of a high index of suspicion and timely, appropriate imaging in patients presenting with obstructive upper gastrointestinal symptoms. It showcases the safety and efficacy of a laparoscopic approach, which allows for definitive treatment with minimal morbidity and rapid functional recovery. Most significantly, this report contributes to the ongoing dialogue regarding optimal surgical technique by demonstrating that in carefully selected patients, a meticulous laparoscopic reduction and primary crural repair, without the routine addition of a fundoplication or gastropexy, can serve as a durable and sufficient treatment. This tailored surgical strategy, supported by the crucial adjunct of intraoperative endoscopy, effectively addresses the underlying pathology while avoiding the potential complications of more extensive procedures.

#### 5. References

1. Lee HY, Park JH, Kim SG. Chronic gastric volvulus with laparoscopic gastropexy after endoscopic reduction: a case report. *J Gastric Cancer*. 2015; 15(2): 147–50.
2. Kulyk V, Kritsak Y, Perepadya V, Nevmerzhytskyi V. Surgical treatment of incarcerated paraesophageal hiatal hernia complicated by necrosis and perforation of the posterior gastric fundus. *Ukr Sci Med Youth J*. 2025; 154(2): 122–7.
3. Pather K, Dowdall R, Mobley EM, Sacco J, Puri R. Definitive, urgent repair of acutely incarcerated paraesophageal hernias is comparable to an elective repair. *Surg Endosc*. 2025; 39(7): 4558–63.
4. Fernandez-Ananin S, Sacoto D, Balagué C, Guarner C, Targarona E. Recurrent and late esophageal mesh extrusion after paraesophageal hiatoplasty: a case report and review of the literature. *Int J Abdom Wall Hernia Surg*. 2020; 3(4): 158.
5. Aiolfi A, Cavalli M, Sozzi A, Lombardo F, Mendogni P, Nosotti M, et al. Paraesophageal hernia repair with laparoscopic Toupet fundoplication: impact on pulmonary function, respiratory symptoms and quality of life. *Hernia*. 2022; 26(6): 1679–85.
6. El-Magd E-SA, Elgeidie A, Elmahdy Y, El Sorogy M, Elyamany MA, Abulazm IL, et al. Impact of laparoscopic repair on type III/IV giant paraesophageal hernias: a single-center experience. *Hernia*. 2023; 27(6): 1555–70.
7. Virdiana M, Kedage V, Ubarale M, Shenoy KR. Duodenum in the right hemithorax: An unusual case of a large paraesophageal hernia. *Int J Abdom Wall Hernia Surg*. 2024.
8. Anjum N, Mohammad Mozassem A, Siraji D, Abu Sayeed M. Gastric volvulus in a 42-year-old male: a case report. *Chattagram Maa-O-Shishu Hosp Med Coll J*. 2025; 23(2): 101–3.
9. Halbart T, Maris C, Laurent S, Trieu T-H, Zeevaert J-B, Wain E. Successful endoscopic management of gastric volvulus: a case report highlighting effective treatment strategies. *Acta Gastroenterol Belg*. 2025; 88(2): 195–7.
10. Thongpiya J, Shukri A, Yingchoncharoen P, Ratra A, Das K. A successful case of endoscopic detorsion of gastric volvulus and percutaneous endoscopic gastrostomy

- placement for gastropexy in an elderly patient. *JGH Open*. 2025; 9(5): e70180.
11. Siahaan PP, Kristianto TA. Early intervention in neonatal gastric volvulus: a case report on prompt diagnosis and surgical success. *Open Access Indonesian Journal of Medical Reviews (OAIJMR)*. 2025; 5(4): 1246–56.
  12. Urbina Velázquez MA, González Flores JE, Portales Rivera CM, Cruz Méndez M, Sandoval A, Silva Cruz FM, et al. Gastric volvulus as a complication of giant hiatal hernia: a case report and literature review. *Cureus*. 2025; 17(5): e84257.
  13. Manterola C, Biel E, Rivadeneira J, Pera M, Grande L. Acute paraesophageal hernia with gastric volvulus. Results of surgical treatment: a systematic review and meta-analysis. *World J Emerg Surg*. 2025; 20(1): 41.
  14. Mustapha KA, Yahya N, Roslan TRN, Borhan MK. Unmasking gastric volvulus in the shadow of hypothyroidism. *J ASEAN Fed Endocr Soc*. 2025; 40(S1): 44–5.
  15. Lang A, Böhme S, Kuhn V, Rayher S, Lautersack O. Diagnostic challenges of a 360° gastric dilatation volvulus in a dog: a case report. *Tierarztl Prax Ausg K Kleintiere Heimtiere*. 2025; 53(3): 167–72.
  16. Alomari MM, Shahan RB, Makhoul TZ, Farah RE, Farah RE, Maraqa MA. Gastric volvulus as a rare complication of hiatal hernia: a rare case report. *Int J Surg Case Rep*. 2025; 133(111582): 111582.
  17. Mazuela LO, López MV, Bolaños EL, Morales-Conde S. Minimally invasive repair of intrathoracic gastric volvulus: a delayed surgical complication after peritonectomy and HIPEC. *Cir Esp (Engl Ed)*. 2025; 800156.
  18. Biswas R, Kumar S, Gupta S, Khanna S. Two hernias, one patient: a case of organoaxial gastric volvulus in a paraesophageal hernia with an incisional hernia. *Cureus*. 2025.
  19. Khan MN, Waqar M, Yousaf S, Imran A. Gastric volvulus and a myriad of anomalies: Asplenia, jejunal diverticulosis and absent colonic attachments: a rare case report. *Turk J Surg*. 2025.
  20. Koo GPY, Tan MY, Goh MC. A rare case of pediatric presentation of a congenital hiatal hernia with gastric volvulus: an emergency department perspective. *Pediatr Emerg Med J*. 2025.