



Bioscientia Medicina: Journal of Biomedicine & Translational Research

Journal Homepage: www.bioscmed.com

Lung Abscess Carcinomatous

Upi Puspita^{1*}, Fauzar², Roza Kurniati²

¹Internal Medicine Resident, Andalas University, Padang, Indonesia

²Pulmonologi Subdivisions, Departement of Internal Medicine, M. Djamil Hospital, Padang, Indonesia

ARTICLE INFO

Keywords:

Squamous cell lung carcinoma,
Lung abscess,
Carcinomatous abscess

*Corresponding author:

Upi Puspita

E-mail address:

upipuspita@gmail.com

All authors have reviewed and approved the final version of the manuscript.

<https://doi.org/10.32539/bsm.v5i7.335>

ABSTRACT

Introduction: Pulmonary malignancies may easily be overlooked and valuable time may be lost. Lung cancer is sometimes diagnosed as a tuberculous cavity or an abscess. Abscess formation can appear in several different ways. Carcinoma that occurs in medium-sized bronchi causes partial bronchial obstruction, atelectasis, and infection due to retention. Inflammation can progress to damage to lung tissue, resulting the formation of multiple suppurative foci or more localized lung abscess. The link between lung abscess and lung cancer has been known, but the presence of malignancy in lung abscesses often undiagnosed. Obstruction from lung cancer can predispose to the development of a lung abscess. Case of a 54 year old man with increased pain at the right chest when breathing in since two months. On physical examination, it was found decreased of fremitus at the right hemithorax, deafness and decreased breath sounds as high as the II - V thoracic right hemithorax. Thorax CT-scan showed a round, homogeneous (HU: 17-30), with a cavity-like image with air fluid level, size: 7,88 cm x 8,2 cm x 9,29 cm and honey comb appearance around it. On the examination of TTNA (Transthoracic Needle Aspiration) results obtained Squamous Cell Carcinoma. A lobectomy is planned for the patient. Conclusion : We reported a rare case, a 54 year old male patient, with the diagnosis of Carcinomatous Lung Abscess. This case report was prepared with the aim of increasing awareness of malignancy in patients with a clinical presentation of abscesses, especially in old age.

1. Introduction

Lung cancer is the leading cause of cancer-related deaths worldwide. Lung carcinoma is the second most common cancer diagnosis by gender, behind prostate cancer for men and breast cancer for women. Non-small cell lung cancer (NSCLC) accounts for 85% of all lung cancers. Squamous Cell Lung Carcinoma (SQCLC) is a type of NSCLC that represent about 25% – 30% of all lung cancers. Lung cancer is often not diagnosed until advanced stage disease is present. Advanced lung cancer has extremely poor prognosis, with a 5-year survival of only 5%.^{1,2,3}

Smoking is the most common cause of lung cancer. It is estimated that 90% of the cases of lung cancer are attributable to smoking. The risk is highest in males

who smoke. The risk is further compounded with exposure to other carcinogens, such as asbestos. Other factors include radiation for non-lung cancer treatment, especially non-Hodgkins lymphoma and breast cancer. Exposure to metals, such as chromium, nickel, and arsenic, and polycyclic aromatic hydrocarbons also is associated with lung cancer. Lung diseases like idiopathic pulmonary fibrosis increase risk of lung cancer independent of smoking.^{2,3,4}

Pulmonary abscesses can have a multifactorial etiology ranging from infection to endobronchial obstruction by foreign bodies or malignant lesions. Pulmonary abscesses can be classified as acute (up to 6 weeks) and chronic (> 6 weeks) according to their duration. It is not common for a bronchial carcinoma to present with the appearance of a lung

abscess. Abscess formation may arise in several different ways. A carcinoma occurring in a medium-sized bronchus causes partial bronchial obstruction, atelectasis, and retention infection. The inflammation may progress to destruction of lung tissue, resulting in the formation of many suppurative foci or a more localized lung abscess. Lung abscesses associated with lung cancer also can be caused by post obstructive pneumonia leading to abscess formation.^{3,5,6}

Carcinomatous lung abscess has been introduced since 1934. Research C Strang and J. Simpson, in 1953 where they studied from 1940 to 1951, found 70 cases of neoplastic abscess. These cases show that, when a lung abscess does not improve with proper medical management, there is a suspicion of lung cancer. Patients with symptomatic abscesses are malignant in about 7% to 18% of cases, but other reports suggest that the incidence may be as high as 36%. In patients older than 45 years, this incidence increases by 33%.⁶

Clinical findings

A 54 year old male patient is treated in the internal medicine ward of dr. M. Djamil Padang. Patients experience increased right chest pain when breathing in since two months before admission to hospital, sometimes accompanied by shortness of breath, cough and fever. There has been a decrease in appetite and body weight of more than 10 kg in the last two months. The patient works as a farmer, and has a history of smoking since 30 years ago, spending two packs / day

with a moderate Brinkman Index (200-599).

Physical examination of the lungs found a decreased right hemithoracic fremitus, deafness and decreased breath sounds as high as the thoracic II - V right hemithoracic, and clubbing fingers were found. From routine laboratory examinations, it was found that there was leukocytosis with neutrophilia shift to right. From X-ray examination of the Thorax (PA), there was an inhomogeneous semi-opaque connection in the upper field of the right lung with an indefinite irregular border, the impression of a suspect mass in the upper field of the right lung (Figure 1). Thoracic ultrasound examination revealed a dextra lung abscess with a differential diagnosis of the mass.

The patient was subjected to a CT scan of the chest where the lesions were round, homogeneous (HU: 17-30), with a cavity-like image with an air fluid level, with a size: 7.88 cm x 8.2 cm x 9.29 cm and honey comb appearance around it (Figures 2 and 3). The impression of CT scan of the chest is a lung abscess with right lung bronchiectasis, with a differential diagnosis of aspergilloma. The location of the lung abscess in this patient was in the posterior segment of the upper lobe in the right hemithorax. The patient continued with a TTNA (Transthoracic Needle Aspiration) examination with the results of Squamous Cell Carcinoma. Sputum culture examination revealed a Staphylococcus. After screening and no metastases were found, the patient was concluded in stage IIIA and planned for a lobectomy.

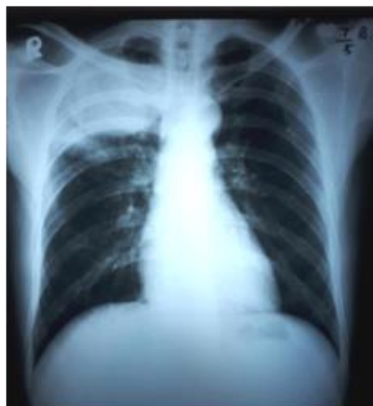

Figure 1. Thoracic X-ray showing inhomogeneous semi-opaque junction with irregular borders in the upper field of the right lung.

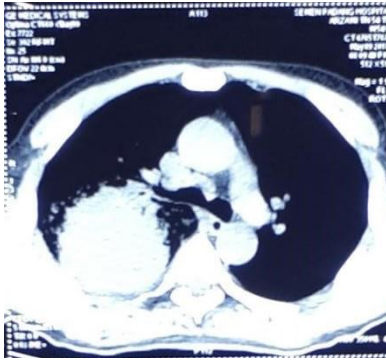


Figure 2. mediastinum window

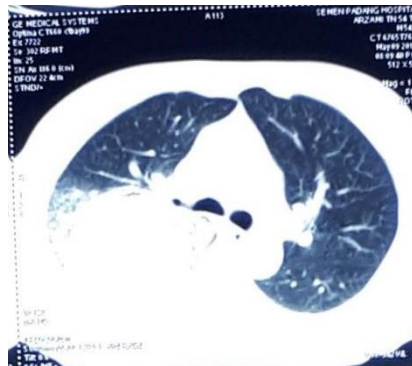

Figure 3. lung window

2. Discussion

The onset of lung abscess can be acute or chronic. Called acute if it occurs less than six weeks. In this patient, lung abscess was classified as chronic, complaints had been felt since eight weeks before entering the hospital. Long-lasting pulmonary disorders can lead to chronic hypoxemia. This is indicated on the patient's physical examination found clubbing finger. Many researchers agree that a common factor in most types of clubbing is distal vasodilation, which results in increased blood flow to the distal part of the digit. Vasodilation can be caused by circulating or local vasodilators, neural mechanisms, response to hypoxemia, or genetic predisposition. ⁸

From routine laboratory examinations, it was found that there was leukocytosis with neutrophilia shift to right which indicated that there was a chronic infection in this patient. Meanwhile, the sputum culture examination found the *Staphylococcus* culture. According to Ivan Kuhajda, et al (2015), 90% of the

incidence of lung abscess is a mixture of anaerobic and aerobic bacteria. In the management of this patient for anaerobic bacteria, metronidazole antibiotics were selected, which have bactericidal, amebicidal and trichomonocidal properties, while for aerobic bacteria, ceftriaxone, which is a third-generation cephalosporin class of antibiotics, has a bactericidal effect by interfering with the synthesis of bacterial cell walls by activating autolysis enzymes on the walls of bacterial cells.^{9,10}

The discovery of antibiotics in the last 40 years, provides new management for the management of lung abscesses. Currently, antibiotics are the cornerstone of treatment for lung abscesses and a large proportion of patients (80-95%) respond to antibiotic therapy. Lung abscess therapy failure is due to persistence of sepsis and / or abscess complications, and sometimes requires drainage by invasive techniques (percutaneous, endoscopic or surgical) or open surgical removal of lung lesions in patients in good general

condition.¹¹

The patient underwent a chest CT scan with the impression of lung abscess and bronchiectasis. Lung abscess in the patient was confirmed by Hounsfield Unit assessment (HU 17-30) which showed the mass on the CT scan image was an abscess. The location of the lung abscess in this patient was in the posterior segment of the upper lobe and occurred in the right hemithorax. As many as 75% of cases of lung abscess due to aspiration occur most frequently in the posterior segment of the upper lobe and lower lobe apical segments, and often occur in the right lung. This is because the right main bronchus is straighter than the left.^{8,9}

Bronchiectasis in patients was diagnosed after finding a honey comb appearance on CT scan of the chest. Bronchiectasis is a radiological or pathological diagnosis characterized by abnormal and irreversible dilatation of the bronchi due to chronic inflammation of the bronchi. The bronchi that are dilated are those with a diameter of > 2 mm. Thoracic CT scan provides 95% specificity and sensitivity in the diagnosis of bronchiectasis. Bronchiectasis can be caused by a variety of factors. Predisposing factors in these patients can be due to primary infection (Staphylococcus bacteria), and smoking habits. Smoking habits in patients can affect mucociliary transport, humoral and cellular defenses, and airway epithelial cell function. This can aggravate the respiratory tract infection in the patient.¹²

The patient continued with TTNA examination with the results of Squamous Cell Carcinoma. Complaints of prolonged cough, decreased appetite and weight loss of more than 10 kg within two months accompanied by pain in the right chest which increases when inhaling leads to suspicion of a pulmonary malignant process that may occur at this time. Risk factors of the patient such as active smoking and exposure to pesticides in daily work also increase the risk of malignancy in patients. In the patient continued abdominal ultrasound examination to rule out the risk of metastasis. The patient did not find nodules in the lymph nodes and metastases in other organs and the

patient was concluded with stage IIIA and planned for lobectomy.^{11,13,14}

The occurrence of a lung abscess in this patient could be a coincidence of 2 different diseases, but on the other side lung cancer can also cause lung abscesses. The most common occurrence of lung abscesses is bronchogenic lung abscess due to aspiration, stasis of secretions, foreign bodies, tumors, and bronchial structures. This situation causes bronchial obstruction and the carrying of virulent organisms that will cause infection in the area distal to the obstruction. In an upright state, the aspirated material will flow into the medial or posterior segment of the inferior lobe of the right lung, but when lying down the aspirate will go to the apical segment of the superior lobe or the superior segment of the inferior lobe of the right lung, only occasionally the aspirate can flow into the lung left.^{8,11}

Although radiology is very helpful in raising the suspicion of lung cancer, it cannot reliably differentiate between cavitory tumors, carcinomatous abscesses and abscesses alone. The diagnosis of squamous cell carcinoma is obtained after the cancer cells are seen under a microscope. Cavities with thickened and irregular walls are more likely to be associated with malignancy, but this is not always the case.^{2,3}

Approximately 50% to 60% of carcinomatous lung abscesses occur in the posterior segment of the upper lobe and the superior segment of the upper lobe, the same bronchopulmonary segment associated with lung abscess due to aspiration. This makes differentiation of a carcinomatous lung abscess from an aspirated pulmonary abscess difficult. Pulmonary abscess has a multifactorial etiology. Lung abscess concurrent with lung cancer should be considered in the differential diagnosis especially in patients who are over 45 years old and have a history of smoking.^{2,3}

In most cases a chest CT scan is sufficient to diagnose and treat a lung abscess but in cases where lung cancer is suspected to be present simultaneously, either TTNA, TTB or bronchoscopy may be required to make the diagnosis. In this case, the histological type of lung cancer associated with lung abscess was

squamous cell carcinoma and it is the most common histological type of lung cancer associated with lung abscess. ³

After confirming the diagnosis, the stage of the cancer is determined. Cancer assessment allows prediction of patient outcome, and helps decide the best treatment options. The stage of squamous cell carcinoma of the lung is based on the TNM system (Tumor, Node, Metastasis). The prognosis for Squamous Cell Lung Carcinoma for the next five years of survival depends largely on Performance status (Karnofsky scale), extent of disease and weight loss in the last six months. ^{5,13}

The mortality rate from lung abscesses has been reported to be approximately 4–5%. Therefore, surgical procedures, although high-risk, have sometimes been performed to improve the clinical course of lung cancer patients with lung abscesses carcinomatous. Yamanashi K et al, 2017 consider surgery for lung cancer with lung abscesses if the patients are eligible for surgery. Surgical procedures for advanced-stage non-small cell lung cancer patients with lung abscesses, although high-risk, led to satisfactory post-operative mortality rates and acceptable prognoses. ⁷

3. Conclusion

We have reported a rare case, a 54 year old male patient, with the diagnosis of Lung Abscess Carcinomatous, a case of lung cancer with a clinical presentation of abscess. This case report was prepared with the aim of increasing awareness of malignancy in patients with a clinical presentation of abscesses, especially in old age. When one considers the causation of lung abscess, bronchial carcinoma ranks quite high as an etiological factor.

4. Acknowledgment

This article does not contain any conflict of interest

5. Reference

1. de Groot PM, Wu CC, Carter BW, Munden RF. The epidemiology of lung cancer. *Transl Lung Cancer Res.* 2018;7(3):220-3
2. Drilon A, Rekhtman N, Ladanyi M, Paik P. Squamous-Cell Carcinomas Of The Lung: Emerging Biology, Controversies, And The Promise Of Targeted Therapy. *Lancet Oncol.* 2013;10:418-26
3. Sabbula BR, Anjum F. Squamous Cell Lung Cancer. *StatPearls Publishing,* 2020:1-13
4. Siddiqui F, Siddiqui AH. Lung Cancer. *StatPearls Publishing.* November 2020 : 1-32
5. Agarwal A, Batra S, Verma A, Vaish AK. Lung cancer with multiple lung abscesses: An unusual presentation. *Int J Res Med Sci.* 2018;6:719-22.
6. Hendriks LEL, Hochstenbag MMH, Lalji UC., Dingemans AMC. A pulmonary abscess, beware of lung cancer. *Respiratory Medicine CME.* 2011;4:157-9.
7. Yamanashi K, Okumura N, Takahashi A, Nakashima T and Matsuoka T. Surgical and survival outcomes of lung cancer patients with intratumoral lung abscesses. *Journal of Cardiothoracic Surgery.* 2017;12(44):1-6
8. Rasyid, Ahmad. Abses Paru dalam Buku Ajar Ilmu Penyakit Dalam. Jilid II. Edisi VI. Jakarta, 2014:1651-7
9. Kuhajda I, Zarogoulidis K, Tsirgogianni K, Tsavlis D, Kioumis I, Kosmidis C. et al. Lung abscess-etiology, diagnostic and treatment options. *Annals of Translational Medicine.* 2015;3(13) : 1-9
10. Mustafa M, Iftikhar HM., Muniandy RK, Hamid SA, Sien MM, ootha N. Lung Abscess: Diagnosis, Treatment and Mortality. *International Journal of Pharmaceutical Science Invention.* 2015;4(2): 37-41
11. Loukeri A, Kampolis CF, Tomos P, Papapetrou D, Pantazoupoulus I, Tzagkaraki A, et al.

- Diagnosis, treatment and prognosis of lung abscess. *Pneumon*. 2015;28(1) : 54-60
12. Rahmatullah, Pasiyan. Bronkiectasis dalam Buku Ajar Ilmu Penyakit Dalam. Jilid II. Edisi VI. Jakarta. 2014:1682-9
 13. Lemjabbar-Alaouia H, Hassana O, Yanga YW, and Buchanana P. Lung cancer: biology and treatment options. *Biochim Biophys Acta*. 2015 December ; 1856(2): 189–210
 14. Travis WD, Brambilla E, Nicholson AG, Yatabe Y, Austin JH, Beasley MB, et al. The 2015 World Health Organization Classification of Lung Tumors. *J Thorac Oncol*. 2015;10: 1243–60