



## Bioscientia Medicina: Journal of Biomedicine & Translational Research

Journal Homepage: [www.bioscmed.com](http://www.bioscmed.com)

### Prepyloric Stricture in a 5-Year Old Infant Caused by Corrosive Injury: A Case Report

Alfi Maido Alius<sup>1\*</sup>, Yusri Dianne Jurnalís<sup>1</sup>, Jon Efendi<sup>2</sup>

<sup>1</sup>Department of Child Health, Faculty of Medicine, Universitas Andalas/Dr. M. Djamil General Hospital, Padang, Indonesia

<sup>2</sup>Department of Surgery, Faculty of Medicine, Universitas Andalas/Dr. M. Djamil General Hospital, Padang, Indonesia

#### ARTICLE INFO

##### Keywords:

Corrosive ingestion  
Prepyloric stricture  
Corrosive injury  
Case report

##### \*Corresponding author:

Alfi Maido Alius

##### E-mail address:

[alfymaydo@gmail.com](mailto:alfymaydo@gmail.com)

All authors have reviewed and approved the final version of the manuscript.

<https://doi.org/10.37275/bsm.v6i12.611>

#### ABSTRACT

**Background:** The incidence of corrosive ingestion is high and largely unreported in developing countries due to lack of parental supervision and careless storing of these chemicals at home. **Case presentation:** A 5 years, 1-month-old boy came to the outpatient clinic department of pediatric Dr. M. Djamil General Hospital with a chief complaint of recurrent vomit since 6 weeks before admission. There was a history of ingested accumulator water 1,5 months before admission. The patient vomits every day, especially after eating and drinking. **Conclusion:** The most common symptoms are vomiting, feeding problems in oral intake, and rapid weight loss. The clinical diagnosis of prepyloric stricture is based on the history of the disease, physical examination, and supporting the investigation. Treatment of gastric outlet obstruction caused by corrosive ingestion should be treated surgically.

#### 1. Introduction

Corrosive or caustic substances are a group of chemicals capable of causing tissue injury upon contact due to a chemical reaction. Worldwide, corrosive injury to the upper gastrointestinal tract is a clinical problem. Corrosive injuries occur in 80% of children due to inadvertent consumption of caustic materials. Alkaline injury is more common in western countries, while in developing countries where acid is easily accessible, acid injury is more common.<sup>1</sup>

In many areas of the world, ingestion of corrosive agents is still a broad issue, with an expected rate in the United States of 5000-15000 cases per year. This problem is seen both in developing countries and in

urban areas of developed countries.<sup>2</sup> Accidental exposure to these substances occurs as a result of inadequate parental supervision and indiscriminate storage of substances at home. This causes children to be very susceptible to exposure to these substances.<sup>3</sup>

Most patients present with mild injuries that recover without sequels, but injuries due to massive ingestion of strong corrosive substances result in high mortality rates. Complications such as hemorrhage, digestive perforation, aortoenteric fistula, or gastrocolic fistula may occur in patients surviving the initial event during the first 2-3 weeks after ingestion.

In the long term, the development of pharyngeal, esophageal, or gastric strictures may compromise nutritional outcomes.<sup>4,5</sup>

The most well-known complication of ingestion of caustic acid is gastric outlet obstruction or pyloric stenosis. This occurs due to accumulated corrosive agents and gastric reflex (pylorus spasm) after ingestion. Generally, stenosis occurs in the pylorus and antrum. Local reactions, esophageal damage, and gastric injury, respectively, can result from the ingestion of corrosive acids. Cases of isolated injury to the abdomen causing pyloric stenosis are very rare, with only 3.8% of all cases of corrosive injury causing isolated injury to the abdomen.<sup>3</sup>

As an emergency measure and delayed reconstruction, surgery has a very important role. Obviously, patients require urgent surgery in the acute phase if there is evidence of perforation. Usually, severe injury at laparotomy is experienced by patients with acidosis, shock, coagulation disorders, and ingestion of large amounts of corrosive substances. In such cases, early surgical intervention may prove beneficial.<sup>6,7,8</sup>

## 2. Case Presentation

A 5-years 1-month-old boy came to the outpatient clinic department of pediatric Dr. M. Djamil General Hospital with a chief complaint of recurrent vomit since 6 weeks before admission. Children ingested Accu water  $\pm$  1,5 months before admission, the amount was  $\pm$   $\frac{1}{4}$  cup, and then he vomited blackishly. The patient vomits every day, especially after eating and drinking. The amount was a quarter-a-half of a glass/times. Vomit was not mixed with blood, accompanied by pain in swallowing. Sometimes  $\frac{1}{2}$ -1 hour after eating, a child would spit back some food. This patient has never been treated before.

The patient is also complaining of abdominal pain intermittently since  $\pm$  20 days before admission, especially in the epigastrium region. No fever, breathlessness, seizure, or chest pain. There is a decrease in body weight to 4 kg in 1,5 months. Micturition and defecation were within the normal

limit.

The patient is the second child of two siblings, normal delivery assisted by a midwife, a term, with birth body weight 3700 grams, body length 50 cm, directly cried. Basic immunization was complete, BCG scar was present. Booster and non-PPI immunizations do not exist. The history of growth and development was normal. Hygiene and sanitation were good.

On physical examination, the patient looked moderately ill and alert. Blood pressure was 100/70 mm Hg, and pulse rate was 100 times per minute, respiratory rate was 22 times per minute, body temperature was 37°C. No pallor, edema, jaundice, or cyanosis. Body weight was 12 kg, body height was 105 cm, and MUAC was 13.5 cm. Weight for age (W/A) 67 %, height for age (H/A) 95 %, and weight for height (W/H) of 71 %, with the impression of being undernourished. The skin was warm, and the turgor returned quickly. No enlargement of lymph nodes. Head round symmetrical. Black hair didn't easily fall out. The eyes didn't look sunken. The conjunctiva was not pale, the sclera was not icteric, the pupil was isokor with a diameter of 2 mm, and the light reflex was positive and normal. Tonsils T1-T1 was hyperemic. The posterior pharyngeal wall was hyperemic. There was no ulcer in the mucous of the mouth. His lip was wet. JVP was 5-2 cmH<sub>2</sub>O.

On lung examination, normo chest, symmetrical, no retraction, breath sounds vesicular, there were no rales and wheezing. There was no distension at the abdomen, no tenderness in epigastrium, liver, and spleen not palpable, turgor was returned fast, percussion timpani, bowel sound was normal. Acral was warm, no cyanosis, no edema, capillary refilling was good, normal physiological reflexes, and there are no pathological reflexes.

Based on laboratory finding, haemoglobin 12,9 g/dl, leukocytes 10,740/mm<sup>3</sup>, platelets 368,000/mm<sup>3</sup>, differential count 0/1/3/39/47/10, sodium: 139 mmol/L, potassium: 4,4 mmol/L, Calcium: 9,8 mg/dl, random blood glucose 90 mg/dl, albumin 3 gr/dl. Based on those findings, the patient was diagnosed as observed hematemesis and corrosive

gastritis due to acid ingestion (Accu water) with differential diagnosis suspect acute gastritis or peptic ulcer and undernourished.

Patient was treated with Total parenteral nutrition IVFD D 12,5% + electrolyte 30 cc/hours + aminofuchsin ped 5% 13,7 cc/hours, ranitide (IV) 2 x

15 mg, omeprazole (IV) 1 x 15 mg and plan to upper endoscopy. The result of esophagogastroduodenoscopy was antrum-pyloric stricture. They found cicatrix in the antrum. The child was planned to perform a bypass gastro duodenostomy operation.

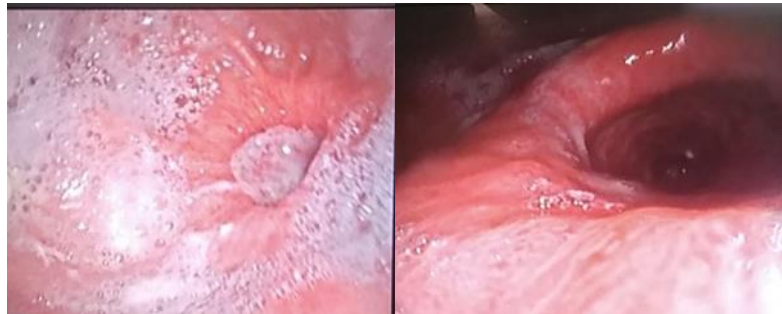


Figure 1. Esophagogastroduodenostomy.

On 7<sup>th</sup> in warded, the patient was surgery performed. Condition after surgery there was no fever, shortness of breath, seizures, vomiting, and bleeding. Pain at the incision was present. Urination was in sufficient quantities, diuresis 3,6 cc/kg/hr. Moderately ill, conscious, pulse rate 100 times per minute, respiratory rate 25 times per minute, body temperature 36,6°C, the conjunctiva was not anemic, sclera was not icteric. There was no abnormality found on the heart and lungs, no abdominal distension. Surgical wound bandages were closed, the bleeding did not exist, and the Extremities were warm with good perfusion.

The patient inward in PICU for one day. One day after surgery, the patient tried to drink liquid meals step by step with good tolerance. 17 days after surgery, the patient was allowed to go home.

### 3. Discussion

This study presents a case of a 5-year 1-month-old boy with pyloric stenosis due to caustic acid ingestion (car battery water/ Accu water). The diagnosis was made based on the history of ingestion of Accu water and non-bilious vomiting, especially after eating. On physical examination, we didn't find

signs and symptoms of dehydration. Vomiting and decreased oral intake remain the most notable features after acid burns in children. Nausea, vomiting, anorexia, and hematemesis usually continue for 24-48 hours. The patient usually responds to conservative treatment in the acute phase, although anorexia persists for one to two weeks. After a latent period of 4-6 weeks, the patient presents again with complaints of persistent vomiting, early satiety, and post-prandial fullness.<sup>4,5</sup> In this study, vomit mixed food was found for the first time hospitalized and resolved with symptomatic therapy.

Vomit was recurrent 6 weeks after the incident, and he had difficulty eating but didn't have any dehydration symptoms. Shukla reported a case of 4 children with a history of ingestion of toilet cleaner (hydrochloric acid). They were treated with conservative therapy for 3 to 6 weeks, but three patients presented non-bilious vomit after each feed, decreased body weight, and dehydration after that.<sup>6</sup>

Endoscopy is an effective technique to determine the presence of esophageal and gastric damage and to avoid unnecessary treatment in patients with no or mild injury.<sup>7</sup>In this case, we performed an endoscopy, and it turned out that it is really helpful in diagnosing

patients accurately. In our case, we found stenosis in pyloric. Gastric outlet obstruction has an incidence of 5%, mainly in the prepyloric area, where prolonged contact with the antral mucosa due to pyloric spasms and to resulting pooling of the caustic agent in this region usually results in stricture in more than 60% of patients.<sup>8</sup>

Pyloric stenosis without esophageal involvement is rare, but it is a well-known complication of corrosive acid ingestion. There is a tendency for acids to lick the esophagus and bite the pyloric antrum. Once in the stomach, the acid tends to follow the natural curve of the lesser curvature to pool in the antrum. This pooling is aggravated by reflex pylorospasm. Therefore, gastric burns mostly occur in the antrum and pylorus.<sup>9</sup> In our patient, there was a pain in swallowing. On physical examination, we found hyperemic in the tonsil and posterior pharyngeal wall. The literature said that depending on the injured area, pain may arise in the oropharynx.<sup>2</sup> This may be caused by odynophagia in this patient and hyperemic in physical examination.

Plain radiograph of the chest and abdomen and water-soluble contrast examination of the upper GI tract may be required during the acute phase to look for perforation.<sup>10</sup> Gastric dilatation was found, and there was air in the distal gastric but in limited volume. There was the distribution of bowel air until the distal part of the rectum. There was no air-fluid level and free air with the conclusion; of partial obstruction on pylori duodenal suspicious pyloric stenosis.

The nature, amount, concentration, duration of contact of the acid in the stomach, the amount of food in the stomach, and the way of swallowing determine the degree of mucosal damage.<sup>9</sup> Strong acids reaching the stomach may cause perforation in 24-48 hours if a large volume and if the organ is empty. The perforation case 2 hours after ingestion in children 2 years old was reported in Turkey<sup>11</sup> and in children 3 years old who accidental ingestion of HCL in Pakistan.<sup>12</sup> Our patient suggests suffering in grade 2 or 3 injuries. Based on the literature, patient with

grade 2 or grade 3 injury has a greater risk of developing complications such as strictures or perforation.<sup>9</sup> Nagi et al.<sup>10</sup> also said that most patients with grades 2B and 3 injuries develop strictures, while those with grades 1 and 2A injury recover without sequelae. The chances for the development of the stricture are about 10-30% in the grade 2 injury and about 40-70% in the grade 3 injury.<sup>13,14</sup>

Extensive damage to the gastrointestinal tract hinders physiological nutrition in these patients. Nutrition is life-maintaining therapy in patients who cannot take food and are disposed to a risk of malnutrition. Documented effects from artificial feeding in patients intoxicated with corrosive substances are reduction of infections, reduction of predisposition to developing aspiration pneumonia, reduction of the risk for pulmonary embolism, and economic reasons. The type of artificial nutrition depends on the degree of esophageal or gastric damage seen by endoscopy. In patients with 1 and 2A degrees of damage, total parenteral nutrition in the first 24-48 hours is followed by a liquid diet until the 10<sup>th</sup> day.

Afterward, food intake can be in a more liberal regimen. Some authors recommend taking liquids (liquid nutritional solutions, milk) 48 hours after ingestion if the patient can swallow his/her saliva. In patients with 2B and 3 degrees of damage, the so-called "esophageal rest" is recommended. That is, the patient must not take food per os. During the "rest," the patient is fed by nasogastric or nasoenteral tube, gastrostomy or jejunostomy, and parenterally by peripheral or central vein. This is explained by the fact that food particles enter the granulocytes of the esophageal wall and exacerbate the inflammation. Esophageal rest may last until the 10<sup>th</sup> day after corrosive ingestion, or some authors say until the 15<sup>th</sup> day, that is, until the first endoscopic control.<sup>5,16</sup>

In this study, the child came in late sequelae, and he ate a regular meal but vomited soon after eating. We suggested to ate a liquid meal with a small volume and frequent times. We evaluated the tolerance intake and gave an additional calorie by parenteral nutrition.

Gastric acid suppression with proton pump

inhibitor and H<sub>2</sub>-antagonists are often used in corrosive burn injury as oesophagitis and gastritis are common, and patients have been kept fasting.<sup>14</sup> This treatment has been employed in our patients in order to suppress gastric acid production and prevent stress ulcers in the stomach. The choice of definitive surgery for corrosive gastric outlet obstruction was determined by the extent of cicatrization of the stomach and the general condition of the patient. The main aim of surgery in corrosive pyloric stenosis is the relief of obstruction with reasonable gastric volume. For short segment stricture in the distal stomach, stricturoplasty, or pyloroplasty, either Heineke-Mikulicz type or Y-V flap can be done. In cases of severe stricture and loss of gastric volume, gastrojejunostomy was preferred. Roux-en-Y gastrojejunostomy was preferred to prevent bile reflux.<sup>17</sup> Timing of surgery is controversial, but early surgical intervention remains the treatment of choice.<sup>6</sup> In this patient, we performed the operation on day 15<sup>th</sup> after inward or day 35<sup>th</sup> after ingestion of corrosive agents.

#### 4. Conclusion

The incidence of corrosive ingestion is high and largely unreported in developing countries due to lack of parental supervision and careless storing of these chemicals at home. The most common presentation such as vomiting, feeding problem in oral intake, and rapid weight loss. The clinical diagnosis of prepyloric stricture is based on the history of the disease, physical examination, and supporting the investigation. Treatment of gastric outlet obstruction caused by corrosive ingestion should be treated surgically.

#### 5. References

1. Naik RR, Vadivelan M. Corrosive poisoning. *Indian Jour of clin pract.* 2012; 23:131-4.
2. Park KS. Evaluation and management of caustic injuries from ingestion of acid or alkaline substances. *Clin Endosc.* 2014; 47:301-7.
3. Kumar L, Saxena A, Singh M, Kohle Y. Accidental corrosive acid ingestion resulting in isolated pyloric stenosis: a rare phenomenon. *J surgery.* 2015; 11:371-3.
4. Gautam A, Gupta UN, Chandra S, Singh B. Corrosive poisoning: no calm after the storm. *JIACM.* 2013; 14:46-9.
5. Chibishev A, Simonovka N, Shikole. A Post-corrosive injuries of upper gastrointestinal tract. *Prilozi.* 2010; 31:297-316.
6. Shukla RM, Mukhopadhyay M, Tripathy BB, Mandal KC, Mukhopadhyay M. Pyloric and antral strictures following corrosive acid ingestion: a report of four cases. *J Indian Assoc Pediatr Surg.* 2010; 15:108-9
7. Temiz A, Oguzkurt P, Ezer SS, Ince E, Hicsonmez A. Predictability of outcome of caustic ingestion by esophagogastroduodenoscopy in children. *World J Gastroenterol.* 2012; 18:1098-103.
8. Demidoren K, Kocamaz H, Dogan Y. Gastrointestinal system lesions in children due to the ingestion of alkali and acid corrosive substance. *Turk J Med Sci.* 2015; 45:184-90.
9. Poocharoen W. Corrosive injury induced gastric outlet obstruction in children: a case report. *The THAI Journal of Surgery.* 2008; 29:54-8.
10. Nagi B, Kochhar R, Thapa BR. Radiological spectrum of late sequelae of corrosive injury to upper gastrointestinal tract A Pictorial review. *Acta radiologica.* 2009; 45:7-12.
11. Gun F, Abbasoglu L, Celik A. Acute gastric perforation after acid ingestion case report. *J Pediatr Gastroenterol Nutr.* 2002; 35:360-2.
12. Mirza B, Ijaz L, Husnain M, Sheikh A. Accidental ingestion of hydrochloric acid causing acute gastric perforation in a child. *Jour of surg Pakistan.* 2011; 16:45-6.
13. Mirji P, Joshi C, Mallapur A, GVishwanath, Emmi S. Management of corrosive Injuries of the upper gastrointestinal tract. *Journal of Clinical and Diagnostic Research.* 2011;

5:944-7.

14. Keh SM, Onyekwelu N, McManus K, McGuigan J. Corrosive injury to upper gastrointestinal tract: Still a major surgical dilemma. *World J Gastroenterol.* 2006; 12:5223-8.
15. Meena BL, Narayan KS, Goyal G, Sultania S, Nijhawan S. Corrosive injuries of the upper gastrointestinal tract. *J Dig Endosc* 2017; 8:165-9.
16. Chibisev A. Post-corrosive late complications in esophagus and stomach – role of the esophageal rest. *Med Arh.* 2010; 64:320-3.
17. Ray D, Chattopadhyay G. Surgical management of gastric outlet obstruction due to corrosive injury. *Indian J Surg.* 2015;77: 662-5.