

## Bioscientia Medicina: Journal of Biomedicine & Translational Research

Journal Homepage: [www.bioscmed.com](http://www.bioscmed.com)

### Neuraxial Anesthesia for Cesarean Section in Pregnant Women with Ruptured Arteriovenous Malformation

Ida Bagus Reza Nanda Iswara<sup>1\*</sup>, FX Adinda Putra Pradhana<sup>1</sup>

<sup>1</sup>Department of Anesthesiology and Intensive Therapy, Faculty of Medicine, Universitas Udayana/Prof. Dr. I.G.N.G. Ngoerah General Hospital, Denpasar, Indonesia

#### ARTICLE INFO

##### Keywords:

AVM  
Neuraxial  
Post-stroke  
Pregnancy

##### \*Corresponding author:

Ida Bagus Reza Nanda Iswara

##### E-mail address:

[idabagusreza@gmail.com](mailto:idabagusreza@gmail.com)

All authors have reviewed and approved the final version of the manuscript.

<https://doi.org/10.37275/bsm.v7i7.842>

#### ABSTRACT

**Background:** Maternal stroke as a result of ruptured arteriovenous malformation (AVM) in pregnancy is rare. However, AVM rupture can result in high morbidity during pregnancy and the puerperium. In its management, several special considerations are needed to ensure the welfare of the mother and fetus. This article will discuss anesthesia in pregnant patients after hemorrhagic stroke due to AVM rupture under neuraxial anesthesia. **Case presentation:** A 25-year-old patient with a second pregnancy with twins at 33 weeks came with complaints of water coming out of the birth canal 1.5 hours before admission to the hospital. The patient was diagnosed with G2P0010 33 Weeks 3 days Gemelli H/H head presentation, buttocks presentation, intracerebral hemorrhage (ICH) et cause suspected AVM rupture, premature rupture of membranes, and first-day febrile observation and planned to undergo cito cesarean section. **Conclusion:** Neuraxial anesthesia is one of the safe options for pregnant patients after a hemorrhagic stroke with controlled intracranial pressure.

#### 1. Introduction

Maternal stroke is a stroke that occurs after pregnancy, both ischemic and hemorrhagic strokes. This stroke results in high morbidity during pregnancy and the puerperium.<sup>1</sup> The risk of stroke increases up to three times in pregnant and postpartum women compared to women who are not pregnant. Until now, maternal stroke data in Indonesia is still not very available because of its rare occurrence.<sup>2</sup> The mortality rate in maternal stroke is quite significant, so in its management, some special considerations are needed. In terms of anesthesia, regional anesthesia provides more benefits because it requires less airway manipulation, more stable hemodynamic status, and a lower risk of

thromboembolism and aspiration compared to general anesthesia in pregnant patients with a history of stroke.<sup>3-5</sup> This study aimed to explore an in-depth case report from the side of anesthesia in post-hemorrhagic stroke pregnant patients with neuraxial anesthesia.

#### 2. Case Presentation

A 25-year-old patient with twins at 33 weeks pregnant came with complaints of water coming out of the birth canal 1.5 hours before entering the hospital. Previous patient with a history of stroke and et cause suspected arteriovenous malformation (AVM) ruptured in the differential diagnosis of cerebral sinus venous thrombosis (CSVT). The patient at that time

complained of dizziness, headache, and repeated vomiting. The patient was referred to the neurology department for a CT-Scan and found bleeding in the brain. The patient was hospitalized for 10 days conservatively and then sent home without any complaints. Currently, there are no complaints of weakness, seizures, visual disturbances, and slurred speech. A history of cough, fever, sore throat, and shortness of breath in the last 2 weeks was also denied. History of heart disease, hypertension, diabetes mellitus, asthma, and other systemic diseases was denied. The patient does not smoke and consume alcohol. This pregnancy is the second pregnancy with a Gemelli baby. The patient previously had a miscarriage in her first pregnancy. The patient is currently taking paracetamol 500 mg if necessary and folic acid once a day.

The results of the physical examination found the patient was compos mentis with vital signs of blood

pressure 120/80 mmHg, pulse 104 times per minute, respiratory rate 18 times per minute, oxygen saturation 99% room air, patient temperature 36.9°C, and NRS pain scale stationary as well as moving three times out of ten. The results of the fetal examination showed a fetal heart rate of 146 beats per minute. Other physical examination results were within normal limits. The results of supporting examinations found leukocytosis patients (WBC =  $13.59 \times 10^3/\mu\text{L}$  (4.1 - 11.0)). The results of hemostasis and SARS-Cov 2 were within normal limits. A previous CT scan of the head revealed intracerebral hemorrhage (volume of about 16 mL) with surrounding perifocal edema in the right parieto-occipital lobe and subdural hematoma in the inter-cerebral fissure and right frontotemporal region with a maximum thickness of 0.4 cm. Results of optic nerve sheath diameters (ONSD) in Figure 2 were found to be within normal limits.

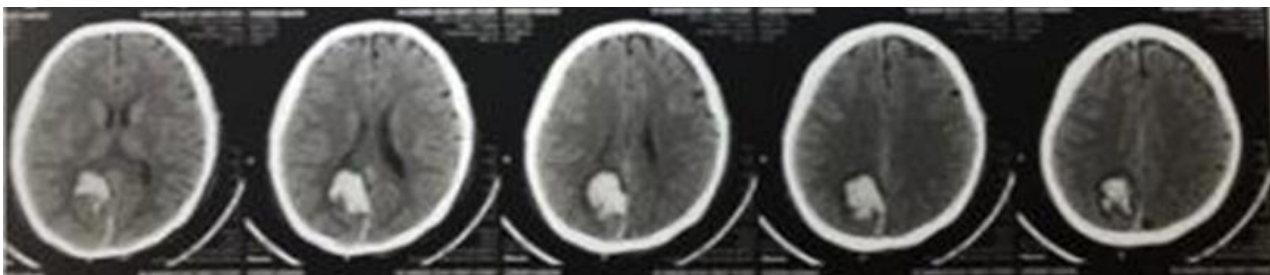


Figure 1. CT-Scan results at the previous examination.

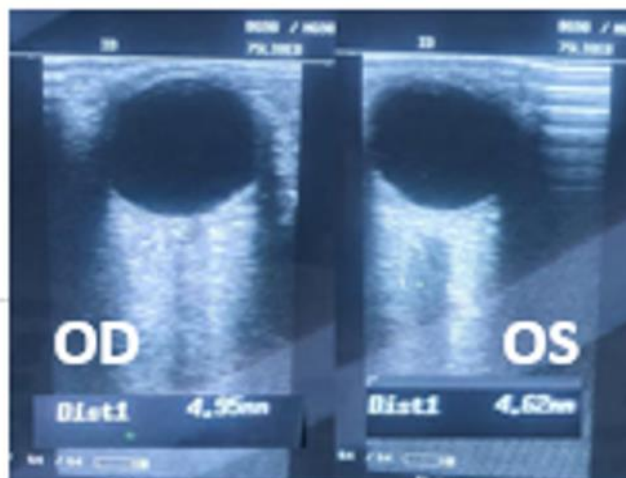


Figure 2. ONSD examination results.

A patient diagnosed with G2P0010 33 weeks 3 days Gemelli H/H head presentation, buttocks presentation, intracerebral hemorrhage (ICH) and et cause suspected AVM rupture with differential diagnosis of CSV, premature rupture of membranes, and the first day of febrile observation. Patient with ASA III physical status and planned to undergo cito cesarean section. The patient was given Ondansetron 8 mg premedication intravenously. The anesthetic technique used was a spinal block with 10 mg bupivacaine hyperbaric 0.5%. The block is performed using a 29 G needle at L2-L3. After that, proceed with the test pinprick, and a blockade as high as T4 was

obtained. Oxytocin 20 IU and tranexamic acid 1000 mg were also given to the patient. 10 minutes later, the first baby was born a boy, 2200 gr, APGAR score 8-9, and without congenital abnormalities, and the second baby was born a boy, 1530 gr, AS 6-7, and without congenital abnormalities. Hemodynamic fluctuations can be seen in Figure 3. After surgery, the patient was treated in the intensive care unit for 1 day and then transferred to the mother-child care room. The analgesic of choice postoperatively is morphine 20 mg in 24 hours and a combination with paracetamol 1000 mg every 8 hours intravenously.

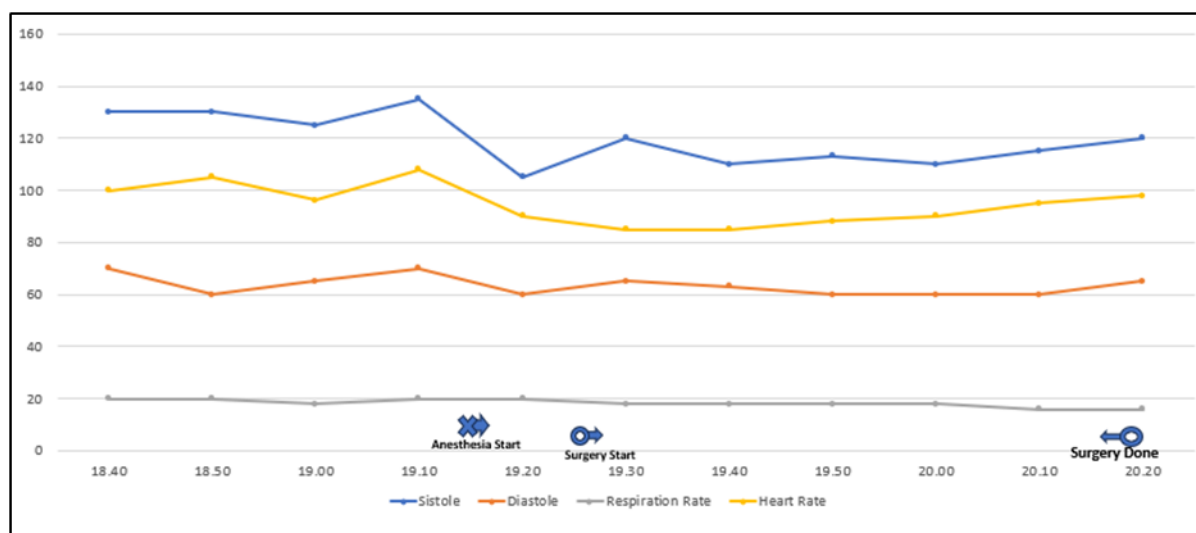


Figure 3. Hemodynamic fluctuations of patients during surgery.

### 3. Discussion

A maternal stroke occurs due to several physiological changes during pregnancy. Several factors, such as hemodynamic changes, venous stasis, hypercoagulable state, and immunomodulation, increase the risk of a mother having a stroke during pregnancy. Hemorrhagic stroke in pregnancy is usually associated with the rupture of an arteriovenous malformation (AVM) or other vascular lesion.<sup>6</sup> Intracranial hemorrhage from aneurysms and AVMs occurs in 0.01% to 0.05% of pregnancies with a maternal mortality rate of 5% to 12%.<sup>7</sup> A study in 2012 showed that the risk of AVM in pregnancy reached

10.8%, and the mortality rate reached 28%.<sup>8</sup> The choice of mode of delivery in patients with AVM is still controversial and is usually based on neurological indications. According to data, only a few pregnant women experience AVM rupture during labor. Most clinicians prefer to use cesarean section to prevent fluctuations of hemodynamics and intracranial pressure due to uterine contractions and the Valsalva maneuver during vaginal delivery. However, the reduced risk of bleeding with cesarean section is still not known with certainty.<sup>6</sup>

In such cases, the choice of anesthetic approach focuses on two things, namely, management of

intracranial pressure and hemodynamics. The choice of a neuraxial anesthetic technique for emergency cesarean section is based on the fact that this technique reduces the risk of aspiration, difficulty, or failure in intubation compared to general anesthesia. In addition, the use of neuraxial anesthetics decreases serum catecholamine levels and improves uteroplacental blood flow. The resulting sympathetic block demonstrates increased intervillous blood flow in patients with preeclampsia.<sup>9</sup> The neuraxial technique eliminates the risk of hemodynamic instability caused by endotracheal intubation and increased intracranial pressure due to positive pressure ventilation.<sup>10</sup> Recent studies also support that neonatal outcomes are worse with the use of general anesthesia at delivery.<sup>11</sup>

Although the choice of a neuraxial anesthetic technique has advantages in terms of maternal and fetal safety, several aspects also need to be considered in assessing whether this technique can be used. These aspects are maternal coagulation status, disorientation, and the impact of stroke on intracranial anatomy and physiology.<sup>1</sup> In this case, the mother's platelet level was still within normal limits (PLT= 267 x 10<sup>3</sup>/μL). The patient is also in a state of compos mentis. Then, the results of this patient's ONSD measurements were within normal limits, so it was concluded that the patient's intracranial pressure was within normal limits and did not require intervention to reduce it. ONSD itself is a non-invasive modality in estimating intracranial pressure using assistance ultrasound. ONSD examination results of more than 5.00-7.00 indicate intracranial pressure of more than 20 mmHg. ONSD specificity rate reached 92.3% with a sensitivity of 95,6%.<sup>12</sup> more regarding time, general anesthesia was superior in time to incision compared to spinal block (11.19 ± 10.74 vs 19.41 ± 7.77 p<0.05).<sup>13</sup> But when compared from the side of safety, neuraxial anesthesia is far superior to general anesthesia. Handling postoperative nausea and vomiting is also important. The choice of regional anesthetic technique also has an effect on this treatment. This is because regional anesthesia

techniques can prevent postoperative nausea and vomiting (PONV), which can increase intracranial pressure.<sup>10</sup>

#### 4. Conclusion

Neuraxial anesthesia is one of the safe options for pregnant patients after a hemorrhagic stroke with controlled intracranial pressure.

#### 5. References

1. Miller EC, Leffert L. Stroke in pregnancy: A focused update. *Anesth Analg.* 2020; 130(4): 1085-96.
2. Elgendy IY, Bukhari S, Barakat AF, Pepine CJ, Lindley KJ, Miller EC; American College of Cardiology Cardiovascular Disease in Women Committee. Maternal stroke: A call for action. *Circulation.* 2021; 143(7): 727-38.
3. Christiansen MN, Andersson C, Gislason GH, Torp-Pedersen C, Sanders RD, Jensen PF, et al. Risks of cardiovascular adverse events and death in patients with previous stroke undergoing emergency noncardiac, nonintracranial surgery. *Anesthesiology.* 2017; 127(1): 9-19.
4. Karnik HS, Jain RA. Anesthesia for patients with prior stroke. *Journal of Neuroanaesthesiology and Critical Care.* 2018; 05(03): 150-7.
5. Kodai I, Tadahiko I, Kazuhiro S. Combined spinal and epidural anesthesia for cesarean section in a parturient with cerebral arteriovenous malformation. *Circulation Control.* 2012; 33(1): 32-5.
6. Miller EC. Maternal stroke associated with pregnancy. *Continuum (Minneapolis, Minn).* 2022; 28(1): 93-121.
7. Yih PS, Cheong KF. Anaesthesia for caesarean section in a patient with an intracranial arteriovenous malformation. *Anaesth Intensive Care.* 1999; 27(1): 66-8.

8. Lv X, Liu P, Li Y. The clinical characteristics and treatment of cerebral AVM in pregnancy. *Neuroradiol J.* 2015; 28(3): 234-7.
9. Ankichetty SP, Chin KJ, Chan VW, Sahajanandan R, Tan H, Grewal A, et al. Regional anesthesia in patients with pregnancy induced hypertension. *J Anaesthesiol Clin Pharmacol.* 2013; 29(4): 435-44.
10. Sim J-H, Lee J-H, Lee C-H, Ryu S-A, Choi S-S. Anesthetic management during cesarean delivery in a pregnant woman with ruptured cerebral arteriovenous malformation -A case report-. *Anesthesia and Pain Medicine.* 2017; 12: 220-3.
11. Ring L, Landau R, Delgado C. The current role of general anesthesia for cesarean delivery. *Curr Anesthesiol Rep.* 2021; 11(1): 18-27.
12. Richards E, Munakomi S, Mathew D. Optic nerve sheath ultrasound. In: *StatPearls.* Treasure Island (FL): StatPearls Publishing. 2023.
13. Wiskott K, Jebrin R, Ioscovich D, Grisaru-Granovsky S, Tevet A, Shatalin D, et al. General versus regional anesthesia for emergency cesarean delivery in a high-volume high-resource referral center: A retrospective cohort study. *Rom J Anaesth Intensive Care.* 2020; 27(2): 6-10.