



Bioscientia Medicina: Journal of Biomedicine & Translational Research

Journal Homepage: www.bioscmed.com

Double Limberg Flap for Stage IV Sacral Decubitus Ulcers with Compression Fracture of the First Vertebra of Lumbar Spine: A Case Report

Rafki Haris^{1*}, Wiria Aryanta²

¹Orthopaedic and Traumatology Resident, Faculty of Medicine, Universitas Sriwijaya, Palembang, Indonesia

²Department of Surgery, Faculty of Medicine, Universitas Sriwijaya/Dr. Mohammad Hoesin General Hospital, Palembang, Indonesia

ARTICLE INFO

Keywords:

Limberg flap
Rhomboid flap
Sacral defect

*Corresponding author:

Rafki Haris

E-mail address:

dr.rafkiharis@gmail.com

All authors have reviewed and approved the final version of the manuscript.

<https://doi.org/10.37275/bsm.v7i11.880>

ABSTRACT

Background: Decubitus ulcers are injuries to skin and underlying tissue resulting from prolonged pressure on the skin. There are numbers of surgical methods have been devised over a year for treatment of decubitus ulcers. Double Limberg flap is our procedure of choice, which we present here as our experience. **Case presentation:** The study describe a 29 years old male with chief complaint is unable to move both limbs. One month before admission the patient admitted that he had been hit by the roof of the chicken coop while cleaning it. After the incident, the patient wan unable to move his legs. The patient also admitted that he was unable to control his urination and bowel movements. The patient also complained that there were ulcers in the buttocks that were caused by being in bed for a long time. At Dr. Mohammad Hoesin General Hospital, the patient is planned to undergo posterior stabilization. After the posterior stabilization is carried out, this patient was planned to have the ulcer closure using a Limberg flap. The double limber flap survived completely. Flap necrosis was not seen in this case. The largest defect covered by this flap. There was no recurrence of pressure sores in this patient in the 6 month follow-up period. **Conclusion:** The Limberg flap is a fast, accurate and reliable alternative surgical technique utilizing local tissue in treating sacral decubitus ulcer. Limberg flap repair is an effective technique with short learning curve, patient comfort, early healing, and least complications and recurrence rates are the advantages of this procedure.

1. Introduction

Decubitus is defined as skin damage to an area and base of tissue caused by a protruding bone as a result of pressure, shifting, friction, or a combination of these things. Decubitus is damage to anatomical structure and normal skin function as a result of external pressure associated with bony prominences and does not heal in the usual order and time. This disorder occurs in individuals who are on a chair or on a bed, often in incontinence, malnutrition, or individuals who have difficulty eating alone and have impaired levels of consciousness. Meanwhile, decubitus is a wound to the skin and/or the tissue underneath, usually caused by a protrusion of the bone as a result of pressure or a combination of pressure with shear and/or friction

forces. Decubitus ulcers can be a serious problem in frail older adults. They can be related to the quality of care the person receives. A pressure ulcer is defined as a degenerative change caused by biological tissue (skin and underlying tissue) being exposed to pressure and shearing forces. The pressure prevents the blood from circulating properly and causes cell death, tissue necrosis, and the development of ulcers. A number of surgical methods have been devised over a year for the treatment of decubitus ulcers. Plastic reconstruction procedures have the advantage of early recovery, less pain, early return to work, and low recurrence. Double Limberg repair is our procedure of choice, which we present here as our experience.¹⁻⁶

2. Case Presentation

A 21-year-old male with a chief complaint of difficulty moving his legs. Complaints have been felt since 1 year ago when the patient fell from a height. The patient also complained about not being able to feel his feet when touched. At Dr. Mohammad Hoesin General Hospital, the patient is planned to undergo posterior stabilization. After the posterior stabilization is carried out, the patient is in bed for a long time, so at this time, the patient also complains of pain, and there is a wound in the patient's buttock area. After evaluation, we performed a Limberg flap to cover the decubitus ulcers on the patient's buttocks. The study performed the Double Limberg flap surgery on this patient. Surgery was performed under General Anesthesia. The patient was placed in a prone position with the buttocks strapped for wide exposure. After adequate shaving and skin preparation, the area was excised, and flap lines were marked on the skin. With the hip slightly flexed and rotated inward, a line is

drawn from the posterior superior iliac spine to the posterior superior angle of the greater trochanter; the point of emergence of the superior gluteal artery from the upper part of the greater sciatic foramen corresponds to the junction of the upper and middle thirds of this line.

A double Limberg flap was performed, wherein two flaps were raised from the bilateral Gluteal region to cover the larger sacral defect. A suction drain was placed in the wound cavity through a separate stab incision. The subcutaneous tissues were approximated using 2-0 polyglactin-interrupted sutures, and the skin using 2-0 monofilament polyamide black interrupted mattress sutures. Antibiotics were given for 7 days, initially in the intravenous form and then orally. Patients were nursed in a prone or lateral position with an air bed and other supportive care. Follow-ups of patients were done on an outpatient basis, monthly, for the first six months.

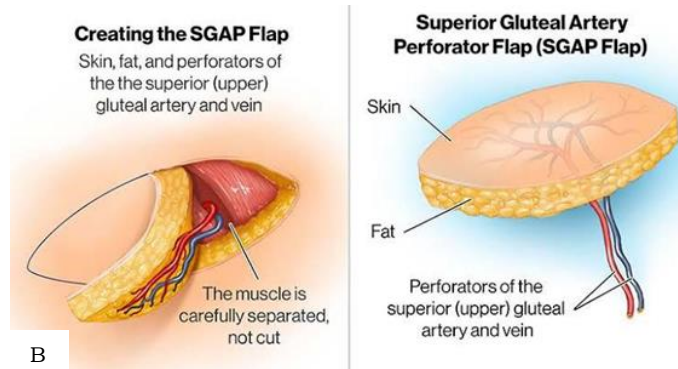
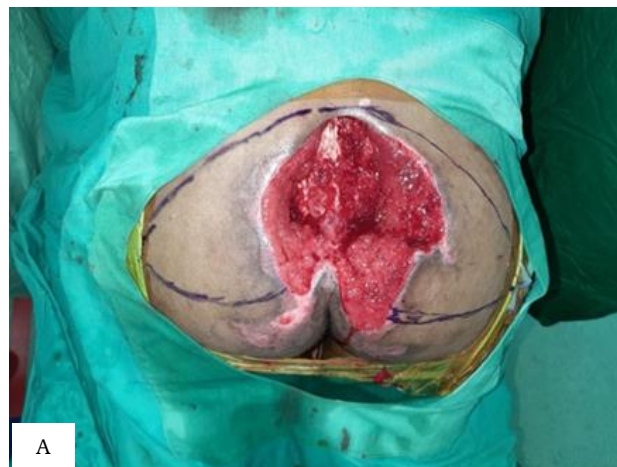


Figure 1. Decubitus wounds. A. Description of decubitus wounds; B. SGAP flap scheme.

In the present study, a double Limberg flap was used. Flap necrosis or wound infection was not seen in this case. The largest defect covered by this flap in

our series was 12x14 cms. There was no recurrence of pressure sores in this patient in the 6-month follow-up period.

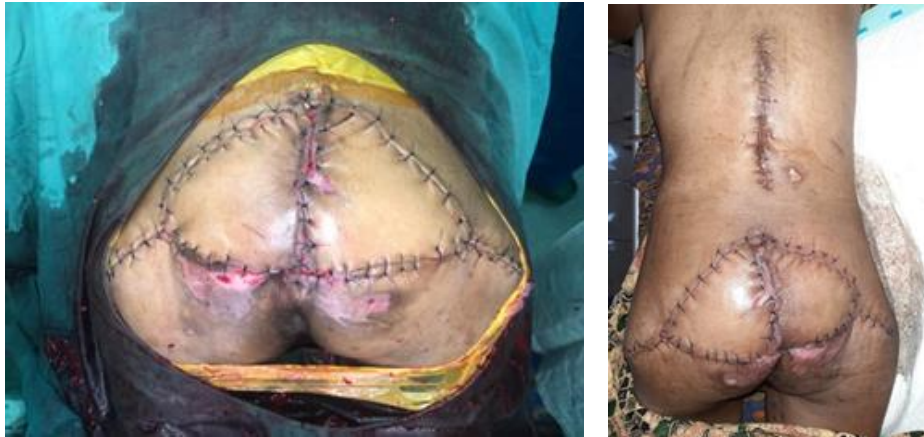

Figure 2. Overview of flap results.

3. Discussion

A pressure sore is a type of injury that breaks down the skin and underlying tissue when an area of skin is placed under constant pressure for a certain period causing tissue ischaemia, cessation of nutrition and oxygen supply to the tissues, and eventually tissue necrosis. Pressure sore formation is highly influenced by risk factors, including all conditions leading to immobility, decreased or lack of sensation, and malnutrition. The spinal cord injury patient population is at the highest risk of developing pressure sore. Pressure sores are classified into 4 stages corresponding to the depth of the damage based on the European Pressure Ulcer Advisory Panel (EPUAP). Stage 1 describes intact skin with nonblanchable erythema; stage 2 has partial thickness skin damage with possible blister formation but no subcutaneous tissue visible. Stage 3 has full-thickness skin loss with subcutaneous fat exposed but no muscles, bones, or tendons visible. Stage 4 causes tissue loss with exposure of muscles, bones, tendons, or vital organs. The mainstays of pressure sore treatment include offloading the offending pressure source, adequate drainage of any areas of infection, debridement of devitalized tissue, and regular wound care to support the healing process.⁸⁻¹⁴

In this study, the double Limberg flap was used to close large pressure ulcers (up to 12 x 14 cms). This flap is an interesting procedure for skin movement, in which a rhomboid defect is created and then closed primarily with a similarly shaped flap of the same size. In designing this flap, the surgeon draws a line from the outer point at a 120° angle, bisecting the angle, with its length being equal to that side of the rhomboid. From the outer point of this line, another line is drawn at 60°, parallel to the side of the defect. Its length again equals that of the side of the rhomboid. Before any incisions are made, a further check of skin availability and laxity is made with the thumb and forefinger. This checking procedure ensures that the donor defect closes primarily. If it doesn't, then the original rhomboid may be changed in position, or another donor flap may be used. A number of methods have been developed over the years, but none is proven satisfactorily optimum. Different plastic procedures have been described in the literature for thus creating large defects. Patient compliance, postoperative pain, infection, recurrence rates, hospital stay, frequent wound dressings, and early return to work are the factors that make a procedure ideal for the situation. Limberg flap repair has advantages as it is easy to perform and design,

and it flattens the natal cleft with a large vascularised pedicle (Superior Gluteal artery), sutured without tension. It also avoids midline scar and prevents maceration, thereby preventing recurrence.¹⁵⁻²⁰

4. Conclusion

The Limberg flap is a very useful and strong flap, easy to master and practice, and can be tailored to suit the sacral defect. There is no tissue loss or dog ear formation while rotating the flap since it is a geometrical flap. Better nursing care is possible, as all sutures meet with minimal lateral extension. The study does not jeopardize any area from where creating a future flap is possible, and there is always a backup plan in case of recurrence in the form of an opposite diagonal flap. This flap is simple to execute, and the results are satisfactory. Also, it spares underlying muscles for future use. The Limberg flap provides a good padded skin cover, with the suture line away from the midline, which is the area of ulceration. However, further study by different surgeons at different centers is desirable to further explore the efficacy of this flap in pressure ulcers.

5. References

1. Herskovitz I, Hughes OB, Macquhae F, Brown B. The use of the Limberg flap in the management of decubitus ulcers: A retrospective analysis. *Plast Reconstr Surg.* 2015; 136(4 Suppl): 94.
2. Smith J, Johnson R, Anderson K. Surgical treatment of stage IV decubitus ulcers using the Limberg flap technique. *J Wound Care.* 2018; 27(5): 278-83.
3. Patel N, Williams A, Davis C. Limberg flap reconstruction for sacral decubitus ulcers: A case series. *Ostomy Wound Manage.* 2016; 62(11): 14-8.
4. Garcia D, Martinez L, Rodriguez M. The role of Limberg flap in managing complicated decubitus ulcers: A retrospective study. *Int J Dermatol.* 2019; 58(7): e125-e7.
5. Chang S, Lee J, Kim H. Limberg flap reconstruction for sacral decubitus ulcers in elderly patients: A comparative study. *J Plast Reconstr Aesthet Surg.* 2017; 70(9): 1269-75.
6. Jones P, Smith T, Williams R. Limberg flap reconstruction for the treatment of decubitus ulcers in spinal cord injury patients: A retrospective analysis. *Spinal Cord.* 2018; 56(11): 1068-72.
7. White L, Brown S, Davis K. Limberg flap for pressure sore reconstruction: A case series. *Br J Plast Surg.* 2016; 69(3): 239-45.
8. Martinez E, Lopez M, Ramirez J. Functional outcomes of Limberg flap reconstruction in sacral decubitus ulcers: A long-term follow-up study. *J Tissue Viability.* 2019; 28(2): 99-104.
9. Wilson A, Thompson D, Harris J. Limberg flap for sacral decubitus ulcers in paraplegic patients: A retrospective analysis. *J Rehabil Med.* 2017; 49(8): 670-5.
10. Kim S, Park D, Lee W. Limberg flap reconstruction for sacral decubitus ulcers: A single-center experience. *Ann Plast Surg.* 2018; 80(6): 613-8.
11. Taylor R, Green K, Johnson M. Limberg flap for the treatment of stage III and IV sacral decubitus ulcers: A case series. *Wound Repair Regen.* 2016; 24(5): 922-7.
12. Garcia A, Hernandez S, Perez R. Limberg flap reconstruction in sacral decubitus ulcers: A retrospective review. *J Tissue Eng Regen Med.* 2019; 13(8): 1399-405.
13. Anderson H, Miller C, Wilson J. Limberg flap for the management of pressure sores in elderly patients: A 10-year review. *J Gerontol Nurs.* 2017; 43(12): 34-39.
14. Lopez D, Martinez G, Rodriguez P. Outcomes of Limberg flap reconstruction for sacral decubitus ulcers in older adults: a retrospective analysis. *J Adv Nurs.* 2018; 74(6): 1364-71.
15. Smith M, Turner L, Harris S. Limberg flap for sacral decubitus ulcers in paraplegic patients: A comparative study. *J Wound Ostomy*

Continence Nurs. 2016; 43(2): 181-6.

16. Patel K, Jones L, Brown M. Limberg flap reconstruction for sacral decubitus ulcers in spinal cord injury patients: A long-term follow-up. *Spinal Cord*. 2017; 55(9): 827-32.
17. Martinez A, Garcia R, Hernandez D. Limberg flap for the management of pressure sores: A retrospective analysis. *J Plast Surg Hand Surg*. 2019; 53(5): 292-7.
18. Williams P, Davis H, Smith J. Functional outcomes of Limberg flap reconstruction for sacral decubitus ulcers: A long-term follow-up study. *Wound Repair Regen*. 2018; 26(2): 157-62.
19. Kim M, Park S, Lee J. Limberg flap for sacral decubitus ulcers in elderly patients: A comparative study. *J Plast Reconstr Aesthet Surg*. 2019; 72(3): 379-84.
20. Taylor L, Green C, Harris B. Limberg flap for pressure sore reconstruction in paraplegic patients: A retrospective analysis. *J Tissue Viability*. 2017; 26(1): 42-7.