

Bioscientia Medicina: Journal of Biomedicine & Translational Research

Journal Homepage: www.bioscmed.com

A Suspicious Cup Disc with High Intraocular Pressure (IOP) and Normal Perimetry: A Rare Self Case Report

Mario Abdiwijoyo^{1*}, Nanda Lessi Hafni Eka Putri²

¹Faculty of Medicine, Universitas Tarumanagara, Jakarta, Indonesia

²Department of Ophthalmology, Ciawi Regional General Hospital, Bogor, Indonesia

ARTICLE INFO

Keywords:

Cup to disc ratio (CDR)
Corneal thickness
Intraocular pressure (IOP)
Juvenile open-angle glaucoma (JOAG)
Ocular hypertension

*Corresponding author:

Mario Abdiwijoyo

E-mail address:

marioabdi216@gmail.com

All authors have reviewed and approved the final version of the manuscript.

<https://doi.org/10.37275/bsm.v8i5.982>

ABSTRACT

Background: Intraocular pressure (IOP) assessment involves evaluating the force exerted by aqueous humor on the internal surface of the anterior eye. Elevated IOP poses a substantial risk for glaucomatous optic neuropathy and is a key modifiable clinical risk factor. This study aims to explore cases of ocular hypertension coupled with optic nerve cupping, suspected to be glaucoma, providing comprehensive details of examination results, diagnosis, and subsequent management. **Case presentation:** A 23-year-old Asian male underwent an ocular examination, revealing average IOP levels measured using non-contact tonometry. Despite no complaints, consecutive measurements noted 28 mmHg for the right eye and 26 mmHg for the left eye. Initial assessments by a glaucoma specialist indicated open-angle anterior chambers. Optical coherence tomography revealed cup disc ratios of 0.7 to 0.8 for both eyes. Medication (Timol) was prescribed, adjusting with oral citicoline and brinzolamide. The diagnosis evolved to juvenile open-angle glaucoma (JOAG). Visual field testing showed normal results. Discontinuation of treatment led to reclassifying the diagnosis as ocular hypertension and scheduling follow-up OCT examinations for five years. **Conclusion:** The patient exhibited corneal thickness $\geq 610 \mu\text{m}$, CDR ≥ 0.7 , IOP $> 25 \text{ mmHg}$, and maintained good visual field conditions. Additional research is essential to understand the correlation between corneal thickness and other eye conditions. Recognizing potential overdiagnosis due to high IOP and large CDR emphasizes the need for meticulous clinical assessment and advanced diagnostic examinations to distinguish physiological and pathological conditions.

1. Introduction

Intraocular pressure (IOP) measurement involves assessing the force applied by the aqueous humor on the internal surface of the anterior eye. Normal pressure typically ranges from 11 to 21 mmHg, with diurnal IOP levels generally higher in the morning. Elevated intraocular pressure poses a significant risk for glaucomatous optic neuropathy and stands as the sole clinically modifiable risk factor. In clinical terms, heightened IOP surpassing 21 mmHg or $\geq 24 \text{ mmHg}$ in eyes lacking optic nerve damage, visual field defects, and retinal nerve fiber layer (RNFL) thinning is termed ocular hypertension (OHT). The global prevalence of

ocular hypertension varies from 0.32% to 12.2%.^{1,2}

Various methods exist for measuring IOP, including transpalpebral, tonometry, and manometry. Applanation, indentation, rebound, and contour matching constitute the four tonometry principles. Applanation tonometry is further categorized into non-contact and contact methods. Goldmann applanation tonometry (GAT) is acknowledged as the International Gold Standard for IOP measurement in clinical settings, avoiding significant corneal damage.^{3,4}

The enlargement of the cup-to-disc ratio, referred to as "cupping," signals the presence of glaucoma, though it is not pathognomonic. The mechanism

behind cup-to-disc enlargement remains incompletely understood. Histopathological studies propose that optic nerve cupping in glaucoma may arise from the loss of ganglion cell axons and thinning of the lamina cribrosa, causing a posterior shift. Cupping can be physiological or linked to glaucoma, known as compressive optic neuropathy, hereditary optic neuropathy, and anterior arteritic ischemic optic neuropathy. Clinically discerning optic nerve cupping due to glaucoma or non-glaucoma remains challenging, primarily due to the subjective nature of optic nerve pallor.⁵

This study will highlight cases of ocular hypertension accompanied by optic nerve cupping suspected to be glaucoma. The objective is to provide a detailed description of the examination results, diagnosis, and subsequent management.

2. Case Presentation

A 23-year-old Asian male, presenting with no complaints, underwent an ocular examination, revealing an average intraocular pressure for both eyes measured using non-contact tonometry. After three

consecutive measurements, the recorded values were 28 mmHg for the right eye and 26 mmHg for the left eye. The patient reported no history of pain or visual impairment, such as blurriness or shadows, and achieved a visual acuity of 6/6 in both eyes. There was no prior use of medications, no history of ocular surgery, and no ocular trauma. The patient had no medical history of hypertension, diabetes mellitus, or other comorbidities and reported neither smoking nor alcohol consumption.

In the initial assessment, the patient was examined by a glaucoma specialist, and gonioscopy revealed an open angle of the anterior chamber. optical coherence tomography (OCT) showed cup disc ratios ranging from 0.7 to 0.8 for both eyes, with other parameters within normal limits (Figure 1). Subsequently, the patient was prescribed topical eye drops (Timol) and scheduled for reevaluation after one month. Upon reexamination at the one-month mark, intraocular pressure remained in the range of 21-24 mmHg for both eyes. The doctor conducted keratometry, revealing a corneal thickness of 612 μm for the right eye and 610 μm for the left eye (Figure 2).

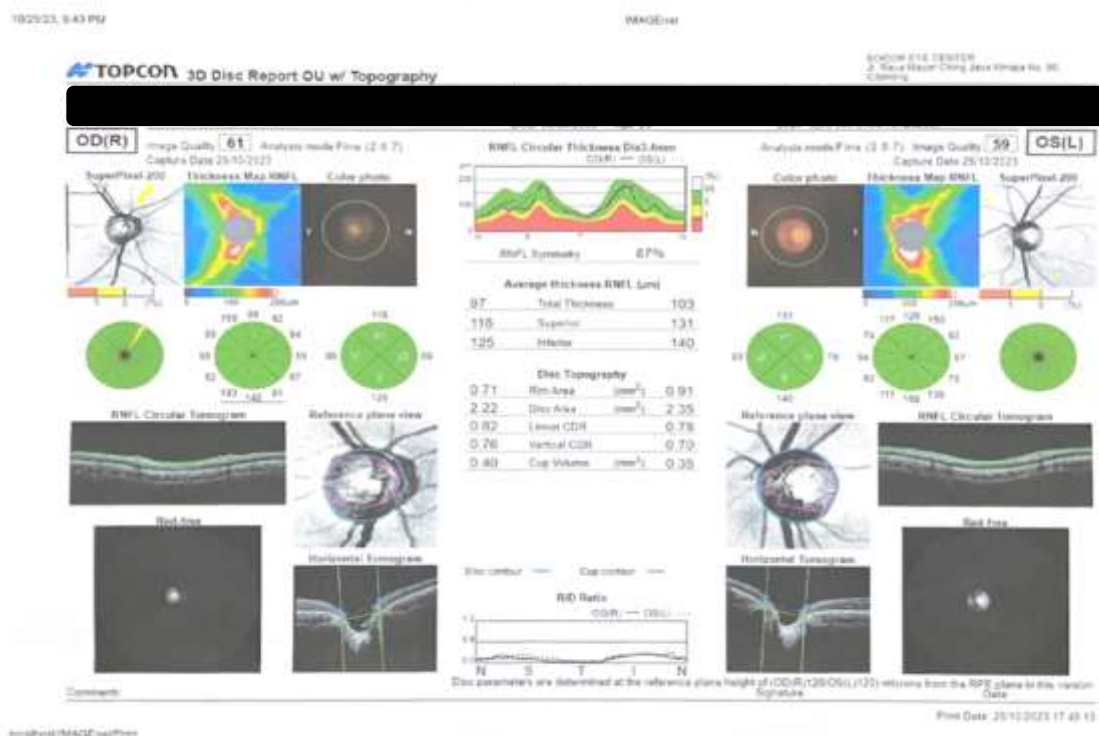


Figure 1. Results of the optical coherence tomography (OCT) examination.

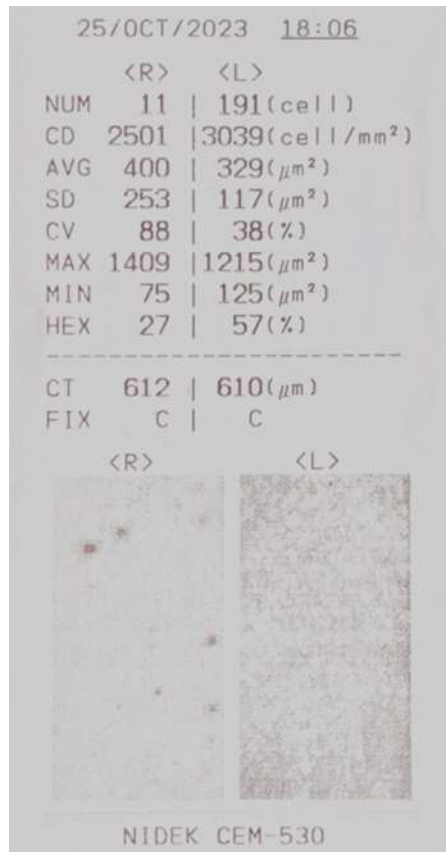


Figure 2. Keratometry result.

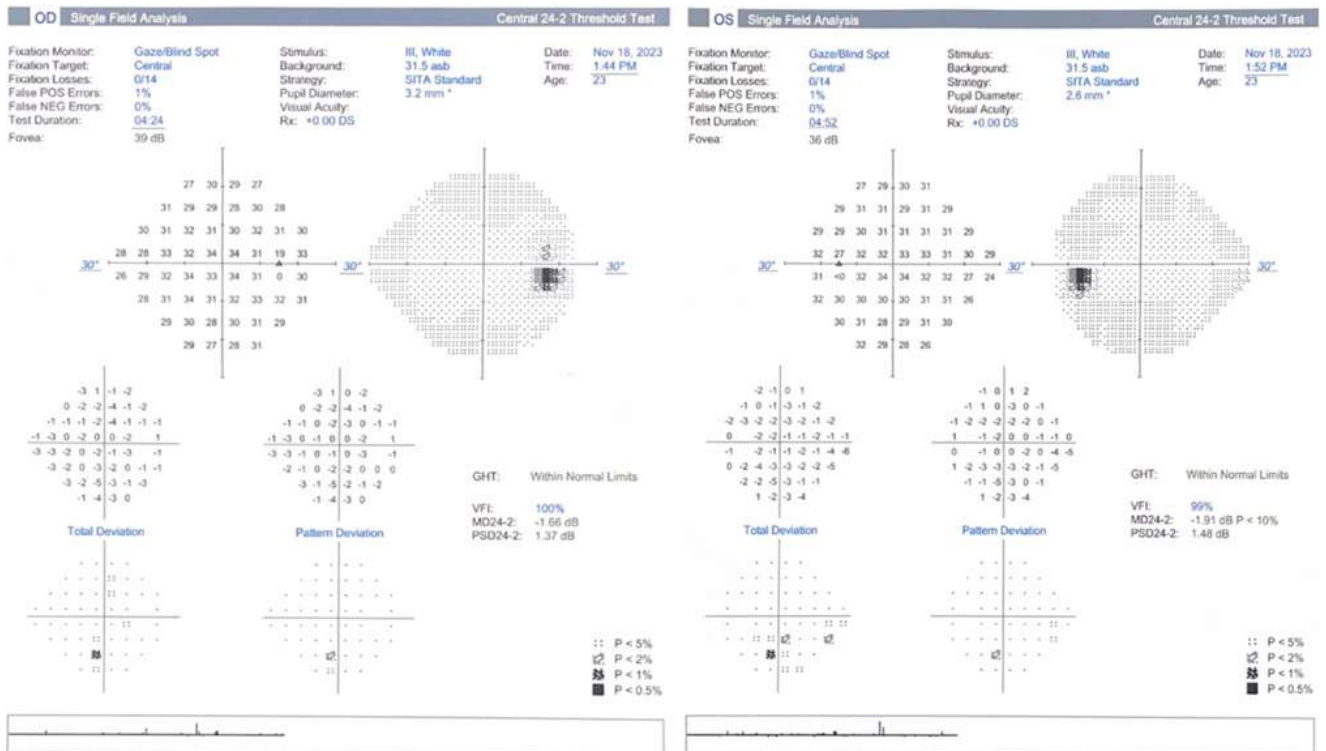


Figure 3. Visual field examination results for the right and left eyes.

The patient's medication was adjusted with the addition of oral Citicoline and Brinzolamide. At this point, the diagnosis was revised to juvenile open-angle glaucoma (JOAG), prompting the doctor to recommend visual field testing (perimetry). The results of the visual field examination for both eyes were within normal limits (Figure 3). Applanation tonometry using a Goldmann tonometer indicated intraocular pressures of 19 mmHg for the right eye and 21 mmHg for the left eye while on Timol and Brinzolamide. Eventually, the doctor advised discontinuation of treatment, reclassifying the diagnosis as ocular hypertension. Follow-up OCT examinations were scheduled one-month post-treatment cessation and subsequently every six months for the next five years.

3. Discussion

Juvenile open-angle glaucoma (JOAG) represents a specific category within primary open-angle glaucoma that manifests before the age of 40. JOAG is distinguished by an increase in intraocular pressure (IOP), predominantly affecting males. This condition may arise from a combination of genetic and non-genetic factors. JOAG is a rare occurrence, with an estimated prevalence of 1 in 50,000 in the United States, 0.7% in Saudi Arabia, 1.9% in India, and 0.7% in the Caucasian population. Inheritance patterns often follow an autosomal dominant trait, frequently involving the myocilin protein, previously identified as trabecular meshwork inducible-glucocorticoid response protein (TIGR). Myocilin protein has been detected in various ocular structures, including the trabecular meshwork, trabecular beam, and juxtacanalicular connective tissue. Over 70 mutations in the myocilin gene (MYOC) have been identified, contributing to increased resistance in the outflow of aqueous humor. However, it is crucial to emphasize that the presence of MYOC mutations does not necessarily indicate the development of JOAG.^{6,7}

Managing juvenile glaucoma can be challenging, but medical therapy has proven effective in controlling the disease for patients with moderately elevated intraocular pressure (IOP) and milder severity. Alpha

agonists are generally avoided in children under the age of 10. Latanoprost demonstrates a favorable reduction in ocular pressure for JOAG compared to other pediatric glaucomas. Combining carbonic anhydrase inhibitors like brinzolamide or dorzolamide with timolol has been shown to improve retinal blood flow in JOAG patients.⁶

The optic disc, a minute blind spot on the retina without photoreceptors, comprises three distinct regions: a central white depression called the cup, a peripheral ring known as the neuroretinal rim, and the optic nerve. Glaucoma arises from elevated intraocular fluid pressure due to abnormal production or drainage of aqueous humor circulating between the cornea and lens inside the eye.⁸

Traditionally, intraocular pressure is measured using applanation tonometry, estimating pressure within the anterior eye based on corneal resistance to flattening. Normal pressure falls between 11 and 21 mmHg, with higher readings typically in the morning. While Goldmann applanation tonometry (GAT) remains the primary method, rebound tonometry using a portable tonometer has emerged as a practical approach for acute conditions. This method, based on the capillary force of the tear meniscus opposing corneal stiffness during a 3.06 mm diameter flattening, necessitates central corneal thickness measurement for accurate intraocular pressure (IOP) readings.¹

In a study by Sarfraz et al., there is no statistically significant correlation between corneal thickness and cup-to-disc ratio (CDR). The journal also notes that many researchers report no significant correlation between corneal thickness and CDR. In this study, patients exhibited above-average corneal thickness, measuring 612 μm in the right eye and 610 μm in the left eye, with both eyes having a linear and vertical CDR of ≥ 0.7 . Shagufta Parveen et al. found that 7 out of 115 (6.1%) studied patients had a CDR >0.6 μm in a healthy condition, not leading to glaucoma.^{9,10}

While the study provides valuable insights, further research is required to explore connections between corneal thickness, cup-to-disc ratio (CDR), intraocular

pressure (IOP), and other corneal thickness-related correlations.

4. Conclusion

This study indicates that the patient has corneal thickness $\geq 610 \mu\text{m}$ in both eyes, CDR ≥ 0.7 in both eyes, IOP $> 25 \text{ mmHg}$, and maintains good visual field conditions. However, further research is necessary to determine the correlation between corneal thickness and other eye conditions. Additionally, it is important to acknowledge that high IOP and large CDR can lead to overdiagnosis by physicians and result in misdiagnosis, potentially overlooking glaucoma in individuals with small cups and discs. Therefore, meticulous clinical assessment and advanced diagnostic examinations are imperative to differentiate between physiological and pathological conditions.

5. References

1. Machiele R, Motlagh M, Patel BC. Intraocular pressure. *Drug Discovery and Evaluation: Pharmacological Assay*, Fourth Edition. 2022.
2. Biswas S, Biswas S. Progression from ocular hypertension into glaucoma. *Ocular Hypertension - The Knowns and Unknowns*. 2021.
3. Da Silva F, Lira M. Intraocular pressure measurement: a review. *Surv Ophthalmol*. 2022; 67(5): 1319–31.
4. Messenio D, Ferroni M, Boschetti F, Goldmann Tonometry F, Biomechanics Appl Sci C. Goldmann tonometry and corneal biomechanics. *Applied Sciences*. 2021; 11(9): 4025.
5. Waisberg E, Micieli JA. Neuro-Ophthalmological Optic Nerve Cupping: An Overview. *Eye Brain*. 2021; 13: 255.
6. Selvan H, Gupta S, Wiggs JL, Gupta V. Juvenile-onset open-angle glaucoma – A clinical and genetic update. *Surv Ophthalmol*. 2022; 67(4): 1099.
7. Chak G, Mosaed S, Minckler D. Diagnosing and managing juvenile open-angle glaucoma. *EyeNet Magazine, Ophthalmic Pearls – Glaucoma, American Academy of Ophthalmology*. 2014.
8. Kumar JRH, Seelamantula CS, Kamath YS, Jampala R. Rim-to-disc ratio outperforms cup-to-disc ratio for glaucoma prescreening. *Scientific Reports*. 2019; 9(1): 1–9.
9. Sarfraz MH, Mehboob MA, Intisar-Ul-Haq R. Correlation between central corneal thickness and visual field defects, cup to disc ratio and retinal nerve fiber layer thickness in primary open-angle glaucoma patients. *Pak J Med Sci* 2017; 33(1): 132.
10. Parveen S, Muzaffar W, Saeed MK, Babar ZU, Tanveer H. Frequency of high cup to disc ratio amongst healthy young population of Central Punjab Province of Pakistan. *Pakistan Armed Forces Medical Journal*. 2023; 73(Suppl-2): S347-50.